This is a digital copy of a book that was preserved for generations on library shelves before it was carefully scanned by Google as part of a project to make the world's books discoverable online.

It has survived long enough for the copyright to expire and the book to enter the public domain. A public domain book is one that was never subject to copyright or whose legal copyright term has expired. Whether a book is in the public domain may vary country to country. Public domain books are our gateways to the past, representing a wealth of history, culture and knowledge that's often difficult to discover.

Marks, notations and other marginalia present in the original volume will appear in this file - a reminder of this book's long journey from the publisher to a library and finally to you.

Usage guidelines

Google is proud to partner with libraries to digitize public domain materials and make them widely accessible. Public domain books belong to the public and we are merely their custodians. Nevertheless, this work is expensive, so in order to keep providing this resource, we have taken steps to prevent abuse by commercial parties, including placing technical restrictions on automated querying.

We also ask that you:

+ *Make non-commercial use of the files* We designed Google Book Search for use by individuals, and we request that you use these files for personal, non-commercial purposes.
+ *Refrain from automated querying* Do not send automated queries of any sort to Google's system: If you are conducting research on machine translation, optical character recognition or other areas where access to a large amount of text is helpful, please contact us. We encourage the use of public domain materials for these purposes and may be able to help.
+ *Maintain attribution* The Google "watermark" you see on each file is essential for informing people about this project and helping them find additional materials through Google Book Search. Please do not remove it.
+ *Keep it legal* Whatever your use, remember that you are responsible for ensuring that what you are doing is legal. Do not assume that just because we believe a book is in the public domain for users in the United States, that the work is also in the public domain for users in other countries. Whether a book is still in copyright varies from country to country, and we can't offer guidance on whether any specific use of any specific book is allowed. Please do not assume that a book's appearance in Google Book Search means it can be used in any manner anywhere in the world. Copyright infringement liability can be quite severe.

About Google Book Search

Google's mission is to organize the world's information and to make it universally accessible and useful. Google Book Search helps readers discover the world's books while helping authors and publishers reach new audiences. You can search through the full text of this book on the web at `http://books.google.com/`

B 3 9015 00212 241 7
University of Michigan - BUHR

Digitized by Google



Digitized by Google

Med. Period.
610.5
P3
S7
L8t

Digitized by Google

Digitized by Google

TRANSACTIONS

L1265-4

OF THE

PATHOLOGICAL SOCIETY OF LONDON.

VOLUME THE FORTY-SECOND.

COMPRISING THE REPORT OF THE PROCEEDINGS FOR THE SESSION 1890-91.

LONDON:
SMITH, ELDER & CO., 15, WATERLOO PLACE.
1891.

Digitized by Google

THE present publication, being the Forty-second Volume of Transactions, constitutes the Forty-fifth published Annual Report of the Pathological Society's Proceedings.

The COUNCIL think it right to repeat that the exhibitors are alone responsible for the descriptions given of the Specimens exhibited by them, the only change made in the Reports furnished by the authors being such verbal alterations as were absolutely necessary.

20, HANOVER SQUARE, W.;
October, 1891.

Digitized by Google

TABLE OF CONTENTS

OF VOLUME XLII.

	PAGE
List of Presidents of the Society	iv
List of Officers and Members for 1891	v—xxvii
Annual Report of Council for 1890-91	xxix
List of Specimens Exhibited during the Session 1890-91	xxxiii
List of Specimens Reported on by the Committee on Morbid Growths	xliv
List of Plates	xlv
List of Figures in the Text	xlvii
Diseases, etc., of the Nervous System	1
Diseases, etc., of the Organs of Respiration	35
Diseases, etc., of the Organs of Circulation	57
Diseases, etc., of the Organs of Digestion	82
Diseases, etc., of the Genito-Urinary Organs	185
Diseases, etc., of the Organs of Motion	232
Diseases, etc., of the Organs of Special Sense	293
Diseases, etc., of the Ductless Glands	298
Diseases, etc., of the Skin	304
Morbid Growths	314
Miscellaneous Specimens	330
Diseases, etc., of the Lower Animals	470
Index	483

Digitized by Google

Presidents of the Society.

ELECTED

1846 CHARLES J. B. WILLIAMS, M.D., F.R.S.
1848 CHARLES ASTON KEY.
1850 PETER MERE LATHAM, M.D.
1852 CÆSAR H. HAWKINS, F.R.S.
1853 BENJAMIN GUY BABINGTON, M.D., F.R.S.
1855 JAMES MONCRIEFF ARNOTT, F.R.S.
1857 SIR THOMAS WATSON, BART., M.D., F.R.S.
1859 SIR WILLIAM FERGUSSON, BART., F.R.S.
1861 JAMES COPLAND, M.D., F.R.S.
1863 SIR PRESCOTT G. HEWETT, BART., F.R.S.
1865 THOMAS BEVILL PEACOCK, M.D.
1867 SIR JOHN SIMON, K.C.B., D.C.L., F.R.S.
1869 SIR RICHARD QUAIN, BART., M.D., LL.D., F.R.S.
1871 JOHN HILTON, F.R.S.
1873 SIR WILLIAM JENNER, BART., M.D., K.C.B., D.C.L., F.R.S.
1875 GEORGE D. POLLOCK.
1877 CHARLES MURCHISON, M.D., LL.D., F.R.S.
1879 JONATHAN HUTCHINSON, F.R.S.
1881 SAMUEL WILKS, M.D., F.R.S.
1883 JOHN WHITAKER HULKE, F.R.S.
1885 JOHN SYER BRISTOWE, M.D., F.R.S.
1887 SIR JAMES PAGET, BART., D.C.L., LL.D., F.R.S.
1889 WILLIAM HOWSHIP DICKINSON, M.D.
1891 SIR GEORGE MURRAY HUMPHRY, M.D., LL.D., F.R.S.

Digitized by Google

OFFICERS AND COUNCIL

OF THE

Pathological Society of London,

ELECTED AT

THE GENERAL MEETING, MAY 19TH, 1891.

President.

SIR GEORGE MURRAY HUMPHRY, M.D., LL.D., F.R.S.

Vice-Presidents.

SIR JOSEPH FAYRER, F.R.S.
WILLIAM TENNANT GAIRDNER, M.D., LL.D.
FREDERICK WILLIAM PAVY, M.D., F.R.S.
P. H. PYE-SMITH, M.D., F.R.S.
HENRY TRENTHAM BUTLIN.
J. NEVILLE C. DAVIES-COLLEY.
J. WARRINGTON HAWARD.
SIR JOSEPH LISTER, BART., D.C.L., LL.D., F.R.S.

Treasurer.

WILLIAM CAYLEY, M.D.

Council.

SIDNEY COUPLAND, M.D.
F. G. DAWTREY DREWITT, M.D.
WILLIAM EWART, M.D.
RICHARD G. HEBB, M.D.
PERCY KIDD, M.D.
DAVID B. LEES, M.D.
FREDERICK WM. MOTT, M.D.
G. NEWTON PITT, M.D.
SAMUEL WEST, M.D.
GERMAN SIMS WOODHEAD, M.D.
CHARLES A. BALLANCE.
WILLIAM HENRY BENNETT.
EDGAR CROOKSHANK, M.B.
R. J. GODLEE, M.S.
WILLIAM HICKMAN, M.B.
JONATHAN HUTCHINSON, JUN.
WILLIAM ARBUTHNOT LANE.
GEORGE HENRY MAKINS.
HERBERT WILLIAM PAGE.
D'ARCY POWER, M.A., M.B.

Honorary Secretaries.

SAMUEL G. SHATTOCK.
F. CHARLEWOOD TURNER, M.D.

Trustees.

SIR RICHARD QUAIN, BART., M.D., F.R.S.
GEORGE D. POLLOCK.
SAMUEL WILKS, M.D., F.R.S.

Digitized by Google

Members of the Morbid Growths Committee.

NORMAN MOORE, M.D.

GEORGE NEWTON PITT, M.D.

F. CHARLEWOOD TURNER, M.D.

SEYMOUR J. SHARKEY, M.D.

ANTHONY A. BOWLBY.

W. WATSON CHEYNE.

HENRY HUGH CLUTTON.

FREDERICK S. EVE.

ROBERT WILLIAM PARKER.

SAMUEL G. SHATTOCK.

Digitized by Google

*** *Members are requested to inform the Secretaries of any corrections which may be necessary.*

LIST OF MEMBERS OF THE SOCIETY.

Honorary Members.

BILLROTH, THEODOR, M.D., Professor of Surgery in the University of Vienna.
BRUCKE, ERNST, M.D., Professor of Physiology in the University of Vienna.
CHARCOT, J. M., M.D., Physician to the "Hôpital de la Salpêtrière," and Professor at the Faculty of Medicine of Paris.
CHAUVEAU, A., M.D., Professor of Physiology at the Medical School of Lyons.
VON HELMHOLTZ, H., M.D., Professor of Physiology in the University of Heidelberg.
JENNER, SIR WILLIAM, Bart., M.D., K.G.C.B., D.C.L., LL.D., F.R.S., Greenwood, Bishop's Waltham, Hants.
LUDWIG, C., M.D., Professor of Physiology in the University of Leipzig.
PASTEUR, PROFESSOR L., Member of the Institute, Paris.
RINDFLEISCH, EDOUARD, M.D., Professor of Pathological Anatomy in the University of Bonn.
SIMON, SIR JOHN, K.C.B., D.C.L., LL.D., F.R.S., 40, Kensington-square, W.
THIERSCH, CARL, M.D., Professor of Surgery in the University of Leipzig.
VIRCHOW, RUDOLF, M.D., Professor of Pathological Anatomy in the University of Berlin.

EXPLANATION OF ABBREVIATIONS.

O.M.—Original Member.
Pres.—President.
T.—Treasurer.
V.-P.—Vice-President.
S.—Secretary.
C.—Member of Council.

Those marked thus (L) have paid Composition Fee for Annual Subscription.
Those marked thus (‡) have paid Composition Fee for Transactions.

Digitized by Google

GENERAL LIST OF MEMBERS.

Elected

L1879 ABERCROMBIE, JOHN, M.D., 23, Upper Wimpole-street, W.
1885 ABRAHAM, PHINEAS S., M.A., M.D., 2, Henrietta Street, W.
1858 ACLAND, Sir HENRY WENTWORTH, Bart., K.C.B., M.D., F.R.S., Broad-street, Oxford.
1883 ACLAND, THEODORE DYKE, M.D., 74, Brook-street, W.
‡1866 ADAMS, ARTHUR BAYLEY.
1890 ADAMS, JAMES, 4, Chiswick-place, Eastbourne.
LO.M. ADAMS, WILLIAM, 5, Henrietta-street, Cavendish-square, W. (C. 1851-4. V.-P. 1867-9.)
L1848 AIKIN, CHARLES A., 7, Clifton-place, Sussex-square, W. (C. 1864-6.)
1872 AIKIN, CHARLES EDMUND, 7, Clifton-place, Sussex-square, W.
1871 AIR, A. CUMMINGS, The Gleevelands, 223, Selhurst-road, South Norwood, S.E.
1880 AITKEN, Sir WILLIAM, M.D., LL.D., F.R.S., Park Villa, Weston-grove-road, Woolston, Southampton.
1882 ALLCHIN, WILLIAM HENRY, M.B., 5, Chandos-street, W.
1877 ALTHAUS, JULIUS, M.D., 48, Harley-street, W.
1884 ANDERSON, ALEXANDER RICHARD, 5, East Circus-street, Nottingham.
1868 ANDERSON, J. FORD, M.D., 41, Belsize-park, N.W.
1880 ANDERSON, JAMES, M.A., M.D., C.M., 41, Wimpole-street, W.
1871 ANDERSON, WILLIAM, 2, Harley-street, W. (C. 1888-90.)
L1863 ANDREW, JAMES, M.D., 22, Harley-street, W. (C. 1868-70. V.-P. 1889-90.)
1887 ABKLE, CHARLES JOSEPH, M.D.
1883 ASHBY, HENRY, M.D., 13, St. John-street, Manchester.
1882 AXE, J. WORTLEY, College House, Great College-street, N.W.

1863 BAGSHAWE, FREDERICK, M.A., M.D., 16, Warrior-square, Hastings.
1864 BAKER, WILLIAM MORRANT, 26, Wimpole-street, W. (C. 1873-6, 1881-3. S. 1878-80. V.-P. 1886-8.)
‡1856 BALDING, DANIEL BARLEY, Royston, Herts.
1889 BALGARNIE, WILFRED, 47, South Molton-street, W.
1880 BALL, BENJAMIN, rue du Faubourg St. Honoré, 3, Paris.
1881 BALLANCE, CHARLES A., M.S., 56, Harley-street, W. (C. 1890-1.)
1875 BARKER, ARTHUR E. J., 87, Harley-street, W. (C. 1884-6.)
1885 BARLING, GILBERT, M.B., 85, Edmund-street, Birmingham.
1874 BARLOW, THOMAS, M.D., B.S., 10, Wimpole-street, W. (C. 1879-81.)
1862 BARRATT, JOSEPH GILLMAN, M.D.
1877 BARROW, A. BOYCE, 37, Wimpole-street, W.
1881 BARRS, ALFRED GEORGE, M.D., 22, Park-place, Leeds.
1879 BARTLETT, HENRY, M.D., Defoe-road, Tooting-corner, S.W.
L1853 BARWELL, RICHARD, 55, Wimpole-street, W. (C. 1862-4. V.-P. 1889-90.)

Digitized by Google

Elected

1861 BASTIAN, H. CHARLTON, M.A., M.D., F.R.S., 8A, Manchester-square, W. (C. 1869-71. V.-P. 1885-7.)

1877 BATEMAN, ARTHUR W., B.A., Tenterfield, New South Wales.

L1876 BATTESON, JOHN, 26, Windsor-road, Forest-gate, E.

1882 BATTLE, WILLIAM HENRY, 6, Harley-street, W.

1870 BÄUMLER, CHRISTIAN G. H., M.D., University of Erlangen.

1874 BEACH, FLETCHER, M.B., Metropolitan District Asylum, Darenth, near Dartford, Kent.

1879 BEALE, EDWIN CLIFFORD, M.B., 23, Upper Berkeley-street, W.

1852 BEALE, LIONEL S., M.B., F.R.S., 61, Grosvenor-street, W. (C. 1858-9. V.-P. 1874-5.)

1856 BEALEY, ADAM, M.D., M.A., Oak-lea, Harrogate.

1870 BECK, MARCUS, M.S., 30, Wimpole-street, W. (C. 1875-7. V.-P. 1888-9.)

1865 BEEBY, WALTER, M.D., Bromley, Kent.

L1880 BEEVOR, CHARLES EDWARD, M.D., 33, Harley-street, W. (C. 1888-90.)

1883 BENHAM, ROBERT FITZROY, Abercorn House, Castletown-road, West Kensington, W.

1886 BENNETT, FREDERICK JOSEPH, 24, George-street, Hanover-square, W.

1877 BENNETT, WILLIAM HENRY, 1, Chesterfield-street, W. (C. 1891.)

1889 BENTLEY, ARTHUR, J.M., M.D., 9, Somers Place, W.

1878 BERNARD, FRANCIS R., M.D.

1882 BERRIDGE, WILLIAM ALFRED, Redhill, Surrey.

1886 BERRY, JAMES, 60, Welbeck-street, W.

1891 BEVILLE, FREDERICK WELLS, The Firs, Palace-road, East Molesey.

‡1856 BICKERSTETH, EDWARD R., 2, Rodney-street, Liverpool.

1889 BIDWELL, LEONARD ARTHUR, 21, Bentinck-street, W.

1882 BINDLEY, PHILIP HENRY, M.B., Branksome-road, St. Leonard's-on-Sea.

1890 BINDLEY, ROBERT ALFRED, Inter. M.B., 35, Highbury-hill, N.

1878 BINDON, WILLIAM JOHN VEREKER, M.D., 18, St. Ann's-street, Manchester.

L1850 BIRKETT, EDMUND LLOYD, M.D., Westbourne Rectory, Emsworth, Hampshire. (C. 1856-7.)

1881 BISS, CECIL YATES, M.D., 135, Harley-street, W.

1865 BISSHOPP, JAMES, Bedford-place, Tunbridge Wells.

1877 BLACK, JAMES, Hillside, Hermitage-road, Norwood.

1889 BLACK, ROBERT, M.D., 6, Pavilion Parade, Brighton.

1850 BLAGDEN, ROBERT, Stroud, Gloucestershire.

1863 BLANCHET, JEAN B., M.D., M.S., Montreal, Quebec, Canada.

1876 BLASSON, WILLIAM, Edgeware, Middlesex.

1879 BOILEAU, J. P. H., M.D., Brigade-Surgeon, Army.

1876 BOND, THOMAS, M.B., 7, Broad Sanctuary, Westminster, S.W.

1869 BOURNE, WALTER, M.D., Archacho, France.

1861 BOWER, RICHARD NORRIS, Ivel Lodge, Sandy, Bedfordshire.

Digitized by Google

Elected

1881 Bowley, Anthony A., 75, Warrington-crescent, Maida Vale, W. (C. 1886–8.)

1851 Bowman, Sir William, Bart., F.R.S., 5, Clifford-street, W. (C. 1855-6. V.P. 1882-4.)

1882 Boyd, Stanley, M.B., 134, Harley-street, W.

1889 Bradford, John Rose, M.B., 52, Upper Berkeley-street, W.

1883 Bradshaw, James Dixon, M.B., 30, George-street, Hanover-square, W.

1879 Brailey, Wm. Arthur, M.D., 11, Old Burlington-street, W.

1880 Bramwell, Byrom, M.D., 23, Drumsheugh-gardens West, Edinburgh.

1889 Bredin, J. Noble, 1, Norton Folgate, E.

1877 Bridges, Robert, M.B., M.A., Manor House, Yattendon, Berks.

‡1867 Bridgewater, Thomas, LL.D. Glas., M.B. Lond., Harrow-on-the-Hill, Middlesex.

1873 Briggs, Jacob Myers, M.D., Coeymans, New York, U.S.

1868 Bright, George Charles, M.D., Cannes, Alpes Maritimes, France.

1857 Briscoe, John, 12, Broad-street, Oxford.

1885 Briscoe, John F., The Lammas, Esher, Surrey.

L1851 Bristowe, John S., M.D., F.R.S., 13, Old Burlington-street, W. (C. 1854-8. S. 1861-4. C. 1865-7. V.-P. 1868-76, 1887. P. 1885-6.)

1860 Broadbent, William Henry, M.D., 34, Seymour-street, W. (C. 1871-3. V.P. 1882-4.)

1886 Brockatt, Andrew Alexander, St. Cuthbert's, Malvern.

L1852 Brodhurst, Bernard E., 20, Grosvenor-street, W. (C. 1862-4.)

1884 Brodie, Charles Gordon, 30, Harley-street. W.

1863 Brodie, George Bernard, M.D., 3, Chesterfield-street, Mayfair, W.

L1865 Brown, Augustus, M.D., 10, Chichester-place, Kemp Town, Brighton.

1871 Brown, Frederick Gordon, 17, Finsbury-circus, E.C.

1875 Browne, George Buckston, 80, Wimpole-street, Cavendish-square, W.

L1866 Browne, Lennox, 36, Weymouth-street, W.

1877 Bruce, J. Mitchell, M.D., 70, Harley-street, W.

1890 Brunton, T. Lauder, M.D., D.Sc., LL.D., F.R.S., 10, Stratford-place, W.

L1855 Bryant, Thomas, 65, Grosvenor-street, W. (C. 1863-6. V.-P. 1877-9.)

L1854 Buchanan, George, M.D., F.R.S., 27, Woburn-square, W.C. (C. 1864-6. V.-P. 1880-2.)

1890 Buckland, Francis O., M.A., M.B., C.M., 6, Lower Sloane-street, S.W.

1887 Bull, William Charles, M.B., 35, Clarges-street, Piccadilly.

1891 Burghard, Frederic Francois, M.D., M.S., 46, Weymouth-street, W.

1878 Burnet, Robert William, M.D., 6, Upper Wimpole-street, W.

1880 Burton, Samuel Herbert, M.B., Norfolk and Norwich Hospital, Norwich.

1887 Butler-Smythe, Albert Charles, 76, Brook-street, W.

1872 Butlin, Henry Trentham (C.), 82, Harley-street, W. (C. 1876-8, 1887-9. S. 1884-6. V.-P. 1891.)

1866 Butt, William Frederick.

Digitized by Google

Elected

1883 Buxton, Dudley W., M.D., 82, Mortimer-street, W.
1856 Buzzard, Thomas, M.D., 74, Grosvenor-street, W. (C. 1869-70. V.-P. 1881-3.)

1885 Cahill, John, 12, Seville-street, Lowndes-square, S.W.
1891 Carless, Albert, M.S., M.B., 15, Stratford-place, W.
‡1855 Carpenter, Alfred, M.D., Duppas House, Croydon.
1890 Carpenter, George Alfred, M.D., 1, St. Ermin's Mansions, Westminster, S.W.
1855 Carter, H. Vandyke, M.D.
1876 Carter, Robert Brudenell, 27, Queen Anne-street, W.
1879 Cassidy, Joseph Lamont, M.D., 44, Harley-street, W.
1877 Casson, John Hornsey.
L1868 Cavafy, John, M.D., 2, Upper Berkeley-street, W. (C. 1881-3.)
1864 Cay, Charles Vidler, Deputy Surgeon-General, Army.
1863 Cayley, William, M.D. (Treasurer), 27, Wimpole-street, W. (C. 1870-1, 1875-8. S. 1872-4. V.-P. 1884-6. T. 1888-91.)
1869 Chaffers, Edward, Keighley, Yorkshire.
1884 Chaffey, Wayland Charles, M.B., 13, Montpellier-road, Brighton.
1891 Chaplin, Arnold, M.B., City of London Hospital for Diseases of the Chest, Victoria Park, N.E.
1876 Charles, T. Cranstoun, M.D., M.C., Albert Mansions, 106, Victoria-street, Westminster, S.W.
1884 Chavasse, Thomas Frederick, M.D., C.M., 24, Temple-row, Birmingham.
1879 Cheyne, William Watson, M.B., C.M., 59, Welbeck-street, W. (C. 1885-7.)
1858 Child, Gilbert W.
1873 Chisholm, Edwin, M.D., Abergeldie, Ashfield, near Sydney, New South Wales [care of Messrs. Dawson, 121, Cannon-street, E.C.].
1871 Christie, Thomas Beath, M.D., Royal India Asylum, Ealing, Middlesex.
1865 Church, William Selby, M.D., 130, Harley-street, W. (C. 1871-3.)
L1868 Churchill, Frederick, M.B., 4, Cranley-gardens, Queen's-gate, S.W.
L1861 Clapton, Edward, M.D., 22, St. Thomas's-street, Southwark, S.E.
1854 Clark, Sir Andrew, Bart., M.D., LL.D., F.R.S., 16, Cavendish-square, W. (C. 1862-5. V.-P. 1881-3.)
1872 Clark, Andrew, 71, Harley-street, W.
1886 Clark, Francis William, Hedworth Villa, *viâ* East Boldon, Durham.
1883 Clarke, Ernest, M.D., B.S., 41, Lee-terrace, Blackheath, S.E.
1891 Clarke, J. J., M.B., St. Mary's Hospital, W.
1885 Clarke, John Michell, M.B., 2, York Buildings, Clifton, Bristol.
1881 Clarke, W. Bruce, M.B., 46, Harley-street, W.
L1875 Clutton, Henry Hugh, M.A., 2, Portland-place, W. (C. 1884-6.)
‡1865 Coates, Charles, M.D., 10, Circus, Bath.
1885 Coats, Joseph, M.D., 31, Lynedoch-street, Glasgow.
1856 Cockle, John, M.D., M.A., 5, Suffolk-place, S.W.

Digitized by Google

Elected

1886 COLLIER, WILLIAM, M.D., 62, High-street, Oxford.
1891 COLLINS, EDWARD TREACHER, 47, Devonshire-street, W.
1888 COLLINS, WILLIAM JOB, M.D., M.S., 1, Albert-terrace, Regent's-park, N.W.
1879 COLLINS, WM. MAUNSELL, M.D., 10, Cadogan-place, S.W.
1878 COLLYNS, R. T. POOLE, 20, Lingfield-road, Wimbledon.
1888 COLMAN, WALTER STACY, M.B., Bridge-street, Peterborough.
1882 COLQUHOUN, DANIEL, M.D., Dunedin, New Zealand.
1882 COMPTON, FRANCIS CHARLES, 72, High-street, Poole, Dorset.
1891 COOK, HERBERT G. GRAHAM, 162, Cromwell-road, S.W.
1858 COOKE, R. T. E. BARRINGTON, 15, St. Nicholas-cliff, Scarborough, Yorkshire.
1871 COOKE, THOMAS, 40, Brunswick-square, W.C.
1866 COOMBS, ROWLAND HILL, Mill-street, Bedford.
1879 COOPER, ARTHUR, 20, Old Burlington-street, W.
1889 COPEMAN, SYDNEY ARTHUR MONCKTON, M.A., M.D., Local Government Board, Whitehall, S.W.
1875 CORY, ROBERT, M.D., 73, Lambeth Palace-road, S.E.
1876 COTTLE, WYNDHAM, M.D., 3, Savile-row, W.
L1861 COUPER, JOHN, 80, Grosvenor-street, W. (C. 1870-2.)
1873 COUPLAND, SIDNEY, M.D., 16, Queen Anne-street, W. (C. 1878-81, 1889-91. S. 1886-8.)
1884 CRICHTON, GEORGE, M.B., 3, Cambridge-villas, Twickenham.
1873 CRIPPS, WILLIAM HARRISON, 2, Stratford-place, W. (C. 1883-5.)
1877 CROCKER, HENRY RADCLIFFE, M.D., 121, Harley-street, W. (C. 1887-9.)
1856 CROFT, JOHN, 48, Brook-street, W. (C. 1870-2. V.-P. 1882-4.)
1879 CROOKE, GEORGE FREDERICK, M.D., 2, Edmund-street, Birmingham.
1886 CROOKSHANK, EDGAR, M.B., Saint Hill, near East Grinstead, Sussex. (C. 1890-1.)
1861 CROSBY, THOMAS BOOR, M.D., 21, Gordon-square, W.C.
1875 CROSS, FRANCIS RICHARDSON, 5, The Mall, Clifton, Bristol.
1890 CROWLE, THOMAS H. RICKARD, 3, Campden Hill-road, W.
1889 CUFF, ROBERT, M.B., Huntriss-row, Scarborough.
1885 CULLINGWORTH, CHARLES JAMES, M.D., 46, Brook-street, W.
1871 CUMBERBATCH, ELKIN, 17, Queen Anne-street, W.
1873 CURNOW, JOHN, M.D., 3, George-street, Hanover-square, W. (C. 1882-4.)
‡1865 CURRAN, WILLIAM, M.D. [33, Auriol-road, West Kensington, W.], care of Mr. Lewis, Gower-street.

1884 DAKIN, W. RADFORD, M.D., B.S., 57, Welbeck-street, W.
1884 DALLAWAY, DENNIS, 5, Duchess-street, W.
1883 DALTON, NORMAN, M.D., 14, Clement's-inn, Strand, W.C.
1873 DAVIDSON, ALEXANDER, M.D., 2, Gambier-terrace, Liverpool.
1885 DAVIES, ARTHUR, M.B., 23, Finsbury-square, E.C.
L1869 DAVIES-COLLEY, J. NEVILLE C., M.B., 36, Harley-street, W. (C. 1880-2. V.-P. 1890-1.)

Digitized by Google

Elected

1883 DAVIS, EDWIN HARRY, West Hartlepool.

‡1859 DAVIS, FRANCIS WILLIAM, R.N. [Agents: Messrs. Hallett and Co., 7, St. Martin's-place, Trafalgar-square, W.C.]

1879 DAVY, HENRY, M.D., 29, Southernhay, Exeter.

1866 DAY, WILLIAM HENRY, M.D., 10, Manchester-square, W.

1887 DELÉPINE, SHERIDAN, M.B., 6, Chapel-place, W.

1880 DENT, CLINTON T., 61, Brook-street, W.

1863 DEVEREUX, DANIEL, Tewkesbury, Gloucestershire.

1856 DICK, H., M.D.

1871 DICKINSON, EDWARD HARRIMAN, M.A., M.D., 162, Bedford-street, Liverpool.

L1858 DICKINSON, WILLIAM HOWSHIP, M.D., 9, Chesterfield-street, W. (C. 1866-8. S. 1869-71. V.-P. 1872-4. P. 1889-90.)

L1890 DICKINSON, WILLIAM LEE, M.B., 9, Chesterfield-street, W.

1872 DIVER, EBENEZER, M.D., Kenley, Caterham-valley, Surrey.

1872 DORAN, ALBAN HENRY GRIFFITHS, 9, Granville-place, W. (C. 1882-4.)

1888 DOVE, AUGUSTUS CHARLES, M.B., B.S., Parkside, Crescent-road, Crouch End, N.

L1866 DOWN, JOHN LANGDON H., M.D., 81, Harley-street, W. (C. 1872-4.)

1877 DRAKE-BROCKMAN, E. F., Madras Medical Service [care of Mr. Lewis, Gower-street, W.C.].

1880 DRESCHFELD, JULIUS, M.D., 325, Oxford-road, Manchester.

1879 DREWITT, F. G. DAWTREY, M.D., 42, Brook-street, W. (C. 1890-1.)

1865 DUCKWORTH, Sir DYCE, M.D., 11, Grafton-street, Bond-street, W. (C. 1877.)

L1847 DUDGEON, ROBERT E., M.D., 53, Montagu-square, W.

1865 DUFFIN, ALFRED BAYNARD, M.D., 18, Devonshire-street, Portland-place, W. (C. 1872-4.)

1868 DUKE, OLIVER THOMAS, M.B., India.

1871 DUKES, CLEMENT, M.D., B.S., Sunnyside, Rugby.

1877 DUNBAR, J. J. MACWHIRTER, M.D., Hedingham House, Clapham-common, S.W.

1877 DUNCAN, ANDREW, M.D., 8, Henrietta-street, Covent-garden, W.C.

1889 DUNCAN, JOHN, M.D., St. Petersburg.

1884 DUNN, LOUIS ALBERT, M.B., M.S., 10, St. Thomas's-street, S.E.

1858 DURHAM, ARTHUR EDWARD, 82, Brook-street, W. (C. 1869-71. V.P. 1883-5.)

1879 DURHAM, FREDERIC, M.B., 82, Brook-street, W.

L1880 EDMUNDS, WALTER, M.D., 75, Lambeth Palace-road, S.E.

1882 EDWARDS, F. SWINFORD, 55, Harley-street, W.

1889 ELAM, WILLIAM HENRY, New Barnet, Herts.

1883 ELDER, GEORGE, M.D., 17, Regent-street, Nottingham.

Digitized by Google

Elected

1867 Ellis, James, M.D., California.

1873 Engelmann, George Julius, M.D., A.M., 3003, Locust-street, St. Louis, Miss., U.S.

L1846 Erichsen, John Eric, LL.D., F.R.S., 6, Cavendish-place, W. (C. 1849-51. V.-P. 1863-4.)

1853 Evans, Conway, M.D., 5, Tavistock-street, Covent Garden, W.C. (C. 1867-8.)

1875 Evans, Julian, A.M., M.D., 123, Finborough-road, Redcliffe-square, West Brompton, S.W.

1879 Eve, Frederic S., 125, Harley-street, W. (C. 1885-7.)

1876 Ewart, James Cossar, M.B., C.M., School of Medicine, Edinburgh.

1881 Ewart, Joseph, M.D., Montpellier Terrace, Brighton.

1877 Ewart, William, M.D., 33, Curzon-street, W. (C. 1889-1.)

‡1859 Ewens, John, 14, Whiteladies-road, Clifton, Bristol.

1887 Eyles, Charles Henry, Gold Coast Colony.

1889 Fairbank, Frederick Royston, M.D., 46, Hallgate, Doncaster.

1872 Fayrer, Sir Joseph, K.C.S.I., M.D. LL.D., F.R.S., 53, Wimpole-street, W. (C. 1880-2. V.-P. 1890-1.)

1872 Fenn, Edward L., M.B., The Old Palace, Richmond, Surrey.

1883 Fenwick, E. Hurry, 5, Old Burlington-street, W.

1872 Fenwick, John C. J., M.D., 25, North-road, Durham.

1863 Fenwick, Samuel, M.D., 29, Harley-street, W.

1885 Féré, Charles, M.D., Médecin de Bicêtre; Boulevard St. Michel, 37, Paris.

1876 Finlay, David W., M.D., Aberdeen. (C. 1886-8.)

1859 Fisher, Alexander, M.D., 2, Bruntsfield Gardens, Edinburgh.

1882 Fleming, George, C.B., LL.D., 98, Tyrwhitt-road, St. John's, S.E.

1872 Forbes, Daniel Mackay, Shoreditch Infirmary, 204, Hoxton-street, N.

‡1866 Foster, Sir Balthazar Walter, M.D., M.P., 55, Temple-row, Birmingham.

1872 Fotherby, Henry J., M.D., Woodthorpe Cotes, Reigate.

1891 Foulerton, Alexander Grant Russell, 122, Brompton-road, S.W.

1880 Fowler, James Kingston, M.A., M.D., 35, Clarges-street, W. (C. 1887-8.)

1878 Fox, Thomas Colcott, M.B., B.A., 14, Harley-street, W.

1858 Francis, Charles Richard, M.B., Bengal Medical Establishment, Indian Army.

1886 Freeman, Henry William, 24, Circus, Bath.

O.M. Frere, J. C.

1891 Fripp, Alfred Downing, M.B., B.S., 65, Harley-street, W.

1864 Frodsham, John Mill, M.D., Streatham, S.W.

Digitized by Google

Elected

1880 GABBETT, HENRY SINGER, M.B., 20, Burlington-place, Eastbourne.

‡1858 GAIRDNER, WILLIAM TENNANT, M.D., LL.D.Edin., 225, St. Vincent-street, Glasgow. (V.-P. 1891.)

1890 GALLOWAY, JAMES, M.A., M.B., London Hospital, E.

1870 GALTON, JOHN H., M.D., 39, Anerley-road, Upper Norwood, S.E.

1855 GAMGEE, J.

L1846 GARROD, Sir ALFRED BARING, M.D., F.R.S., 10, Harley-street, W. (C. 1851. V.-P. 1863-5.)

1879 GARSTANG, THOMAS WALTER HARROPP, Headingley House, Knutsford, Cheshire.

1872 GARTON, WILLIAM, M.D., 58, Bagot-street, Wavertree, Liverpool.

1880 GIBBES, HENEAGE, M.B., University of Michigan, Ann Arbor, Michigan, U.S.A.

L1853 GIBBON, SEPTIMUS, M.D., 39, Oxford-terrace, Hyde-park, W.

1878 GIBBONS, R. A., M.D., 29, Cadogan-place, S.W.

1876 GILL, JOHN, M.D., 31, Apsley-road, Clifton, Bristol.

1881 GLYNN, THOMAS ROBINSON, M.D., 62, Rodney-street, Liverpool.

1873 GODLEE, RICKMAN JOHN, M.B., B.S., 19, Wimpole-street, W. (C. 1877-80. 1891. S. 1887-9.)

1875 GODSON, CLEMENT, M.D., 9, Grosvenor-street, W.

1879 GODWIN, CHARLES HENRY YOUNG, Surgeon Major, Army; Victoria Hospital, Netley.

1878 GOLDING-BIRD, CUTHBERT H., M.B., 12, Queen Anne-street, W. (C. 1885-7.)

1890 GOODALL, E. WILBERFORCE, M.D., Guy's Hospital, S.E.

1871 GOODHART, JAMES FREDERIC, M.D., 25, Weymouth-street, W. (C. 1876-8, 1886-8. S. 1883-5.)

1875 GOULD, ALFRED PEARCE, M.S., 16, Queen Anne-street, W. (C. 1883-5.)

1870 GOWERS, WILLIAM RICHARD, M.D., F.R.S., 50, Queen Anne-street, W. (C. 1878-9.)

L1858 GOWLLAND, PETER Y., 34, Finsbury-square, E.C.

1888 GRANT, J. DUNDAS, M.A., M.D., C.M., 17, Finsbury Square, E.C.

1891 GRANT, JAMES E. R., Charing Cross Chambers, Duke-street, W.C.

1867 GREEN, T. HENRY, M.D., 74, Wimpole-street, W. (C. 1871-3, 1878-9. S. 1875-6. V.-P. 1886-8.)

1873 GREENFIELD, WILLIAM SMITH, M.D., B.S., 7, Heriot-row, Edinburgh. (C. 1877-80.)

‡1855 GREENHILL, WILLIAM ALEXANDER, M.D., 5, The Croft, Hastings.

1886 GREVES, EDWIN HYLA, M.D., Rodney House, Suffolk-road, Bournemouth.

1885 GRIFFITH, WALTER SPENCER ANDERSON, M.B., 114, Harley-street, W.

1887 GRIFFITHS, JOSEPH, M.B., C.M., 16, Panton-street, Cambridge.

1876 GRIFFITHS, THOMAS D., M.D., Hearne Lodge, Swansea.

Digitized by Google

Elected

1882 GROSS, CHARLES, M.D., M.S., 112, Westbourne-grove, W.
1861 GUENEAU DE MUSSY, HENRI, M.D., 15, Rue du Cirque, Paris.
1880 GUNN, R. MARCUS, M.B., C.M., 54, Queen Anne-street, W.
1876 GWYTHER, JAMES, M.B.

1887 HABERSHON, SAMUEL HERBERT, M.D., 70, Brook-street, W.
L1851 HACON, E. DENNIS, 269, Mare-street, Hackney, N.E. (C. 1872.)
1879 HADDEN, WALTER BAUGH, M.D., 21, Welbeck-street, W. (C. 1886-8.)
1882 HAIG, A., M.B., 7, Brook-street, W.
1877 HALLOWES, FREDERICK BLACKWOOD, Redhill, Surrey.
1890 HAMER, WILLIAM HEATON, M.B., Ladywell, Dartmouth Park Hill, Highgate, N.
1886 HAMILTON, DAVID JAMES, M.B., 1, Albyn-place, Aberdeen.
1890 HANDFIELD-JONES, MONTAGU, M.D., 35, Cavendish-square, W.
1886 HANDFORD, HENRY, M.D., 14, Regent-street, Nottingham.
1882 HARBINSON, ALEXANDER, M.D., County Lunatic Asylum, Lancaster.
L1848 HARE, CHARLES JOHN, M.D., Berkeley House, 15, Manchester-square, W. (C. 1852-4. V.-P.1874-7.)
L1856 HARLEY, GEORGE, M.D., F.R.S., 25, Harley-street, W. (C. 1862-5. V.-P. 1878-80.)
1872 HARRIS, HENRY, M.D., Trengweath-place, Redruth, Cornwall.
1879 HARRIS, VINCENT DORMER, M.D., 31, Wimpole-street, W.
L1858 HART, ERNEST, 38, Wimpole-street, W. (C. 1867-8.)
1870 HAWARD, JOHN WARRINGTON, 16, Savile-row, W. (C. 1879-81. V.-P. 1890-1.)
1886 HAWKINS, FRANCIS HENRY, M.B., 59, Wimpole-street, W.
1890 HAWKINS, HERBERT PENNELL, M.B., 38, Weymouth-street, W.
L1856 HEATH, CHRISTOPHER, 36, Cavendish-square, W. (C. 1866-7. V.-P. 1879-81.)
1881 HEBB, RICHARD G., M.D., 9, Suffolk-street, S.W. (C. 1891.)
1884 HEBBERT, CHARLES ALFRED.
1878 HELLIER, JOHN B., M.B., Headingley, Leeds.
1879 HENDERSON, GEORGE COURTENAY, M.D., Kingston, Jamaica, West Indies.
1869 HENSLEY, PHILIP J., M.D., 4, Henrietta-street, W.
1884 HERRINGHAM, WILMOT PARKER, M.B., 13, Upper Wimpole-street, W.
1855 HEWITT, GRAILY, M.D., 36, Berkeley-square, W. (C. 1865-7.)
1864 HICKMAN, WILLIAM, M.B., 1, Dorset-square, N.W. (C. 1890-1.)
1860 HILL, M. BERKELEY, M.B., 66, Wimpole-street, Cavendish-square, W. (C. 1874-5.)
1875 HITCHCOCK, HARRY KNIGHT, M.D., Christowell, Branksome-park, Bournemouth, Hants.
1880 HOBSON, JOHN MORRISON, M.D., Glendalough, Morland-road, Croydon.
L1854 HOLMES, TIMOTHY, 18, Great Cumberland-place, W. (C. 1862-3. S. 1864-7. C. 1868. V.-P. 1869-71.)
L1850 HOLT, BARNARD WIGHT, 14, Savile-row, W. (C. 1853.)

Digitized by Google

Elected

O.M. HOLTHOUSE, CARSTEN. (C. 1852-4, V.-P. 1874-5.)
1878 HOOD, DONALD WILLIAM CHARLES, M.D., 43, Green-street, W.
1864 HOOD, WHARTON P., M.D., 11, Seymour-street, W.
1870 HOPE, WILLIAM, M.D., 56, Curzon-street, W.
1882 HOPKINS, JOHN, Central London Sick Asylum, Cleveland-street, W.
1879 HORROCKS, PETER, M.D., 26, St. Thomas's-street, S.E.
1883 HORSLEY, VICTOR, M.B., B.S., F.R.S., 33, Seymour-street, W. (C. 1888-9.)
L1880 HOVELL, T. MARK, 3, Mansfield-street, W.
1875 HOWSE, HENRY GREENWAY, M.S., 59, Brook-street, W. (C. 1878-81.)
1884 HUDSON, CHARLES ELLIOTT LEOPOLD BARTON 6, Chandos-street, W.
L1856 HUDSON, JOHN, M.D., 11, Cork-street, W.
L1854 HULKE, JOHN WHITAKER, F.R.S., 10, Old Burlington-street, W. (C. 1863-5. S. 1868-72. V.-P. 1873-6, 1885-6. T. 1877-9. P. 1883-4.)
1874 HUMPHREYS, HENRY, M.D., 16, Warrior Gardens, St. Leonards-on-Sea.
1883 HUMPHRY, Sir GEORGE MURRAY, M.D. (PRESIDENT), LL.D., F.R.S., University of Cambridge. (P. 1891.)
1888 HUNTER, WILLIAM, M.D., 66, Wimpole-street, W.
1852 HUTCHINSON, JONATHAN, F.R.S., 15, Cavendish-square, W. (C. 1856-9. V.-P. 1872-3, 1881-3. P. 1879-80.)
1882 HUTCHINSON, JONATHAN, jun., 12, Old Cavendish-street, W. (C. 1889-91.)
1884 HUTTON, HENRY RICHMOND, M.B., 8A, St. John-street, Manchester.
1889 HYSLOP, THEOPHILUS BULKELEY, M.B., C.M., Bethlem Royal Hospital, S.E.

1880 INGRAM, ERNEST FORTESCUE, Newcastle, Natal, S. Africa.

1886 JACKSON, ARTHUR MOLYNEUX, M.D., Middlesex County Asylum, Tooting, S.W.
1865 JACKSON, J. HUGHLINGS, M.D., F.R.S., 3, Manchester-square, W. (C. 1872-3. V.-P. 1888-9.)
1886 JACKSON, PHILIP J., 216, Great Dover-street, S.E.
1887 JACOB, ERNEST HENRY, M.D., 12, Park-street, Leeds.
1875 JALLAND, WILLIAM HAMERTON, St. Leonard's House, Museum-street, York.
1888 JAMES, J. T., 30, Harley-street, W.
‡1853 JARDINE, JOHN LEE, Capel, near Dorking, Surrey.
1881 JENNINGS, WILLIAM OSCAR, M.D., 8, Rue Roy, Paris.
1879 JESSOP, CHARLES MOORE, 98, Sutherland-avenue, W.
1866 JESSOP, THOMAS RICHARD, 31, Park-square, Leeds.
1878 JOHNSON, ARTHUR JUKES, Yorkville, Ontario, Canada.
1876 JOHNSON, CHARLES HENRY, Winton House, Basingstoke, Hants.
LO.M. JOHNSON, GEORGE, M.D., F.R.S., 11, Savile-row, W. (C. 1846-50. V.-P. 1863-4, 1884-6. T. 1880-3.)
1888 JOHNSON, RAYMOND, M.B., B.S., 123, Gower-street, W.C.
1881 JOHNSTON, JOSEPH, M.D., 24, St. John's Wood-park, N.W.

Digitized by Google

Elected

1854 JOHNSTONE, ATHOL A. W., St. Moritz House, 61, Dyke-road, Brighton.
L1853 JONES, SYDNEY, M.B., 16, George-street, Hanover-square, W. (C. 1864-6. V.-P. 1886-7.)
1888 JONES, TALFOURD, M.B., Eastbourne.
1862 JONES, THOMAS RIDGE, M.D., 4, Chesham-place, S.W. (C. 1882-4.)
1886 JULER, HENRY EDWARD, 77, Wimpole-street, W.

1890 KANTHACK, A. A., M.B., B.S., St. John's College, Cambridge.
1867 KELLY, CHARLES, M.D., Broadwater-road, Worthing, Sussex. (C. 1874.)
L1846 KENT, THOMAS J., 89, Piccadilly, W.
1852 KERSHAW, W. WAYLAND, M.D., Kingston-on-Thames.
1879 KESTEVEN, WILLIAM HENRY, 372, Camden-road, N.
1859 KIALLMARK, HENRY WALTER, 5, Pembridge-gardens, W. (C. 1875-6.)
1882 KIDD, PERCY, M.D., 60, Brook-street, W. (C. 1889-91.)
1867 KING, EDWIN HOLBOROW, Netley Court, Southampton.
1871 KING, ROBERT, M.B., Boyfield House, Moulton, Spalding, Lincolnshire.
L1852 KINGDON, J. ABERNETHY, 2, Bank-buildings, E.C.
1878 KLEIN, EDWARD EMANUEL, M.D., F.R.S., 19, Earl's Court-sq., S.W. (C. 1888-9.)
1888 KYNSEY, WILLIAM RAYMOND, C.M.G., Colombo, Ceylon.

1878 LANCEREAUX, ETIENNE, M.D., 44, Rue de la Bienfaisance, Paris.
1882 LANE, WILLIAM ARBUTHNOT, M.B., M.S., 8, St. Thomas's-street, S.E. (C. 1891.)
1865 LANGTON, JOHN, 62, Harley-street, W. (C. 1882-4.)
1886 LANKESTER, HERBERT, M.D., 1, Elm-park-gardens, S.W.
1869 LARCHER, O., M.D.Par., 97, Rue de Passy, Paris. [M. Kliensieck, Libraire, Rue de Lille, 11, Paris, per Messrs. Longmans.]
1884 LARDER, HERBERT, Whitechapel Infirmary, Bakers-row, E.
1873 LATHAM, PETER WALLWORK, M.D., 17, Trumpington-street, Cambridge.
1876 LAW, WILLIAM THOMAS, M.D., 9, Norfolk-crescent, W.
1883 LAWFORD, JOHN BOWRING, M.D., C.M., 55, Queen Anne-street, W.
1853 LAWRENCE, HENRY JOHN HUGHES, Picton House, Llandowror, St. Clears. (C. 1873-5.)
1887 LAWSON, BERNARD, Timaru, Canterbury, New Zealand.
1859 LAWSON, GEORGE, 12, Harley-street, W. (C. 1870-1. V.-P. 1884-5.)
1879 LAYCOCK, GEORGE LOCKWOOD, M.B., Melbourne, Victoria, Australia.
1875 LEDIARD, HENRY AMBROSE, M.D., 41, Lowther-street, Carlisle.
L1852 LEE, HENRY, 9, Savile-row, W. (C. 1860-2. V.-P. 1875-6.)
1879 LEECH, DANIEL JOHN, M.D., 96, Mosley-street, Manchester.
1877 LEES, DAVID B., M.D., 22, Weymouth-street, W. (C. 1890-1.)
1867 LEES, JOSEPH, M.D., 21, Brixton-road, S.W.
1877 LEESON, JOHN RUDD, M.D., C.M., 6, Clifden-road, Twickenham.
1868 LEGG, JOHN WICKHAM, M.D. (C. 1874-5.)
1884 LEONARD, HENRY JAMES, M.B., 279, Camden-road, N.

Digitized by Google

Elected

1861 LICHTENBERG, GEORGE, M.D., 47, Finsbury-square, E.C.
1889 LIGHT, EDWIN MELLOR, M.B., B.C., The Infirmary, Leeds.
1875 LINGARD, ALFRED, 1, St. Ermin's Mansions, Westminster, S.W.
1877 LISTER, Sir JOSEPH, Bart., D.C.L., LLD., F.R.S., 12, Park-crescent, W. (C. 1880-2. V.-P. 1887-8, 1891.)
1889 LITTLE, JOHN FLETCHER, M.B., 60, Welbeck-street, W.
L1862 LITTLE, LOUIS S., China.
1878 LITTLEJOHN, SALTER G., M.B., C.M., Central London District Schools, Hanwell.
1874 LIVEING, EDWARD, M.D., 52, Queen Anne-street, W.
L1863 LIVEING, ROBERT, M.D., 11, Manchester-square, W. (C. 1876.)
1882 LOCKWOOD, C. B., 19, Upper Berkeley-street, W.
1876 LONGHURST, ARTHUR EDWIN TEMPLE, M.D., 4, Eaton Square, S.W. (C. 1885-7.)
1881 LUBBOCK, MONTAGU, M.D., 19, Grosvenor-street, W.
1873 LUCAS, R. CLEMENT, M.B., M.S., 18, Finsbury-square, E.C. (C. 1883-5.)
1880 LUND, EDWARD, 22, St. John-street, Manchester.
1879 LUNN, JOHN REUBEN, St. Marylebone Infirmary; Rackham-street, Ladbroke-grove-road, W.
1887 LYON, THOMAS GLOVER, M.D., 39, King-street, Cheapside, E.C.

1871 MACCARTHY, JEREMIAH, M.A., 15, Finsbury-square, E.C. (C. 1878-80.)
1873 MCCONNELL, J. F.
1871 MAC CORMAC, Sir WILLIAM, 13, Harley-street, W. (C. 1878-80.)
1882 MACKENZIE, FREDERIC MORELL, 29, Hans-place, S.W.
1870 MACKENZIE, GEORGE WELLAND, 13, William-street, S.W.
1885 MACKENZIE, HECTOR WILLIAM GAVIN, 77, Lambeth Palace-road, S.E.
1870 MACKENZIE, JOHN T., Bombay, India.
1864 MACKENZIE, Sir MORELL, M.D., 19, Harley-street, W.
1878 MACKENZIE, STEPHEN, M.D., 18, Cavendish-square, W. (C. 1890.)
1879 MACLAGAN, THOMAS JOHN, M.D., 9, Cadogan-place, S.W.
1865 MACLAURIN, HENRY NORMAND, M.D., 187, Macquarie-street, Sydney, New South Wales.
1879 MACMAHON, JAMES THOMAS, 146, Wandsworth-road, S.W.
1876 MACNAMARA, CHARLES, 13, Grosvenor-street, W.
1879 MACREADY, JONATHAN FORSTER, 51, Queen Anne-street, W.
1885 MAGUIRE, ROBERT, M.D., 4, Seymour-street, W.
1877 MAKINS, GEORGE HENRY, 2, Queen-street, May Fair, W. (C. 1889-91.)
1887 MALCOLM, JOHN DAVID, M.B., C.M., 24, Bryanston-street, W.
1890 MANSON, PATRICK, M.D., C.M., 21, Queen Anne-street, W.
1876 MAPLES, REGINALD, Kingsclere, near Newbury.
1868 MARSH, F. HOWARD, 30, Bruton-street, W. (C. 1876-7.) (V.-P. 1889-90.)
1887 MARTIN, SIDNEY, M.D., B.S., 10, Mansfield-street, W.
1889 MASON, DAVID JAMES, M.D., Rosemont, Maidenhead.

Digitized by Google

Elected

1867 MASON, PHILIP BROOKES, Burton-on-Trent.
1884 MAUDSLEY, HENRY CARR, M.D., 11, Spring-street, Melbourne, Victoria.
L1852 MAY, GEORGE, jun., M.B., Reading.
1888 MAY, WILLIAM PAGE, M.D., B.Sc., National Hospital, Queen-square, W.C.
1881 MAYLARD, ALFRED ERNEST, M.B., 4, Berkeley-terrace, Glasgow.
1874 MEREDITH, WILLIAM APPLETON, M.B., 6, Queen Anne-street, W.
1859 MESSER, JOHN COCKBURN, M.D., Assistant Surgeon R.N.
1866 MICKLEY, GEORGE, M.A., M.B., St. Luke's Hospital, Old-street, E.C.
1877 MILNER, EDWARD, 32, New Cavendish-street, W.
1882 MONEY, ANGEL, M.D., 24, Harley-street, W.
1879 MOORE, NORMAN, M.D., 94, Gloucester-place, Portman-square, W. (C. 1885-7.)
1881 MOORE, THOMAS, 6, Lee-terrace, Blackheath, S.E.
1875 MORGAN, JOHN H., 68, Grosvenor-street, W. (C. 1886-8.)
1874 MORISON, ALEXANDER, M.D., C.M., Dunnottar, 115, Green-lanes, N.
1880 MORISON, BASIL GORDON, M.B., C.M., 70, Marquess-road, N.
1869 MORRIS, HENRY, M.A., M.B., 8, Cavendish-square, W. (C. 1877-9, 1884-6. S. 1881-3. V.-P. 1888-9.)
1879 MORRIS, MALCOLM ALEXANDER, 8, Harley-street, W.
1875 MORTON, JOHN, M.B., Guildford.
1884 MOTT, FREDERICK WALKER, M.D., 84, Wimpole-street, W. (C. 1891.)
1879 MOULLIN, CHARLES W. MANSELL, M.D., 69, Wimpole-street, W.
1878 MUMFORD, WILLIAM LUGAR, M.D., 12, Suffolk-street, Pall Mall, S.W.
1876 MUNRO, WILLIAM, M.D., C.M., Clarkefield, Fountain-street, Cheetham Hill, Manchester.
1885 MURRAY, HUBERT MONTAGUE, M.D., 27, Savile-row, W.
1864 MYERS, ARTHUR B. R., 43, Gloucester-street, Warwick-square, S.W. (C. 1872-3.)
1882 MYERS, A. T., M.D., 9, Lower Berkeley-street, W.
1887 MYERS, W. H., Fort Wayne, Indiana, U.S.A.

1887 NASON, EDWARD NOEL, M.B., 80, Abbey-street, Nuneaton.
1873 NETTLESHIP, EDWARD, 5, Wimpole-street, W. (C. 1882-4.)
1875 NEWBY, CHARLES HENRY, 15, Landport-terrace, Southsea, Hants.
1865 NEWMAN, WILLIAM, M.D., Stamford, Lincolnshire.
1868 NICHOLLS, JAMES, M.D., Trenarren, Newquay, Cornwall.
1876 NICHOLSON, JOHN FRANCIS, M.D., 29, Albion-street, Hull.
1878 NOOTT, WILLIAM MATHIAS, 8, Kensington-park-road, W.
L1864 NORTON, ARTHUR T., 101, Harley-street, W. (C. 1877-9.)
1883 NORVILL, FREDERIC HARVEY, M.B., Summerland, Yeovil, Somersetshire.
1856 NUNN, THOMAS WILLIAM, 8, Stratford-place, W. (C. 1864-6. V.-P. 1878-80.)
1871 NUNNELEY, Rev. FREDERICK BARHAM, M.D.

1880 O'CONNOR, BERNARD, M.D., Greenhill-park, Harlesden, N.W.

Digitized by Google

Elected

1873 O'Farrell, George Plunkett, M.B., 19, Fitzwilliam-square, Dublin.
1880 Ogilvie, George, M.B., 22, Welbeck-street, W.
1880 Ogilvie, Leslie, M.B., 46, Welbeck-street, W.
1850 Ogle, John W., M.D., 30, Cavendish-sq., W. (C. 1855-6. S. 1857-60. C. 1861-3. V.-P. 1865-8.)
1876 Oliver, John Ferens, M.D., 12, Old Elvet, Durham.
1888 Openshaw, Thomas Horrocks, M.B., B.S., 16, Wimpole-street, W.
1860 Orange, William, M.D., 35, Cromwell-road, Brighton.
1875 Ord, William Miller, M.D., 37, Upper Brook-street, W. (C. 1880-2.)
1879 Ormerod, J. A., M.D., 25, Upper Wimpole-street, W. (C. 1887-9.)
1881 Owen, Isambard, M.D., 40, Curzon-street, W.
1865 Owles, James Allden, M.D., Hill View, Woking, Surrey.

1875 Page, Herbert William, M.A., M.C. Cantab., 146, Harley-street, W. (C. 1889-91.)
1870 Paget, Sir James, Bart., D.C.L., LL.D., F.R.S., 1, Harewood-place, W. (P. 1887-8.)
1884 Paget, Stephen, 57, Wimpole-street, W.
1872 Parker, Robert William, 8, Old Cavendish-street, W. (C. 1881-3.)
1874 Parker, Rushton, M.B., B.S., 59, Rodney-street, Liverpool.
L1853 Parkinson, George, 50, Brook-street, W.
1882 Pasteur, William, M.D., 4, Chandos-street, W.
1885 Paul, Frank Thomas, 44, Rodney-street, Liverpool.
1865 Pavy, Frederick William, M.D., F.R.S., 35, Grosvenor-street, W. (C. 1872-4. V.-P. 1891.)
1868 Payne, Joseph Frank, M.D., 78, Wimpole-street, W. (C. 1873-5, 1883-5. S. 1880-2. V.-P. 1888-9.)
1872 Pearce, Joseph Chaning, M.D., C.M., Montague House, St. Lawrence-on-Sea, Kent.
1863 Pearson, David R., M.D., 23, Upper Phillimore-place, W.
1884 Pedley, F. Newland, 32, Devonshire-place, Portland-place, W.
1879 Peel, Robert, 130, Collins-street East, Melbourne, Victoria.
1889 Penberthy, John, Royal Veterinary College, Camden Town, N.W.
1887 Penrose, Francis George, M.D., 4, Harley-street, W.
1884 Pepper, Augustus Joseph, M.B., C.M., 13, Wimpole-street, W.
1888 Perry, Edwin Cooper, M.B., The College, Guy's Hospital, S.E.
1878 Philipps, Sutherland Rees, M.D., St. Ann's-heath, Virginia Water, Chertsey.
1871 Phillips, Charles Douglas F., M.D., 10, Henrietta-street, W.
1878 Phillips, John Walter, 30, Stanley-street, West Melbourne, Victoria.
1863 Pick, Thomas Pickering, 18, Portman-street, W. (C. 1870-1. V.-P. 1885-7.)
1867 Pitt, Edward G., M.D.
1884 Pitt, George Newton, M.D., 24, St. Thomas's-street, S.E. (C. 1890-1.)
1876 Pitts, Bernard, M.A., M.B., 31, Harley-street, W. (C. 1888-90.)

Digitized by Google

Elected

1887 PITTS, ROBERT ZACCHEUS, Springfield, Chelmsford.
1886 POCOCK, WALTER, 374, Brixton-road, S.W.
1883 POLAND, JOHN, 4, St. Thomas's-street, Southwark, S.E.
1882 POLLARD, BILTON, 24, Harley-street, W.
L1846 POLLOCK, GEORGE D. (TRUSTEE), 36, Grosvenor-street, W. (S. 1850-3. C. 1854-6. V.-P. 1863-5. P. 1875-6.)
1850 POLLOCK, JAMES EDWARD, M.D., 52, Upper Brook-street, W. (C. 1862-4. V.-P. 1879-81.)
1870 POORE, GEORGE VIVIAN, M.D., 30, Wimpole-street, W. (C. 1883-5.)
1876 PORT, HEINRICH, M.D., 48, Finsbury-square, E.C.
L1879 POTTER, HENRY PERCY, St. Mary Abbotts' Infirmary, Marloes-road, Kensington, W.
1866 POWELL, RICHARD DOUGLAS, M.D., 62, Wimpole-street, W. (C. 1873-5, 1881-3. S. 1877-9. V.-P. 1887-8.)
1884 POWER, D'ARCY, M.A., M.B., 26, Bloomsbury-square, W.C. (C. 1891.)
1865 POWER, HENRY, 37A, Great Cumberland-place, W. (C. 1876-7.)
1887 PRATT, WILLIAM SUTTON, Weedon, Northamptonshire.
1884 PRICE, J. A. P., M.D., 41, Castle-street, Reading.
1888 PRIESTLEY, R. C., M.B., 81, Linden-gardens, W.
L1856 PRIESTLEY, WILLIAM OVEREND, M.D., 17, Hertford-street, W.
1888 PRIMROSE, ALEXANDER, M.B., C.M. 196, Simcoe-street, Toronto, Canada.
1882 PRINGLE, J. J., M.B., 23, Lower Seymour-street, W.
L1848 PURNELL, JOHN JAMES, Woodlands, Streatham-hill, S.W. (C. 1858-61.)
1865 PYE-SMITH, PHILIP HENRY, M.D., F.R.S., 54, Harley-street, W. (C. 1874-7. V.-P. 1890-1.)

LO.M. QUAIN, Sir RICHARD, Bart., M.D., LL.D., F.R.S. (TRUSTEE), 67, Harley-street, W. (C. 1846-51. S. 1852-6. T. 1857-68. *Pres.* 1869-70. V.-P. 1871-3.)

1884 RAKE, BEAVEN NEAVE, M.D., Leper Asylum, Trinidad.
1872 RALFE, CHARLES HENRY, M.D., M.A., 26, Queen Anne-street, W. (C. 1877-9.)
1857 RAMSKILL, J. SPENCE, M.D., 5, St. Helen's-place, Bishopsgate-street, E.C.
L1848 RANDALL, JOHN, M.D., 204, Adelaide-road, N.W. (C. 1864-6.)
1857 RANKE, HENRY, M.D., Munich.
‡1890 RANSOM, WILLIAM BRAMWELL, M.D., The Pavement, Nottingham.
1865 RASCH, ADOLPHUS A., M.D., 7, South-street, Finsbury-square, E.C.
1891 RATCLIFFE, JOSEPH RILEY, M.B., The General Hospital, Birmingham.
1887 RAVEN, THOMAS FRANCIS, Broadstairs, Kent.
1870 RAY, EDWARD REYNOLDS, Dulwich Village, S.E.
L1858 REED, FREDERICK GEORGE, M.D., 46, Hertford-street, W.
1875 REID, ROBERT WILLIAM, M.D., C.M., University of Aberdeen.
1881 RENNER, WILLIAM, M.R.C.S., Wilberforce-street, Free Town, Sierra Leone.

Digitized by Google

Elected

1854 Reynolds, J. Russell, M.D., F.R.S., 38, Grosvenor-street, W. (C. 1868-9.)

1871 Richards, J. Peeke, London County Asylum, Hanwell, W.

1866 Rivington, Walter, M.S., 95, Wimpole-street, W.

‡1865 Roberts, David Lloyd, M.D., 11, St. John's-street, Manchester.

1871 Roberts, Frederick Thomas, M.D., 102, Harley-street, W. (C. 1883-5.)

1878 Roberts, William Howland, M.D., Surgeon, Madras Army.

1888 Robertson, Robert, M.D., The Bungalow, Ventnor, Isle of Wight.

1885 Robinson, Arthur Henry, M.D., Mile End Infirmary, Bancroft-road, N.E.

1887 Robinson, Henry Betham, M.B., 59, Lambeth Palace-road, S.E.

1882 Robinson, Tom, M.D., 9, Princes-street, Cavendish-Square, W.

1888 Rolleston, H. D., M.B., B.C., 13, Upper Wimpole-street, W.

1858 Rose, Henry Cooper, M.D., Penrose House, Hampstead, N.W. (C. 1873-4.)

1876 Rose, William, M.B., B.S., 17, Harley-st., W.

1879 Ross, James, M.D., C.M., 335, Oxford-street, Manchester.

1875 Rossiter, George Frederick, Cairo Lodge, Weston-super-Mare.

1877 Roth, Bernard, 29, Queen Anne-street.

1888 Roughton, Edmund Wilkinson, 33, Westbourne-terrace, W.

1858 Rouse, James, 2, Wilton-street, S.W.

1887 Roy, Charles Stuart, M.D., Cambridge.

1891 Russell, William, M.D., 46, Albany-street, Edinburgh.

1869 Rutherford, William, M.D., F.R.S., 14, Douglas-crescent, Edinburgh.

1882 Sainsbury, Harrington, M.D., 63, Welbeck-street, W.

1853 Salter, S. James A., M.B., F.R.S., Basingfield, near Basingstoke, Hants. (C. 1861-3. V.-P. 1880-2.)

1854 Sanderson, John Burdon, M.D., D.C.L.Durham, F.R.S., 50, Banbury-road, Oxford. (C. 1864-7. V.-P. 1873-4.)

1875 Sangster, Charles, 148, Lambeth-road, S.E.

1877 Sankey, H. R. O., M.B., Boreatton Park, Baschurch, Salop.

1886 Saundby, Robert, M.D., 83a, Edmund-street, Birmingham.

1871 Saunders, Charles Edward, M.D., Sussex County Lunatic Asylum, Hayward's Heath.

1890 Saunders, Frederick William, M.B., B.C., 17, Barkston-gardens, South Kensington, S.W.

1873 Savage, George Henry, M.D., 3, Henrietta-street, Cavendish-square, W. (C. 1881-3.)

1882 Savill, Thomas Dixon, M.D., Paddington Infirmary, 285, Harrow-road, W.

1877 Semon, Felix, M.D., 39, Wimpole-street, W. (C. 1885-7.)

1872 Sergeant, Edward, Town Hall, Bolton, Lancashire.

1876 Sharkey, Seymour J., M.D., 2, Portland-place, W. (C. 1884-6.)

1880 Shattock, Samuel G. (Hon. Secretary), 4, Crescent-road, The Downs, Wimbledon. (C. 1885-7. S. 1890-1.)

Digitized by Google

Elected

1885 Shaw, Lauriston Elgie, M.D., 10, St. Thomas's-street, S.E.

1884 Sheild, Arthur Marmaduke, M.B., B.S., 20, Stratford-place, Oxford-street, W.

1886 Sherrington, C. S., M.B., 27, St. George's-square, S.W.

L1856 Shillitoe, Buxton, 2, Frederick's-place, E.C.

L1855 Sibley, Septimus W., 7, Harley-street, W. (C. 1863-5. V.-P. 1879-81.)

1887 Sibley, Walter Knowsley, 7, Harley-street, W.

‡1875 Siddall, Joseph Bower, M.D., C.M., Condybeare, Northam, Bideford.

1880 Silcock, A. Quarry, M.D., B.S., 52, Harley-street, W. (C. 1888-90.)

1866 Sims, Francis Manley Boldero, 12, Hertford-street, W.

1887 Smallpeice, William Donald, 42, Queen Anne's-gate, S.W.

‡1875 Smee, Alfred Hutchinson, The Grange, Hackbridge, Carshalton, Surrey.

1879 Smith, E. Noble, 24, Queen Anne-street, W.

1887 Smith, Frederick John, M.B., 4, Christopher-street, Finsbury-square, E.C.

1875 Smith, George John Malcolm, M.B., Hurstpierpoint, Sussex.

1872 Smith, Gilbart, M.D., 68, Harley-street, W.

1878 Smith, Herbert Urmson, M.B., Cape Colony.

1873 Smith, Richard T., M.D., 53, Haverstock-hill, N.W.

1883 Smith, Robert Percy, M.D., Bethlem Royal Hospital, St George's Road, S.E.

1869 Smith, Robert Shingleton, M.D., Deepholm, Clifton Park, Bristol.

1856 Smith, Thomas, 5, Stratford-place, W. (C. 1867-9. V.-P. 1877-8.)

1866 Smith, William, Melbourne, Australia.

1870 Smith, William Johnson, Seamen's Hospital, Greenwich, S.E. (C. 1879-81.)

L1869 Smith, William Wilberforce, M.D., 14, Stratford-place, W.

1870 Snow, William Vicary, M.D., Richmond Gardens, Bournemouth.

1888 Solly, Ernest, M.B., Royal Free Hospital, Gray's Inn-road, W.C.

1868 Southey, Reginald, M.D., 32, Grosvenor-road, Pimlico. (C. 1882-4.)

1887 Spencer, Walter George, M.B., 35, Brook-street, W.

1888 Spicer, Robert Henry Scanes, M.D., 28, Welbeck-street, W.

1861 Squire, Alexander Balmanno, M.B., 24, Weymouth-street, W.

1885 Squire, John Edward, M.D., 53, Harley-street, W.

1890 Stabb, Ewen Carthew, St. Thomas's Hospital, Albert-embankment, S.E.

1889 Stewart, Edward, M.D., 8, Upper Wimpole-street, W.

L1854 Stewart, William Edward, 16, Harley-street, W.

1891 Stiles, Harold Jalland, M.B., C.M., 5, Castle-terrace, Edinburgh.

1879 Stirling, Edward Charles, Adelaide, South Australia [care of Messrs. Elder & Co., 7, St. Helen's Place, E.C.].

1883 Stoker, George, 14, Hertford-street, W.

1881 Stokes, Henry Fraser, 2, Highbury-crescent, N.

1884 Stonham, Charles, 4, Harley-street, W.

Digitized by Google

Elected

1875 Sturge, W. A., M.D., 29, Boulevard Dubouchage, Nice.
L1871 Sutherland, Henry, M.D., 6, Richmond-terrace, Whitehall, S.W.
1882 Sutton, John Bland, 48, Queen Anne-street, W. (C. 1887-90.)
‡1867 Swain, William Paul, 17, The Crescent, Plymouth.
1881 Symonds, Charters James, M.S., 26, Weymouth-street, Portland-place, W. (C. 1886-8.)

1870 Tait, Robert Lawson, 7, The Crescent, Birmingham.
1886 Targett, James Henry, M.B., M.S., 10, St. Thomas's-street, S.E.
1891 Tate, Walter William Hunt, University College Hospital, W.C.
1864 Tatham, John, 12, George-street, Hanover-square, W.
1870 Tay, Warren, 4, Finsbury-square, E.C. (C. 1881-2.)
1871 Taylor, Frederick, M.D., 20, Wimpole-street, W. (C. 1879-81.)
1885 Taylor, Henry H., 10, Brunswick-place, Brighton.
1880 Taylor, Seymour, M.D., M.C., 16, Seymour-street, W.
1879 Thin, George, M.D., 22, Queen Anne-street, W. (C. 1889-90.)
1870 Thomas, John Davies, M.D., 52, North-terrace, Adelaide, South Australia [care of Mr. H. K. Lewis, Gower-street].
L1852 Thompson, Sir Henry, Knt., 35, Wimpole-street, W. (S. 1859-63. C. 1865-7. V.-P. 1868-70.)
1891 Thomson, Henry Alexis, M.D., 2, Coates-crescent, Edinburgh.
1884 Thomson, John, M.B., C.M., 18, Walker-street, Edinburgh.
1874 Thornton, John Knowsley, M.B., 22, Portman-street, W.
1872 Thornton, William Pugin, 35, St. George's-road, Canterbury.
1865 Thorowgood, J. C., M.D., 61, Welbeck-street, W. (C. 1876-8.)
1880 Tirard, Nestor Isidore, M.D., 28, Weymouth-street, W.
1884 Tivy, William James, 8, Lansdowne-place, Clifton, Bristol.
1856 Tomes, Sir John, F.R.S., Upwood Gorse, Caterham, Surrey. (C. 1867-9.
1882 Tooth, H. H., M.D., 34, Harley-street, W.
1886 Totsuka, Kankai.
L1872 Townsend, Thomas Sutton, 68, Queen's Gate, S.W.
1888 Trevelyan, E. F., M.D., Seamen's Hospital, Greenwich, S.E.
1881 Treves, Frederick, 6, Wimpole-street, W. (C. 1887-90.)
1851 Trotter, John W., Bossall Vicarage, York. (C. 1865-9.)
1859 Truman, Edwin Thomas, 23, Old Burlington-street, W.
1888 Tubby, Alfred Herbert, M.B., 39, Finsbury-circus, E.C.
1867 Tuckwell, Henry Matthews, M.D., 64, High-street, Oxford.
1858 Tudor, John, Dorchester, Dorset.
L1875 Turner, Francis Charlewood (Hon. Secretary), M.D., 15, Finsbury-square, E.C. (C. 1884-6. S. 1891.)
1882 Turner, George Robertson, 49, Green-street, W.
1863 Turner, James Smith, 12, George-street, Hanover-square, W.
1890 Turner, William Aldren, M.B., 13, Queen Anne-street, W.
1858 Turtle, Frederick, Clifton Lodge, Woodford, Essex.
1880 Tyson, William Joseph, M.D., 10, Langhorne-gardens, Folkestone.

Digitized by Google

Elected

L1854 VASEY, CHARLES, 112, Cambridge-gardens, Notting-hill, W.
1867 VENNING, EDGCOMBE, 30, Cadogan-place, S.W.
1889 VOELCKER, ARTHUR FRANCIS, M.D., B.S., 13, Welbeck-street, W.

L1867 WAGSTAFFE, WILLIAM WARWICK, B.A., Purleigh, St. John's-hill, Sevenoaks. (C. 1874, 1878-80. S. 1875-7.)
LO.M. WAITE, CHARLES D., M.D., 3, Old Burlington-street, W.
1885 WAKLEY, THOMAS, jun., 5, Queen's-gate, S.W.
1881 WALLER, BRYAN CHARLES, M.D., Masongill House, Cowan-bridge, Kirkby-Lonsdale.
1890 WALLIS, FREDERICK CHARLES, M.B., M.S., 18, St. James's-street, S.W.
1888 WALSHAM, HUGH, M.A., M.B., B.C., St. Bartholomew's Hospital, E.C.
1873 WALSHAM, WILLIAM JOHNSON, M.B., C.M., 27, Weymouth-street, W. (C. 1881-3.)
1859 WALTERS, JOHN, M.B., Reigate, Surrey.
1889 WASHBOURN, JOHN WYCHENFORD, M.D., Guy's Hospital, S.E.
1877 WATERHOUSE, CHARLES, M.B., M.C., Carl Ludwigstrasse, Währing, Vienna.
1891 WATERHOUSE, HERBERT FURNIVALL, M.D., C.M., 34, Bernard-street, W.C.
1880 DE WATTEVILLE, ARMAND, M.A., M.B., 30, Welbeck-street, W.
1890 WEBB, CHARLES FREEE, M.D., New-street House, Basingstoke.
L1858 WEBER, HERMANN, M.D., 10, Grosvenor-street, W. (C. 1867-70. V.-P. 1878-80.)
1876 WEIR, ARCHIBALD, M.D., St. Mungho's, Great Malvern.
1864 WELCH, THOMAS DAVIES, M.D., Fairmount, Frith-hill, Godalming, Surrey.
1853 WELLS, Sir THOMAS SPENCER, Bart., 3, Upper Grosvenor-street, W. (C. 1865-8. V.-P. 1876-7.)
L1851 WEST, CHARLES, M.D., Kenilworth, Eaton-road, West Brighton. (C. 1856-7.)
1877 WEST, SAMUEL, M.D., 15, Wimpole-street, W. (C.1884-6, 1891. S. 1889-90.)
1888 WETHERED, FRANK J., M.D., 34, Queen Anne-street, W.
1891 WHEATON, SAMUEL WALTON, M.D., 52, The Chase, Clapham Common, S.W.
1867 WHIPHAM, THOMAS TILLYER, M.B., 11, Grosvenor-street, W. (C. 1880-2.)
1869 WHIPPLE, JOHN H. C., M.D., Army Medical Staff.
1877 WHITE, CHARLES HAYDON, 20, Shakespeare-street, Nottingham.
1891 WHITE, GILBERT B. MOWER, M.B., B.S., 39, Torrington-square, W.C.
1881 WHITE, WILLIAM HALE, M.D., 65, Harley-street, W. (C. 1888-90.)
1886 WHITE, WILLIAM HENRY, M.D., 43, Weymouth-street, W.
‡1868 WHITEHEAD, WALTER, 24, St. Ann's-square, Manchester.
1877 WHITMORE, WILLIAM TICKLE, 7, Arlington-street, S.W.
1870 WICKSTEED, FRANCIS WILLIAM, Chester House, Weston-super-Mare.

Digitized by Google

Elected

1869 WILKIN, JOHN F., M.D., M.C., New Beckenham, Kent.

1871 WILKINSON, J. SEBASTIAN, New Zealand.

L1855 WILKS, SAMUEL, M.D., F.R.S. (TRUSTEE), 72, Grosvenor-street, W. (C. 1857-60. V.-P. 1869-72, 1883-5. P. 1881-2.)

1879 WILLCOCKS, FREDERICK, M.D., 14, Mandeville-place, W.

1886 WILLETT, EDGAR WILLIAM, M.B., 25, Welbeck-street, W.

1869 WILLIAMS, ALBERT, M.D. (Travelling).

‡1858 WILLIAMS, CHARLES, 48, Prince of Wales-road, Norwich.

1866 WILLIAMS, CHARLES THEODORE, M.D., 2, Upper Brook-street, W. (C. 1875-8.)

1881 WILLIAMS, DAWSON, M.D., B.S., 25, Old Burlington-street, W.

1872 WILLIAMS, JOHN, M.D., 11, Queen Anne-street, W. (C. 1878-80.)

1864 WILLIAMS, W. RHYS, M.D., Linden House, Bertie-road, Leamington.

1881 WILLIAMS, W. ROGER, 28, Winckley-square, Preston.

1876 WILLIAMSON, JAMES MANN, M.D., Ventnor, Isle of Wight.

1863 WILLIS, FRANCIS, M.D., The Spa, Braceborough, Stamford.

1889 WILSON, ALBERT, Leytonstone, Essex.

1888 WILSON, CLAUDE, M.D., C.M., 6, York-road, Tunbridge Wells.

1859 WILSON, EDWARD THOMAS, M.B., Montpelier-terrace, Cheltenham.

1859 WILSON, ROBERT JAMES, 7, Warrior-square, St. Leonards-on-Sea.

‡1861 WINDSOR, THOMAS, Medical Library, Boston, Mass., U.S. [care of B. F. Stevens, 4, Trafalgar-square, W.].

1889 WINGRAVE, V. HAROLD WYATT, 7, Taviton-street, Gordon-square, W.C.

1874 WISEMAN, JOHN GREAVES, Dearden-street, Ossett, Yorkshire.

1865 WITHERBY, WILLIAM H., M.D., Pitt-place, Coombe, Croydon.

L1850 WOOD, JOHN, F.R.S., 61, Wimpole-street, W. (C. 1857-9. V.-P. 1872-4. T. 1884-7.)

1887 WOOD, T. OUTTERSON, M.D., 40, Margaret-street, W.

1854 WOOD, WILLIAM, M.D., 99, Harley-street, W.

1876 WOOD, WILLIAM EDWARD RAMSDEN, M.A., M.D., The Priory, Roehampton, S.W.

1883 WOODCOCK, JOHN ROSTRON, 155, Hagley-road, Birmingham.

1883 WOODHEAD, GERMAN SIMS, M.D., Examination Hall, Victoria-embankment, London, W.C. (C. 1891.)

1879 WOODWARD, G. P. M., M.D., Deputy Surgeon-General; Sydney, New South Wales.

1884 WORTS, EDWIN, 6, Trinity Street, Colchester.

1869 WYMAN, WILLIAM S., M.D., Red Brae, 18, Putney-hill, S.W.

1890 WYNNE, EDWARD T., M.B., 14, Argyll-road, Kensington, W.

1884 WYNTER, WALTER ESSEX, 30, Upper Berkeley-street, W.

1872 YOUNG, HENRY, M.B., Monte Video, South America.

Digitized by Google

Digitized by Google

ANNUAL REPORT OF COUNCIL, 1890-91.

PRESENTED AT THE ANNUAL MEETING, MAY 19TH, 1891.

THE Council is glad to report that the Society is flourishing. The roll of members has been increased by fifteen, thirty-one new members having been elected, seven have resigned, and nine have been removed by death, viz. Sir William Gull, Dr. Matthews Duncan, Mr. Marshall, Mr. Arthur Adams, Mr. Bellamy, Dr. Fincham, Dr. Gulliver, Dr. Humby, and Dr. Way.

Several important changes have been introduced since the Council made its last report to the Society in January, 1890.

1. The arrangement of the secretarial duties has been altered. The term of office will, for the future, be two years instead of three. Every year a new Secretary will be appointed, a surgeon and a physician in turn. The last appointed officer, called the Junior Secretary, will manage the business of the ordinary meetings and edit the volume; the Senior Secretary being responsible for the Council meetings, as well as for the financial and other general business of the Society. By this means the surgeons have been enabled to take their proper share in the actual working of the meetings, and the experience of the past session fully proves the wisdom of the change.

2. The date of the General Meeting has been altered from January to May, *i. e.* from the middle to the end of the session. The election and change of officers in the middle of session was found to be very inconvenient in working. One of the incidental

Digitized by Google

disadvantages of the old system was the fact that the list of officers in the current volume was never correct; and a further inconvenience was that the balance-sheet, being made up to the 30th of December, contained the accounts of parts of two sessions. Under the new arrangement each session will be complete in itself, the officers will begin and end their work with the session, and the balance-sheet will show the actual expenses of each working year. In order to provide for the business of the Society in the interval between the General Meeting in May and the commencement of the session in October, it is arranged that the old officers shall not hand over their duties to the new until the first meeting of the Society in October, when the new President will open the proceedings with a short address.

These changes introduce, of course, complication into the accounts of the present year, which have to deal with the greater part of two sessions; but next year, when the difficulties of transition are past, the accounts will gain greatly in simplicity and clearness.

3. The last change is, in some respects, the most important of all, as touching the fundamental constitution of the Society. By the original first rule or fundamental law the scope of the Society's work was, in the opinion of your Council, unduly limited, for it seemed to exclude by its wording the communication to the Society of researches which, though not anatomical, were still pathological in the widest and highest sense. It was wisely felt that in the 'Transactions' of the Society should be found as complete a record as possible of all work bearing upon the essence and nature of disease and its results. The Council believe that the altered wording of the rule will have the effect intended.

In consequence of the changes referred to, the Bye-Laws have required complete revision. They are at present in the press, and will be circulated among the members shortly.

The balance-sheet shows on this occasion the accounts of a session and a half, and cannot therefore be compared with those of previous years. The increased expenditure has been partly met by increased receipts from subscriptions. The volume of 'Transactions,' though not so bulky as some of its predecessors, will be found fully equal to them in the quality of its contents. Its expenses have been heavy, chiefly owing to the excellence and costliness of many of the illustrations. Still the need of economy in these respects has not been overlooked by the Council. By

Digitized by Google

more business-like arrangements entered into with those concerned the cost of printing has been already greatly reduced, and it is intended next year to consider the possibility of effecting similar savings in the production of illlustrations. Partly with this object, and partly with the object of ensuring the best technical skill, the Council has appointed a Committee of Illustrations, whose special duty it will be to see that the most effective as well as the least expensive methods of reproducing the drawings and illustrations to be published are adopted. The Council believe that such a Committee will be of the greatest assistance to the Secretaries in their difficult and arduous work of editing the volume.

In October of the present year Professor Virchow will celebrate his 78th birthday. In 1869 the Society paid him the well-deserved honour of electing him an honorary member. The Council now recommend that the Society should take its proper part in the movement to his honour, and suggest that a congratulatory address should be drawn up, signed by the President and Council, and presented to Professor Virchow by the President in the name of the Society.

Signed, on behalf of the Council,

W. H. Dickinson, *President.*

May 5th, 1891.

Digitized by Google

THE PATHOLOGICAL SOCIETY OF LONDON,

Cr. *In Account with the Treasurer*, WILLIAM CAYLEY, ESQ., M.D., *43rd Session*, 1890–91. **Dr.**

From 1st January, 1890, *to 30th April*, 1891.

	£	s.	d.	£	s.	d.
By *Balance* in Treasurer's hands				101	6	9
Subscriptions:						
417 Annual at 21*s*.	437	17	0			
28 Admissions (Resident) at 21*s*.	29	8	0			
6 Ditto (Non-Resident)	11	11	0			
*12 Life Compositions	33	12	0			
				512	8	0
Sale of Transactions:						
By the Publisher (Smith, Elder)	49	6	10			
" Assist. Sec. (Cash) £15 4 6						
" " (Composition) 10 10 0						
	25	14	6			
				75	1	4
Dividends (6 quarters)				46	19	0
				£735	15	1

	£	s.	d.	£	s.	d.
To *Meetings:*						
Expenses of Rooms	105	0	0			
Refreshments	36	15	0			
R. Coldrey (Attendance)	7	10	0			
Microscopes	26	1	0			
				175	6	0
Transactions:						
Printing, Binding, Delivering of Vol. XLI	193	0	9			
Illustrations £237 8 8						
Less payment by a Member for own Illustrations 5 5 0						
	232	3	8			
				425	4	5
Secretariat and Treasury:						
Sundry Printing and Stationery	37	8	1			
Assist. Sec.	28	7	0			
Commission to Collector (on account)	15	15	0			
Bureau	15	15	0			
Petty Cash	2	10	0			
Cheques and Bank Charges	2	6	7			
				102	1	8
				702	12	1
Balance in hand (*April* 30*th*)				33	3	0
				£735	15	1

Audited and found correct, May 7th, 1891,

W. B. HADDEN, M.D., W. BRUCE CLARKE, M.B., } *Auditors.*

May 7th, 1891,

W. CAYLEY, M.D., *Treasurer.*

SAMUEL WEST, M.D., SAMUEL G. SHATTOCK, } *Hon. Secs.*

* By a law recently passed by the Society, the sum derived from Composition Fees, and now amounting to £138 12*s*., ought to have been invested. The finances have not, however, yet rendered this possible.

Digitized by Google

LIST OF SPECIMENS AND REPORTS

BROUGHT BEFORE THE SOCIETY DURING THE SESSION 1890–1.

I. DISEASES, ETC., OF THE NERVOUS SYSTEM.

PAGE

1. External hydrocephalus By S. W. Wheaton, M.D. 1
2. Extensive chronic gummatous pachymeningitis of five years' duration
   By G. Newton Pitt, M.D., for R. Cuff, M.D. 4
3. Thrombosis of cerebral veins By William Collier 12
4. Local atrophy of cerebral convolutions
   By J. A. Ormerod, M.D. 13
5. Heterotopia of the grey matter of the spinal cord
   By Howard H. Tooth, M.D. 14
6. Heterotopia of the grey matter of the spinal cord
   By C. M. Campbell, M.D., and William Aldren Turner, M.B., M.R.C.P. 20
7. A case of syringomyelus [With Plate I]
   By James Galloway, M.B. 26

II. DISEASES, ETC., OF THE ORGANS OF RESPIRATION.

1. Ulceration just below right vocal cord followed by subcutaneous emphysema
   By H. Montague Murray M.D. 35

Digitized by Google

PAGE

2. Extreme leprosy of larynx necessitating tracheotomy (Card specimen) By Bevan Rake, M.D. 37
3. Anomalous tumour of the larynx By Felix Semon, M.D., and Samuel G. Shattock 37
4. Fibroid polypus of the trachea By Leonard A. Bidwell 40
5. Complete rupture of right bronchus (Card specimen) By H. D. Rolleston 42
6. Case of plastic bronchitis By Samuel West, M.D. 43
7. Gangrene of lung secondary to bronchiectasis By G. Newton Pitt 46
8. Tuberculosis of the lung arising from tuberculosis of the bronchial glands By Arthur Francis Voelcker, M.D. 46
9. Necrosed pulmonary tissue and exudation becoming tubercular (Card specimen) By Sheridan Delépine 50
10. Gumma of lung By H. D. Rolleston 50
11. Diffuse syphilitic fibrosis of the lungs By E. C. Perry 53
12. Myxo-sarcoma of lung By H. D. Rolleston 54
13. (1) Primary carcinoma of lung. (2) Mediastinal glands from same case By E. Lycett Burd, M.D. 55
14. Tuberculosis of the pleura By E. C. Perry 55

III. DISEASES, ETC., OF THE ORGANS OF CIRCULATION.

1. Rupture of the heart and of the arch of the aorta. (1) One inch above the aortic valves. (2) At the junction of the transverse and descending parts of the arch By H. D. Rolleston 57
2. Simple atrophy of heart By G. Gulliver, M.B. 58
3. Tricuspid stenosis. Partial obstruction of right auriculo-ventricular opening by partly calcified and organised fibrinous vegetations. Localised fibrous thickening and calcification of endocardium of left auricle By Sheridan Delépine 59

Digitized by Google

PAGE

4. Aneurysmal dilatation of wall of left ventricle (Card specimen) By G. Gulliver, M.B. 60
5. Aneurysm of heart By J. A. Ormerod, M.D. 60
6. Gummatous infiltration of the muscular wall of the heart, leading to aneurysmal pouching and rupture By G. Newton Pitt, M.D. 61
7. Myocarditis limited to the right side of the heart By H. D. Rolleston, M.B., M.R.C.P. 63
8. Patent foramen ovale in an adult By W. B. Hadden 65
9. Communication between the ventricles of the heart—congenital (Card specimen) By H. D. Rolleston, M.B. 65
10. A heart with bifid apex (Card specimen) By Samuel G. Shattock 67
11. Aortic aneurysm communicating with superior vena cava By William Miller Ord, M.D. 71
12. Aneurysms above and involving the sinuses of Valsalva. Death from rupture of one into the pericardium (Card specimen) By Francis H. Hawkins, M.B. 74
13. Saccular aneurysm of aorta in a woman; rupture into left bronchus (Card specimen) By H. D. Rolleston, M.B. 76
14. Saccular aneurysm of descending aorta rupturing into left bronchus (Card specimen) By W. Lee Dickinson 77
15. Aneurysm of abdominal aorta compressing common bile-duct and rupturing into duodenum (Card specimen) By W. Lee Dickinson 77
16. Aneurysm of superior mesenteric artery; extravasation into mesentery; hæmorrhage into peritoneal cavity (Card specimen) By James Galloway, M.B. 78
17. Partial rupture of the right subclavian artery with extensive separation of the internal and middle coats By Anthony A. Bowlby 79

Digitized by Google

IV. DISEASES, ETC., OF THE ORGANS OF DIGESTION.

PAGE

1. On a case of pressure diverticulum of the œsophagus By THOMAS F. CHAVASSE 82
2. Caseous gland opening into the œsophagus By ARTHUR FRANCIS VOELCKER, M.D., M.R.C.P. 87
3. Malignant disease of the œsophagus communicating with trachea and aorta (Card specimen) By W. B. HADDEN 88
4. Epitheliomatous tumour occluding the œsophagus By LAURISTON SHAW, M.D. 89
5. Sarcoma of the œsophagus perforating the trachea By LAURISTON SHAW, M.D. 90
6. A tumour involving trachea and œsophagus in the neck By JOHN CAHILL 91
7. A case of chylous ascites and chylous hydrothorax, due to thrombosis and contraction of veins at the root of the neck on the left side By SIDNEY MARTIN, M.D. 93
8. A case of chylous ascites By FRED. J. SMITH, M.B., M.R.C.P. 100
9. Loose body in peritoneal cavity (Card specimen) By H. D. ROLLESTON, M.B. 103
10. Contraction of the stomach from chronic inflammation (Card specimen) By LAURISTON SHAW, M.D. 104
11. Extreme cicatrisation and contraction of the stomach, due to a corrosive poison taken three months previously By C. H. GOLDING-BIRD and G. NEWTON PITT, M.D. 105
12. A case of extreme contraction of the stomach By W. B. HADDEN, M.D. 107
13. Anthrax œdema of stomach (Card specimen) By G. NEWTON PITT, M.D. 108
14. Colon pigmented black throughout with lead [With Plate II] By G. NEWTON PITT, M.D. 109
15. Ulcerative colitis By SEYMOUR J. SHARKEY, M.D. 109
16. Ulcerative colitis (Card specimen) By H. BETHAM ROBINSON, M.B. 115
17. Psilosis or sprue By FRANK J. WETHERED, M.D., M.R.C.P. 116

Digitized by Google

PAGE

18. Chronic intestinal obstruction from stricture of the ileum, secondary to ulceration produced by strangulation of the bowel in a femoral hernia; death from perforation [With Plate III] By G. Newton Pitt, M.D. 119
19. Stricture of jejunum (Card specimen) By H. D. Rolleston, M.B. 122
20. Volvulus in a new-born infant; laparotomy By G. Newton Pitt, M.D. 123
21. Ileo-cæcal intussusception with involvement of the duodenum; passage of the cæcum and vermiform appendix from the right into the left iliac region (Card specimen) By Sheridan Delépine, M.B. 124
22. Perforation of small intestine caused by a collection of orange pips incarcerated in an inguinal hernia By Bernard Pitts, M.B. 125
23. Rupture of vermiform appendix By Arthur Voelcker, M.D. 127
24. Vermiform appendix in a case of general acute peritonitis By Arthur Voelcker, M.D. 128
25. A case of fæcal fistula at the umbilicus with non-development of sigmoid flexure and rectum By William Anderson, F.R.C.S. 128
26. Lipoma of spermatic cord with hernial sac By E. W. Roughton 130
27. Duodenal pouch (Card specimen) By H. D. Rolleston, M.B. 131
28. Obstruction at the ileo-cæcal valve caused by a carcinomatous tumour growing from the ileo-cæcal valve; remarks (Card specimen) By Francis H. Hawkins, M.B. 132
29. Intestine and liver from a case of ankylostomiasis (Card specimen) By Beaven Rake, M.D. 135
30. Papillomatous growth, containing the ova of the *Bilharzia hæmatobia*, removed from the rectum By Anthony A. Bowlby 136
31. Three cases of imperforate rectum By Stephen Paget, F.R.C.S. 136
32. Rupture of liver; partial repair (Card specimen) By H. D. Rolleston, M.B. 138

Digitized by Google

PAGE

33. Pylephlebitis suppurativa consequent on perityphlitis. No symptoms pointing to the liver. Parotid swelling a fortnight before death subsiding without suppuration By Samuel West, M.D. 138
34. Extensive gummatous lesions of the liver, diaphragm, lung, and spleen By Sheridan Delépine, M.B.Edin., B.Sc.Lausanne; and Richard Sisley, M.D.Lond. 141
35. Tumour in the portal fissure and liver leading to complete occlusion of the vena cava from the kidneys to the heart, with a similar tumour in the heart By Samuel West, M.D. 155
36. Lipoma of liver (? appendix epiploica) By H. D. Rolleston, M.B. 160
37. A case of primary melanotic sarcoma of the liver By Sheridan Delépine, M.B.Edin. 161
38. Pigmented growth of liver (apparently primary sarcoma) (Card specimen) By F. G. Penrose, M.D. 172
39. New growth in liver secondary to carcinoma of descending colon By Norman Moore, M.D. 172
40. Liver containing two hydatids, the sacs communicating but not the cysts; paracentesis three times, 90 oz.; free incision; death from exhaustion By Samuel West, M.D. 175
41. Gall-bladder with internal ulceration By Norman Moore, M.D. 178
42. Ulceration of gall-bladder By Sydney Jones, M.B. 179
43. Distension and commencing suppuration of the gall-bladder in association with typhoid fever (Card specimen) By W. Hale White, M.D. 181
44. Large gall-stone in ductus communis choledochus (Card specimen) By W. Joseph Tyson, M.D. 182
45. Duodenal pouching at the opening of the bile-duct, due to ulceration (Card specimen) By H. D. Rolleston, M.B. 183
46. Rupture of spleen By Edgar Willett, M.B. 183
47. Cirrhosis of pancreas in diabetes (microscopical) (Card specimen) By W. B. Hadden, M.D. 184

Digitized by Google

V. DISEASES, ETC., OF THE GENITO-URINARY ORGANS.

PAGE

1. Hydronephrosis of right kidney, removed by nephrectomy; aberrant renal artery (Card specimen) By ALBAN DORAN 185
2. Perinephritic abscess opening into the duodenum (Card specimen) By H. D. ROLLESTON, M.B. 186
3. Tumour of right kidney, weighing 4½ lbs.; hæmaturia; death By JOHN R. LUNN 186
4. A case of tubercular ulceration of the bladder, which was treated by means of a weak solution of tuberculin By E. HURRY FENWICK 189
5. Specimens of the *Distoma hæmatobium* (*Bilharzia hæmatobia*), with the urinary organs and lung containing ova By ANTHONY A. BOWLBY 194
6. Bladder affected with *Bilharzia hæmatobia* (Card specimen) By SAMUEL G. SHATTOCK 196
7. Hydatid cyst between bladder and rectum; retention of urine; surgical kidneys; death Reported by JOHN R. LUNN 198
8. Large hydatid cyst in the pelvis pressing upon the bladder and causing obstructive suppression of urine By E. HURRY FENWICK 201
9. Secondary melanotic sarcoma of the bladder By J. H. TARGETT 214
10. The soft parts and pelvis of a made adult who had extroversion of the bladder By EDGAR WILLETT 215
11. Vesical calculi (Card specimen) By RAYMOND JOHNSON 217
12. Myxo-sarcoma of prostate and bladder (Card specimen) By W. D. SPANTON (per J. H. TARGETT) 218
13. Prostatitis and periprostatic abscess; cystic dilatation of prostatic glands; numerous prostatic calculi (Card specimen) By SHERIDAN DELÉPINE 219
14. Cystic chondro-adenoma of testis (Card specimen) By H. BETHAM ROBINSON 220

Digitized by Google

PAGE

15. Cystic dilatation of the vasa deferentia (Card specimen) By J. H. Targett 221
16. Primary carcinoma of the right Fallopian tube with large cyst in connection with the new growth (Card specimen) By W. Essex Wynter, M.D. 222
17. Blood-cast of the uterus in a case of anæmia (Card specimen) By Sheridan Delépine 222
18. Case of supernumerary median nipple and areola in a male By W. Roger Williams 224
19. Cystic disease of breast in young women By H. Betham Robinson, M.S. 226
20. Duct carcinoma simulating scirrhus. [With Plate IV fig. 1.] By H. Betham Robinson 229

VI. DISEASES, ETC., OF THE ORGANS OF MOTION.

1. Fracture of first rib (Card specimen) By H. D. Rolleston, M.B. 232
2. Fracture of both first ribs (Card specimen) By H. D. Rolleston, M.B. 232
3. Fractures of the first rib (Card specimen) By H. D. Rolleston, M.B. 233
4. Extensive necrosis of the vertex (with drawing of the skull) (Card specimen) By H. D. Rolleston, M.B., for Dr. Dewsnap 234
5. Femora three years after osteotomy By James Berry, M.B., B.S. 234
6. Two specimens of extreme thickening of the calvaria in infants By Samuel G. Shattock 235
7. Symmetrical periostitis of femur, with an unusual formation of new bone By Anthony A. Bowlby 243
8. Osteitis deformans in a single bone By H. H. Clutton 246
9. Osteitis deformans By Joseph Griffiths 249
10. Acromegaly By H. D. Rolleston, M.B., for A. A. Kanthack, M.B. 251
11. Calvaria showing irregular absorption of bone from a case of congenital syphilis By J. F. Payne, M.D. 252

Digitized by Google

PAGE

12. Gummatous disease of occipital lobe due to inherited syphilis; perforation of skull
By J. HUTCHINSON, jun. 254
13. Caries of the scapula (Card specimen)
By L. A. DUNN, M.B. 257
14. Epiphysitis (so called) in infants
By WILLIAM HENRY BATTLE 258
15. Ossifying epulis of lower jaw (Card specimen)
By L. A. DUNN, M.B. 263
16. Central sarcoma of femur (Card specimen)
By W. H. BATTLE 264
17. Glandular carcinoma of upper jaw
By H. BETHAM ROBINSON 265
18. Columnar carcinoma of humerus secondary to tumour of upper part of rectum By BERNARD PITTS, M.A., M.C. 267
19. Charcot's disease of both knee-joints (Card specimen)
By J. H. TARGETT, M.B. 269
20. Patella with (dislocated internal semilunar?) cartilage fixed to it By H. D. ROLLESTON, M.B. 271
21. A piece of the patellar cartilage knocked off and forming a loose body in the knee-joint
By W. BRUCE CLARKE, M.B. 273
22. Two loose bodies removed from a knee-joint separately with an interval of four weeks
By EDGAR WILLETT, M.B. 274
23. Fifty loose bodies removed from a knee-joint
By JAMES BERRY, M.B., B.S. 275
24. Loose bodies from a tubercular knee-joint [With Plate V] By HOWARD MARSH 276
25. Genu recurvatum in a fœtus at term (Card specimen) [With Plate VI] By SAMUEL G. SHATTOCK 280

VII. DISEASES, ETC., OF THE ORGANS OF SPECIAL SENSE.

1. Malignant polypus of the nose
By ARTHUR E. BARKER, F.R.C.S. 293

Digitized by Google

PAGE
2. Nasal calculus (Card specimen) By RAYMOND JOHNSON 296
3. Osteoma of temporal bone By C. A. BALLANCE 296

VIII. DISEASES, ETC., OF THE DUCTLESS GLANDS.

1. Tuberculosis of the thyroid gland (Card specimen) By E. C. PERRY 298
2. Tuberculosis of the thyroid gland (Card specimen) By ARTHUR VOELCKER, M.D. 298
3. Exophthalmic goitre in a girl causing death by asphyxia By W. G. SPENCER 299
4. Substernal goitre arising in an accessory thyroid By BERNARD PITTS 301
5. Pigmented small intestines, adrenals, and semilunar ganglia, from a case of Addison's disease (Card specimen) By W. H. ALLCHIN, M.B. 302

IX. DISEASES, ETC., OF THE SKIN.

1. Rodent ulcer of scalp (Card specimen) By H. H. CLUTTON 304
2. Carcinoma of scalp By S. PAGET 306
3. Carcinoma following lupus of face (Card specimen) By JAMES BERRY 308
4. "On a supposed case of indigenous leprosy" [really carcinoma] By P. S. ABRAHAM, M.A., M.D., B.Sc., F.R.C.S.I. 309

X. MORBID GROWTHS.

1. Two cases of dermal cyst of finger By E. C. STABB 314
2. Sebaceous carcinoma of face [With Plate IV, fig. 2] By H. BETHAM ROBINSON 315

Digitized by Google

PAGE

3. Columnar-celled carcinoma involving the lower jaw
By H. BETHAM ROBINSON 317
4. Intra-cystic carcinoma of pectoral region. (Card specimen) By EDGAR WILLETT 319
5. Mediastinal carcinoma secondary to scirrhus of the pancreas (Card specimen) By H. D. ROLLESTON 320
6. Melanotic sarcoma, very widely disseminated
By JOHN CUMMING MACKENZIE, M.B., communicated by G. SIMS WOODHEAD, M.D. 321

XI. MISCELLANEOUS COMMUNICATIONS.

1. On the morphology, cultivation, and toxic products of the tubercle bacillus [With Plate VII, figs. 3 and 4]
By EDGAR M. CROOKSHANK, M.B. 330
2. Note on tubercular animals under treatment with tuberculin
By P. ABRAHAM, M.D., and E. CROOKSHANK, M.B. 343
3. Note on media for the cultivation of the bacillus of tubercle By Sir HUGH R. BEEVOR, communicated by PROFESSOR CROOKSHANK 344
4. Micro-organism of diphtheria with experimental results in animals By ALBERT WILSON, M.D., Leytonstone 346
5. Hæmatoporphyrin in the urine
By S. MONCKTON COPEMAN, M.A., M.D. 364
6. Cultivation of psorospermia (a preliminary communication) [With Plate VII, figs. 1 and 2; and Plate VIII]
By SHERIDAN DELÉPINE, M.B.Edin. 371
7. Inoculation experiments with psorospermia
By SAMUEL G. SHATTOCK and CHARLES A. BALLANCE 377
8. On the non-contagiousness of cancer
By WALTER K. SIBLEY, M.B.Cantab. 381
9. A case of leprosy, with remarks on the nature of the lesions found in the lungs
By SHERIDAN DELÉPINE, M.B.Edin., and CH. SLATER, M.B.Cantab. 386

Digitized by Google

PAGE

10. A case of melano-mycosis of the skin, with remarks, &c. [With Plates IX and X] By SHERIDAN DELÉPINE 423
11. Charcot's crystals in sputum containing a croupous cast (Card specimen) [With Plate XI] By SHERIDAN DELÉPINE, M.B., B.Sc. 458
12. Charcot's crystals in an alcoholic extract of a liver in a state of acute atrophy (yellow and red) (Card specimen) [With Plate XI] By SHERIDAN DELÉPINE, M.B., B.Sc. 458
13. Charcot's crystals in fæces (Card specimen) By SHERIDAN DELÉPINE, M.B., B.Sc. 459
14. Case of chronic general nodular tuberculosis, *i. e.* multiple tubercular tumours throughout the body, many in brain; no symptoms save indefinite one of tumour of the brain By SAMUEL WEST, M.D. 460
15. Tuberculosis of finger (tendon-sheath, &c.) By E. C. STABB 464
16. Symmetrical hemiatrophy of the gastrocnemii muscles (Card specimen) By J. H. TARGETT 465
17. Spina bifida associated with cystic horseshoe kidney (Card specimen) By RAYMOND JOHNSON 466
18. Cured spina bifida (Card specimen) By G. H. MAKINS 467
19. Webbed fingers and toes (Card specimen) By H. BETHAM ROBINSON 468
20. Hodgkin's disease, with lardaceous kidneys and an unusually large spleen (Card specimen) By W. HALE WHITE 468

XII. DISEASES, ETC., OF THE LOWER ANIMALS.

1. Bony plates in dura mater pressing on the spinal cord, and causing paraplegia in a dog (From the Brown Institution) (Card specimen) By W. G. SPENCER 470
2. Filariæ in a dog's heart (Card specimen) By E. C. PERRY 471

Digitized by Google

PAGE

3. Lympho-sarcoma surrounding the abdominal aorta, narrowing it near its termination, and completely obstructing the iliacs, in a dog (From the Brown Institution) (Card specimen) By W. G. Spencer 472
4. Sarcoma surrounding the trachea and the aorta in a dog (From the Brown Institution) (Card specimen) By W. G. Spencer 472
5. Rabbit's liver showing hypertrophic cirrhosis (Card specimen) By E. N. Nason, M.B. 473
6. Leucocythæmia splenica. Cat (From the Brown Institution) (Card specimen) By W. G. Spencer 473
7. Pyosalpinx. Distension of both uterine cornua with pus from a dog which had purulent vaginitis (From the Brown Institution) (Card specimen) By W. G. Spencer 474
8. Hæmatosalpinx and hæmatometra. Distension of the uterus and both cornua with menstrual fluid in an aged dog, due to obstruction by a cervical polypus (From the Brown Institution) (Card specimen) By W. G. Spencer 475
9. Eyes of an adult cat, showing the results of purulent keratitis and conjunctivitis (From the Brown Institution) (Card specimen) By W. G. Spencer 476
10. Cervical teeth. By J. Bland Sutton 477
11. A harlequin calf. By J. Bland Sutton 479

Digitized by Google

REPORTS OF THE COMMITTEE ON MORBID GROWTHS.

PAGE

1. On Dr. Shaw's Specimen of Sarcoma of the Œsophagus. [R. W. Parker and Samuel G. Shattock] 91
2. On Dr. Cahill's Specimen of Tumour of the Neck. [Charters J. Symonds and Anthony A. Bowlby] 92
3. On Dr. West's Specimens of Tumour in the Portal Fissure and Liver. [Seymour J. Sharkey and Frederick S. Eve] 159
4. On Mr. Lunn's Specimen of Tumour of the Kidney. [R. W. Parker and Samuel G. Shattock] 188
5. On Mr. Barker's Specimen of Malignant Polyp of the Nose. [A. A. Bowlby and C. J. Symonds] 295
6. On Mr. Stephen Paget's Crateriform Ulcer of the Scalp. [G. Newton Pitt and F. Charlewood Turner] 307

Digitized by Google

LIST OF PLATES.

		TO FACE PAGE
I.	Syringomyelus. (Dr. GALLOWAY.) (Page 26) .	28
II.	Deposit of Lead Sulphide in Cæcum. (Dr. NEWTON PITT.) (Page 109)	110
III.	Stricture of the Intestine. (Dr. NEWTON PITT.) (Page 119)	120
IV.	Fig. 1. Duct Carcinoma of Breast. (Mr. ROBINSON.) (Page 229) Fig. 2. Recurrent Carcinoma of Face. (Mr. ROBINSON.) (Page 315)	230
V.	Loose Bodies from a Tubercular Knee-joint.) (Mr. HOWARD MARSH.) (Page 276.) . .	278
VI.	Genu Recurvatum. (Mr. SHATTOCK.) (Page 280) .	282
VII.	Figs. 1, 2. Psorospermia. (Dr. DELÉPINE.) (Page 371) Figs. 3, 4. Bacillus Tuberculosis. (Prof. CROOKSHANK.) (Page 330)	336
VIII.	Psorospermosis. (Dr. DELÉPINE.) (Page 371) .	376
IX.	Melanomycosis. (Dr. DELÉPINE.) (Page 423) .	444
X.	Melanomycosis. (Dr. DELÉPINE.) (Page 423) .	446
XI.	Charcot's Crystals. (Dr. DELÉPINE.) (Page 458) .	458

Digitized by Google

LIST OF FIGURES IN THE TEXT.

PAGE

1. Ophthalmic diagrams 7
2. Brain in gummatous pachymeningitis . . 9
3, 4. Heterotopia of grey matter of spinal cord . 18, 24
5. Syringo-myelus 30
6. Heart with bifid apex 68
7. Rupture of inner and middle coats of subclavian artery 80
8. Diverticulum of the œsophagus . . . 83
9. Dissection of the veins at root of neck in a case of chylous ascites 97
10. Gumma of spleen 148
11. Gumma of liver 150
12. Hydatid cyst in pelvis 204
13. Blood cast of uterus 223
14. Microscopic section of calvaria in rickets . . 240
15. Periostitis of femur 244
16. Displaced semilunar cartilage . . . 272
17. Genu recurvatum 285
18. Osteoma of temporal bone . . . 296
19. Rodent ulcer 305
20. Spectrum of hæmatoporphyrin . . . 366
21. Psorospermia 376
22. Aspergillus niger 443
23. Eye of cat with purulent keratitis . . . 476
24, 25. Cervical tooth 478
26. Harlequin calf 480

Digitized by Google

REPORT.

SESSION 1890-1891.

I. DISEASES, ETC., OF THE NERVOUS SYSTEM.

1. *External hydrocephalus.*

By Dr. S. W. Wheaton.

For permission to use the notes of this case during the time that it was an in-patient at the Royal Hospital for Children and Women I am indebted to Dr. Sunderland. The patient was a child, aged 7 months, the mother was a German, and it was her first child, the father was an Englishman; both parents were healthy. The enlargement of the head was first noticed three months after birth. When admitted into the hospital the shape of the head and face was in no way different from an ordinary case of hydrocephalus, but what was particularly noticeable was the marked dilatation of the veins of the scalp and superficial redness all over it, fading on pressure. The anterior fontanelle was tense, and measured five inches in length by four inches in breadth, the greatest circumference of the head was eighteen inches. There was no paralysis or rigidity of any part, nor any evidence of mental deficiency, the child being bright and lively, taking notice of things going on and recognising persons; it did not appear to be in any pain, and was not fretful. There was no vomiting, no optic neuritis nor deafness, no signs of rickets. One week after admission the child had an attack of diarrhœa, during which the circum-

Digitized by Google

ference of the head diminished slightly, and the fontanelle became depressed, but when this ceased the progressive enlargement of the head continued, the child wasted, became rather drowsy, presented from time to time a convergent squint, and marked redness of the scalp continued. The course of temperature was singular, there being periods of from three to seven days of normal temperature with alternating periods of similar duration, in which it remained above normal and varying from 102·4° to 99°. The child died rather suddenly seven weeks after admission without developing any other symptoms. At the autopsy, when the dura mater was incised in the removal of the skull-cap 8 ounces of clear straw-coloured fluid escaped on the left side, and a little more than 8 ounces on the right side. On both sides the dura mater was found to be lined by a distinct membrane from one fourth to one sixth of an inch in thickness, the outer surface of which was firm and tough, of pink colour, and firmly adherent to the dura mater, the inner surface was soft, of yellowish-white colour, with many flocculi and felt-like processes. This membrane gradually became thinner towards the base of the skull, and in both sides extended only a short way over the tentorium cerebelli, the under surface of which was healthy. Lying over the surface of the brain was a soft friable layer of lymph, continuous at the base of the skull with the thicker membrane lining the dura mater; the effused fluid had occupied the space between these two membranes on each side. When the layer of lymph was lifted off the surface of the brain was found to be quite smooth, slightly injected and congested, the subarachnoid tissue slightly œdematous, with a few splashes of lymph on its surface. The cerebral hemispheres appeared uniformly shrunken, like a brain which had been hardened in spirit, their substance was very firm; the ventricles were not at all distended, and contained no fluid. The cerebellum was healthy, and appeared of large size as compared with the shrunken hemispheres. There was no other disease, except that the spleen was enlarged, measuring three inches by one and a half inches, tough, firm, and uniformly adherent to the surrounding viscera. A microscopical section of the membrane lining the dura mater shows from without inwards, first a layer of well-formed fibrous tissue, then a layer of fibrous tissue in which hæmorrhage has taken place, next a layer of fibrous tissue between the fibres of which are a large number of embryonic cells and nuclei, and lastly a thick layer of large cells with granular contents

Digitized by Google

with several nuclei, and of irregular shape, lying in the spaces of a fine meshwork of branching fibrils. The membrane contains also numerous vessels, which run towards the dura mater.

There is evidently here a new-formation between the arachnoid and dura mater, and the condition comes under the head of serous pachymeningitis. I have not been able to find a similar case in any English work, the text-books all assert that such a condition is unknown., A case is reported in vol. xxxvii of this Society's 'Transactions' by Dr. Edmonds, under the heading of external hydrocephalus, but here it is said that the head was not obviously hydrocephalic, and that there was nothing abnormal within the skull, except that the brain was small and ill-developed, and the surrounding space between it and the skull filled with clear fluid. Professor Henoch, in his recent work on diseases of children, says that he has seen two cases, and reports the notes of one case, a child 10 months old; here 10½ ounces of fluid were present, and a similar membrane lined the dura mater, the ventricles being empty and perisplenitis present; the posterior fossa of the skull was free from membrane. Commenting upon this condition, he says that the points in favour of the diagnosis of external hydrocephalus are: slight development of cerebral symptoms, and absence of intellectual impairment. I think, on comparing his cases with the present one, we may add as pointing to this condition signs of affection of the spleen, periods of normal temperature alternating with periods of pyrexia, also redness and congestion of the scalp. I may also mention that a similar condition has been found in general paralysis of the insane, but never, so far as I am aware, with the production of so much fluid or any obvious enlargement of the head. As to the ultimate cause of this condition I am unable to give any explanation; when occurring in adults it has been supposed to be due to hæmorrhage beneath the dura mater, but I think that the microscopical appearances show that the amount of blood extravasated is extremely small, and that it has taken place into a membrane which was already present. It may be a manifestation of syphilis, and the condition of the spleen is perhaps in favour of that view, but there was no other evidence to suggest this. *November 4th*, 1890.

Digitized by Google

2. *Extensive chronic gummatous pachymeningitis of five years' duration.*

By G. Newton Pitt, M.D., for R. Cuff, M.D.

Wm. W—, aged 23, was seen by Dr. Cuff, of Scarborough, in consultation with Dr. Malvin, in November, 1887. He was suffering with intense pain in his head, radiating from a spot two inches behind and one inch above the right external auditory meatus; the attacks of pain culminated in general convulsive seizures, without loss of consciousness, as frequently as thirty or forty times in the twenty-four hours. The attacks were as severe at night as in the day. He was confined to his bed, and was greatly emaciated. When he attempted to walk he reeled about, but no paresis of the limbs could be detected.

The right pupil was rather larger than the left, which latter was fixed in places by adhesions due to iritis, and there was evidence of commencing optic neuritis in the left eye.

The patient states that about 1885 he had a chancre, but he is not aware that he has had any secondary eruptions. In 1886, after carrying some tiles down a ladder from a three-storied house, he went indoors and fell down in a fit, knocking the back of his head against the iron foot of a table, cutting it severely; a scar still remains. When he recovered his consciousness his mouth was full of blood. He is not very clear as to these dates, but this was his first fit, and since this time he has never been free for three months from attacks.

Cerebral syphilis was diagnosed, and the patient was put upon large doses of iodide of potassium with Liq. Hyd. Perchloridi.

February, 1888.—The patient has greatly improved, he is able to walk about, and has about one fit daily. The iodide was discontinued.

When next seen, in July, the following notes were made:—He has two or three epileptiform attacks daily; there is intense pain above and behind the right ear, with great tenderness. There is double optic neuritis; the right disc is dark, with a hazy outline, the vision being good; the left disc is a brownish mass without outline, the vessels are obscured in places, the vision is barely $\frac{6}{60}$.

Digitized by Google

His gait is unsteady, the left arm is tremulous, and the movements inco-ordinate.

℞ Pot. Bromidi, ʒss.
Pot. Iodidi, gr. xv, t. d. s. ex aquâ.

September 10th.—The fits are more numerous, the pain is worse, the muscles on the left side are weak. The eyesight is very defective.

℞ Pot. Iod., gr. xx.
Pot. Bromidi, gr. xl.
Liq. Hyd. Perchlor., ʒj, t. d. s.

October 1st.—No fit for three days. The pain in the head is very troublesome, it starts over the right eyebrow, running over the side of the head to behind the ear. At times his sight is very dim for a few minutes, and then improves. During the next fortnight he had no fits, and his eyesight improved.

November 22nd.—Two fits to-day, with the face drawn to the left side.

February, 1889.—He has been progressing favorably, taking iodide of potassium, until four days ago, when he had two fits, and on the next day five fits. The left side of the face was drawn up. The left elbow and right knee were painful. The pupils react to light and accommodation, he can stand steadily with his eyes shut. The knee-jerk is normal on the left side, but diminished on the right. There is still pain and tenderness two inches above and one and a half inches behind the right external meatus.

℞ Pot. Iod., gr. xl, t. d. s.

18th.—There have been no fits, but the pain has been very severe.

March 11th.—The patient had a fit for half a minute, the first one for ten days. He now looks well nourished and healthy. The attacks are now of the following nature:—There is a transient loss of consciousness, stertorous breathing, a duskiness of the face, with general tremblings; this is followed in less than a minute by twitching of the face, irregular movements of the limbs, lasting for several minutes, after which the patient sinks into a lethargic (hysterical ?) condition, from which he can be roused by stimulation, cold water, &c.

During this period the character of the attacks had varied greatly. At first there were general convulsions, later on the general convulsions were preceded by epileptiform attacks, and

Digitized by Google

in 1889 there were momentary epileptiform attacks, followed by an hysterical condition.

The patient was admitted into Guy's Hospital July 9th, 1889, under the care of Dr. Pitt.

For the following notes we are indebted to the clinical clerk Mr. W. J. Scott.

Since the first fit in 1886 he has never been two months without having a fit. Often before a fit comes on he wants to defæcate, sometimes he reels about and falls if he cannot hold something to support himself. His head feels heavy, the left side of his nose contracts, and the contraction passes down to the left side of the mouth, drawing up the left side of the face. There is also a queer sort of pain passing down the left arm to the hand.

The arm and hand go to sleep and become powerless. These symptoms very seldom occur on the right side; and when they do they are very slight; this is immediately or a few minutes before a fit. He carries a clothes-peg about with him, which he puts in his mouth when an attack is coming on.

During a fit he is unconscious or semi-conscious; when the latter, he is able to hold the clothes-peg in his mouth, and can hear what is said without being able to reply. Both arms jerk about, the right usually more than the left, but sometimes the left does not move but is powerless.

On physical examination, he is a somewhat spare but healthy-looking man, with no abnormal physical signs, with the exception that the knee-jerk is slightly better marked on the left than on the right side, but there is no ankle clonus and no paresis of the muscles. The right optic disc is white and the tissue filled in, the arteries on the retina are smaller than on the disc, but none are very small. The atrophic condition is less marked in the left eye.

The field of vision in the right eye is normal, in the left it is limited to the temporal half of the field.

July 24th.—During the fortnight he has been in the hospital he has had only two or three slight seizures. He always carries a clothes-peg about with, and when deprived of this instrument he never has a fit. The attacks appear to be hysterical.

August 19th.—On returning from the closet at 4 a.m. he jumped vigorously into bed and called out, "I'm in a fit, I'm in a fit."

On examination, he was found lying on his back biting a stick vigorously. He contorted his face, rolled his eyes, and closed his

Digitized by Google

FIG. 1.

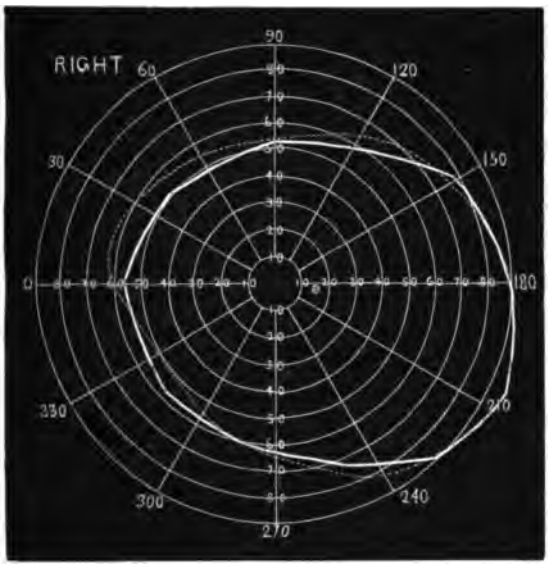

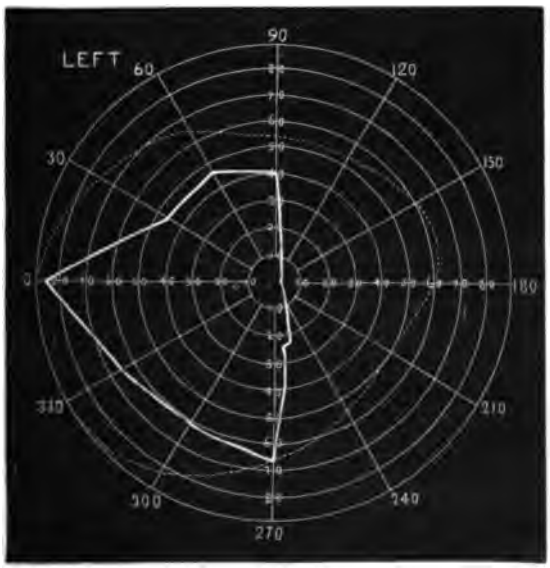

Fields of vision in July, 1889. The right is normal, the left is hemiopic. The defect is probably due to the optic neuritis.

Digitized by Google

eyelids tightly. The conjunctivæ were sensitive; there was no lividity nor stertor, the legs were not moved. The left arm was extended and trembled violently for some seconds, it then remained at rest for a short time, to be followed by trembling. He conversed during his attack, *e.g.* saying, "Look at my face;" which immediately became the seat of repeated twitching. When his stick was taken away the fit ceased.

Within ten minutes he was sleeping soundly, and remained very drowsy.

At 2 p.m., when asked if he felt any threatening of another fit, he said he did; within a minute he stretched himself out on the bed, rhythmical tremors took place in the left hand with movements of the left facial muscles. There was no stertor, no anæsthesia, no tonic contractions, and for some time he lay motionless, but was soon able to walk about.

On August 24th he went home, and Dr. Cuff hearing of his death in April, 1890, was able to obtain permission to examine the brain, which was hardened in Müller's fluid and sent up to Dr. Pitt.

Post-mortem examination.—There was caries of the inner surface of the whole of the right parietal bone with the exception of a strip half an inch wide along its anterior margin: the outer surface of the bone was healthy.

The thickened dura mater is adherent with the pia mater to the brain beneath over the area in diagram A.

There is a dense mass of more or less parallel lamellæ of fibrous tissue with some nodules of tough caseous débris, varying from one sixteenth to a quarter of an inch in thickness, lying between the dura mater and the brain over the area shown in diagram B.

The area in which the brain is infiltrated is limited to the angular and supra-marginal gyri and to a few spots in the lower part of the ascending convolutions as shown in diagram C.

The following are the appearances in a series of transverse sections, the positions of which are indicated in the diagram A.:

1. The dura mater is adherent over the first and second frontal convolutions, and is thickened over the second.

2. The dura mater is adherent over first, second, and upper part of third frontal, and there is a general slight thickening.

3. The dura mater is adherent over the three frontal convolutions and over the upper part of the first temporo-sphenoidal, but the

Digitized by Google

thickening is limited to the first three; there is a small patch invading the surface of the third frontal.

FIG. 2 A.

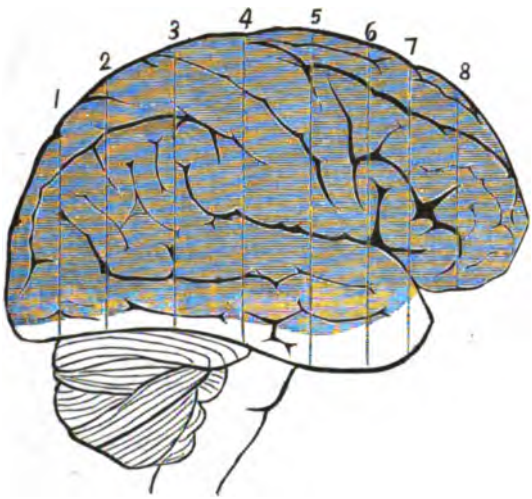

The shaded portion indicates the area over which the dura mater was adherent to the brain. The numbered lines correspond to the transverse sections of the brain which are described.

FIG. 2 B.

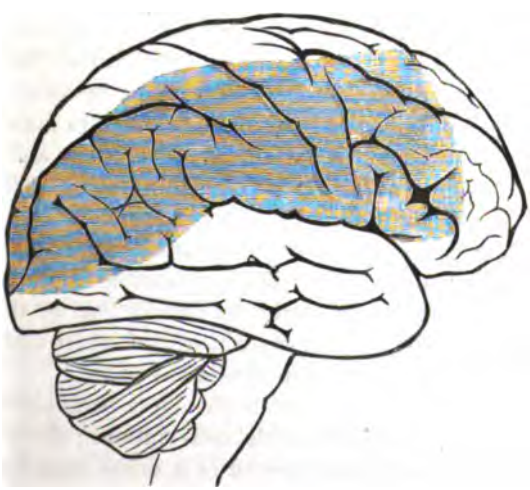

The shaded portion indicates the area over which the dura mater is thickened.

Digitized by Google

FIG. 2 C.

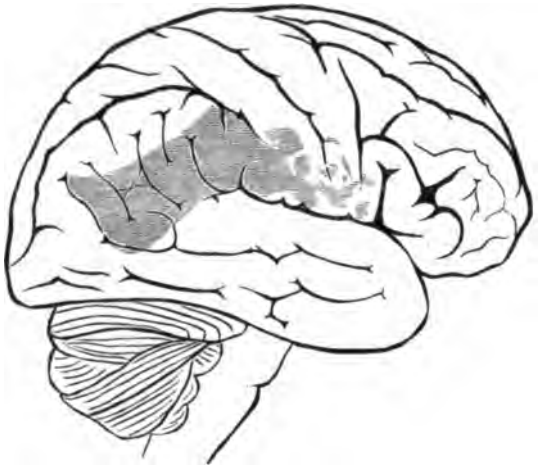

The shaded area indicates the portion of the cortex which is infiltrated with gummatous products.

4. The dura mater is adherent over the first and ascending frontal, over the ascending parietal and the first temporo-sphenoidal. There is a diffused gummatous mass half an inch thick over the ascending frontal and parietal convolutions; the gummatous mass infiltrates the lower part of the ascending parietal slightly to a depth of a quarter of an inch.

5. The dura mater adheres to both the ascending convolutions, to the supra-marginal and first and second temporo-sphenoidal convolutions. There is an extensive thick mass (half an inch thick in the centre) of fibrous and caseous material, the latter forming only small nodules lying beneath the dura mater over the ascending parietal and supra-marginal convolutions, and the supra-marginal convolution is invaded one third of an inch deep by similar chronic syphilitic products at one spot.

6. The dura mater over the superior parietal, supra-marginal, and first and second temporo-sphenoidal convolutions is adherent; there is a thick fibro-caseous mass over the inferior part of the superior parietal and the whole of the supra-marginal, which latter is more deeply infiltrated than anywhere else in the brain.

7. The dura mater is adherent to the supra-parietal, the angular and the second temporo-sphenoidal convolutions; the angular and the temporo-sphenoidal are covered by a dense mass half an inch thick, which infiltrates the former at its upper part.

Digitized by Google

8. The dura mater is adherent to the first occipital and the angular convolutions; over the latter there is a dense caseous and fibroid mass, which infiltrates its upper part.

Microscopically the gummatous products consist of parallel laminæ of dense fibrous tissue, with a variable amount of cell infiltration; in spots this is scanty and in others abundant. The caseous material fails to stain with hæmatoxylin. The appearances are those of a chronic gummatous meningitis. Sections of the pons and medulla do not show any descending degeneration.

The extensive area of the cortex, which is infiltrated by the gummatous products, consists of the greater part of the supra-marginal and angular gyri; but this infiltration apparently gave rise to no symptoms, the hemiopia in the left eye being readily explicable by the optic neuritis. The slight superficial infiltration of the lower part of the ascending convolutions by gummatous products would explain the twitching and tremors of the left side of the face, but no permanent facial paralysis was noticeable at any time.

The disease was a fibro-gummatous infiltration of the dura mater, setting up a caries of the right temporal bone on the one side and infiltrating the cortex on the other.

The deposit must have commenced previous to the cranial injury, but the latter probably determined the seat of the maximum intensity of the disease. The most extensive area is that over which the dura mater was adherent, while the gummatous meningitis extends beyond the portion of the cortex which is involved.

It is remarkable that so extensive a lesion should for many months at a time have produced but slight symptoms. There was no paralysis of the limbs, and no twitching or weakness of the muscles, except during and for a short time after the fits. In 1889 these fits lasted but a short time, were of infrequent occurrence, and were very much dominated by the succeeding hysterical condition. All the senses were normal, except that there was blindness over the nasal half of the field of vision of the left eye.

The case is remarkable on account of the wide extent of the disease, being more extensive than in any of the cases we have found recorded. The dura mater was adherent over practically the whole of the right lateral surface of the brain, and there was a gummatous deposit over an area about half this size.

The patient lived four years after his first fit, a duration beyond the average of these cases. *May 5th*, 1891.

Digitized by Google

3. *Thrombosis of cerebral veins.*

By William Collier.

The brain of a young woman, aged 23, who was prematurely confined of a stillborn child on January 4th of the present year. She remained upstairs for a fortnight, and was going on very well, when on January 20th she complained of headache, became very hysterical and aphasic, answering "Yes" or "No" to everything. In the course of a few hours she was seized with general convulsions, which chiefly affected the right side. The right side of face, the right arm and leg, became paralysed; she vomited at intervals during the first two days. Urine showed a trace of albumen. The convulsions were repeated with lessening intensity for four or five days, always more marked on right side, amounting at last to twitching of the muscles of the face only. As the spasms passed off she became semi-comatose, and continued so until death, which occurred on the 29th of January, in the early morning, eight days from the commencement of her illness. A few hours before death the temperature began to rise, reaching the maximum 107·5° F. at death.

Head.—On removing the skull-cap the dura mater appeared normal, but on raising this membrane the upper surface of left hemisphere was seen to be extensively ecchymosed over the parietal and greater part of the frontal lobes. Over this area there was a thin layer of lymph, and the veins (superior external cerebral) were distended, with soft dark blood-clot, especially where they entered the superior longitudinal sinus, contrasting markedly with the corresponding veins of the right hemisphere. The superior longitudinal sinus itself contained recent clot, but was not distended. The torcula Herophili and the right lateral sinus were distended with blood-clot, as also the right superior petrosal, but those of left side were almost empty. On removing the brain a similar condition of ecchymosis with distended veins (internal cerebral) was found on the mesial surface of the left hemisphere, which bulged inwardly so as to cause a depression on the mesial surface of right hemisphere.

The arteries at the base of the brain appeared quite normal;

Digitized by Google

they were empty. Nor was embolus found on tracing up the Sylvian and other arteries.

Brain weighed 42 ounces. The left hemisphere was softened down to the lateral ventricle, more especially immediately below the area of thrombosis on the surface; here it was almost diffluent, the punctiform ecchymosis extended through the grey matter into the white, for the depth of one and a half inches, the rest of the hemisphere was soft and yellow. The rest of the brain was quite normal, including the basal ganglia of the left side.

All the other organs of the body are healthy.

March 3rd, 1891.

---

4. *Local atrophy of cerebral convolutions.*

By J. A. Ormerod, M.D.

The left cerebral hemisphere of a brain is exhibited wherein the convolutions bordering the posterior branch of the fissure of Sylvius are atrophied. The lower parts of the inferior parietal lobule, including the supra-marginal gyrus, and the upper lip of the first temporo-sphenoidal convolution, are almost gone; the lower lip of the ascending parietal convolution and the rest of the first temporo-sphenoidal convolution are thinned.

The cause was not determined; the cerebral arteries appeared normal; the arachnoid covering the spot was thickened and depressed, beneath it was the gap in the convolutions now seen.

The arachnoid generally was rather watery-looking; the sub-arachnoid fluid in some excess; the surface of the brain rather soft. In the opposite hemisphere was a superficial cavity (three quarters of an inch in diameter), apparently hæmorrhagic in origin, situated in third temporo-sphenoidal convolution.

The patient had renal disease, large white kidneys with commencing interstitial changes and mitral disease. He died of uræmia. No symptoms pointing to the local cerebral disease were noted during life. *November 18th*, 1890.

Digitized by Google

5. *Heterotopia of the grey matter of the spinal cord.*

By Howard H. Tooth, M.D.

The spinal cord from the level of the first dorsal pair of nerves downwards was sent to me by my friend Mr. Woods, of the Hoxton House Asylum. The notes of the case unfortunately do not throw any light upon the condition of the cord, but are sufficient to establish the fact that the patient was a general paralytic.

H. H—, a musician, aged 24, admitted June 11th, 1884, to Hoxton House Asylum, was the subject of delusions, such as that he was enormously rich, and that every woman was in love with him. He was thin, pale, and with a silly self-satisfied expression. His pupils were unequal, the right smaller than the left.

On September 13th there is a note to the effect that he still had the delusions, his speech was hesitating and tremulous, and that the gait was somewhat tabetic in character. Unfortunately no further note can be found till that of the *post-mortem* on January 14th, 1885, at which was found a considerable hæmorrhage between the dura and skull, from the left middle meningeal artery. The subarachnoid space contained an immense quantity of fluid. All the membranes were thickened. Brain generally small, convolutions flattened. Ventricles full of fluid. The lungs were both disorganised, and full of cavities. Pleuræ strongly adherent.

The spinal cord came into my hands at the end of January, 1885. It was hardened in potassium bichromate 2 per cent. solution. Small pieces of the cord were taken at various levels, and placed in strong picrocarmine for a week or more, then dehydrated and completely penetrated with paraffin wax. The sections made for these were stuck to the slides with shellac and creosote, the wax removed with turpentine, and mounted in balsam.

Microscopical examination of spinal cord.—Dorsal I (see Fig. 3).—General configuration of section quite recognisable. Anterior horns cut off from posterior by a bridge of white matter, which contains several normal nerve-fibres, but generally exhibits the features of acute softening. The lateral limiting layer on both sides is sharply defined, marking the line of demarcation between the lateral region and the grey matter that has disappeared. The grey matter of the anterior horns shows here a tendency to bud off a part of its

Digitized by Google

substance as a thin strip on the left side, more extensively on the right. In the part budded off from the right horn are two or three ganglion-cells. The neuroglia of the lateral region shows considerable thickening, especially on the right side, but the nerve-fibres seem to be normal.

The connective tissue of the pia and arachnoid is somewhat thickened, and there is evidence of inflammatory process in the anterior fissure. This applies to all the sections. The anterior and posterior roots here and throughout the cord present perfectly normal appearances.

Dorsal II.—The same general appearance as in the last section, but the signs of inflammation are more marked. The thickening of the neuroglia is very pronounced in the right crossed pyramidal tract.

Dorsal III.—A complete change in the disposition of the grey matter. The only indication of the position of the section antero-posteriorly is the position of the anterior spinal artery. The anterior roots indicate where the anterior horns should be. The left anterior horn is represented by a rounded mass of grey matter, in which can be found in one section only one ganglion-cell, though there are several masses of hyaline material, which may be degenerated ganglion-cells. The right anterior horn is absent altogether. The right lateral limiting layer is visible, which enables one to determine that the strip of grey matter passing down to the periphery of the section is the right posterior horn. In this can be seen a few cells in the position of the tractus intermedio-lateralis, and one or two bipolar cells on the left side of its base indicating the posterior vesicular column. On the left side of this posterior horn is seen a small island of grey matter containing several small bipolar cells. This is probably the dislocated left posterior vesicular column. It can be seen to have some sort of continuity with a mass of granular matter situated on the left side in the periphery of the section, which is probably the substantia gelatinosa of the left posterior horn. The left posterior roots are absent in this section.

Dorsal IV.—The disintegration of the grey matter attains its maximum in this section. The grey matter is represented by one islet of fair size, deeply stained, and showing a number of ganglion-cells of the bipolar type. This is, therefore, possibly the posterior vesicular column, probably of the right side. The rest of the grey matter is distributed in strips round the edge of this section, two of which might be the substantia gelatinosa of the two posterior horns,

Digitized by Google

but no ganglion-cell-containing substance can be found. The white matter is generally much softened and altered. Very few normal nerve-fibres can be seen.

Dorsal V.—Here again the general appearance of the spinal cord section is absent. The grey matter is disposed as one strip running probably antero-posteriorly.

Dorsal VIII.—The general appearance of the grey matter is now restored. There is decided sclerosis of the crossed pyramidal tract on both sides, probably secondary. The left anterior horn is smaller and more stumpy than natural, but contains normal ganglion-cells. The left posterior vesicular column is in its proper position, but is attenuated by a mass of degenerated myeline material, which presses it to one side. In the commissure is a mass of granular, deeply-staining material. The right anterior horn is much attenuated, and much longer than the left. Lying against the anterior fissure is a mass of grey matter without ganglion-cells, which looks as if it had been chipped off from the horn. The right posterior vesicular column, and tractus intermedio-lateralis, are absolutely normal.

Dorsal IX.—Sclerosis of lateral column as before. Complete dislocation of left posterior vesicular column, so that it becomes applied to the posterior median aspect of the posterior commissure, its proper anterior end abutting on the posterior septum (Fig. 3, D. IX). Its histological appearance is apparently quite normal. Its place is taken by a loose tissue, in which can be seen several medullated nerve-fibres.

Dorsal X.—Sclerosis of lateral columns very marked. Anterior horns stunted, the left containing very few ganglion-cells, the right fewer than normal. The left posterior horn is broken up into three fragments. One retains the position of the posterior vesicular column, and contains characteristic ganglion-cells; another, not far from this, marks the outer limit of the horn; the third, a small mass at the point of entrance of the posterior roots, is probably the remains of the substantia gelatinosa. The posterior vesicular column is absent on the right side.

Dorsal XII.—Posterior horn and posterior region generally most affected. Sclerosis of lateral columns still. Basal part of both horns much attenuated. Substantia gelatinosa and spongiosa remain on the left side, but on the right side are broken up and dislocated. Near the middle line on the right side are several

Digitized by Google

patches of staining material, which may be the remains of the basal parts of the posterior horns.

Lumbar I.—The left posterior vesicular column has quite disappeared, its place is taken by apparently normal nerve-fibres, in a rather thickened neuroglia network. The posterior region has a disturbed appearance. The right posterior vesicular column is present, and is normal as regards its contained cells. There is a small mass of grey matter (?) in the right postero-lateral column.

Lumbar IV.—The left posterior vesicular column is apparently dislocated so as now to appear on the lateral aspect of the horn. The right posterior vesicular column is much attenuated, but has natural ganglion-cells in it. The posterior region generally shows much disturbance and sclerotic thickening, dotted about it are islets of grey matter (?). Anterior horns quite natural.

Sacral I.—Similar affection of posterior region to last, with dislocation of substantia gelatinosa and spongiosa.

Sacral II.—Right posterior horn has disappeared, large masses situated on each side of left posterior horn.

Summary of microscopical appearances:—1. Evidence of inflammation, acute and chronic, as shown by the thickening of the membranes, patches of softening with disappearance of medullated nerve-fibres, and local increase of neuroglia.

2. The condition of the grey matter. This presents a great variety of appearances, from a comparatively slight alteration of shape to almost complete disappearance and disorganisation. In no section is the appearance normal.

3. The ganglion-cells show great vitality. In the section shown in Fig. 3, D. IV, where there is only a small patch of grey matter left, there are still one or two cells altered but recognisable.

4. In the section in which the inflammatory processes are less evident and extensive there is a tendency for pieces of the grey matter to be removed to points distant from their original position (heterotopia). The removed pieces may be altered or retain generally their normal appearance. See Fig. 3, D. XIII to S. IV.

5. The space left by the displaced grey matter may be occupied by inflammatory softening, or by apparently quite normal medullated fibres (cf. Fig. 3, L. 1).

6. Where the disorganisation of the grey matter is greatest there is also the greatest affection of the surrounding white matter.

7. At points below the most disorganised region there is

Digitized by Google

FIG. 3.

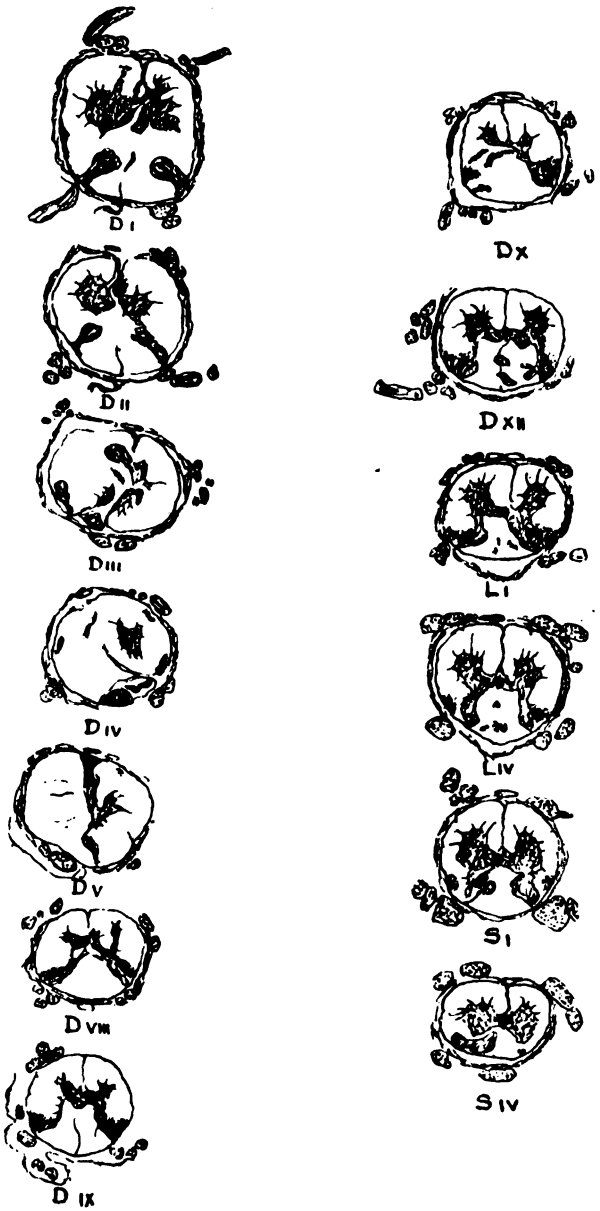

Sections of the spinal cord described in the text. The letters indicate the levels at which the sections are made.

Digitized by Google

decided sclerosis of the crossed pyramidal tract, such as might follow a transverse myelitis (Fig. 3, D. VIII, *et seq.*).

8. All through cord there is a tendency for the posterior region to be affected most. The grey matter of the posterior horns in all the sections from Dorsal VIII downwards exhibits, in a greater or less degree, the peculiarity called heterotopia. The anterior horns show this peculiarity much less constantly.

9. The anterior and posterior nerve-roots present normal appearances in every section.

Remarks.—This curious condition has received some attention from German writers. A short bibliography will be found in Kronthal's[1] paper, and the latest article on the subject is by Jacobsohn.[2]

There seems to be a tendency to confuse two distinct conditions. The two observers above mentioned note and figure a condition they call "Doppelbildung," or reduplication of the cord in the lumbar region. The most remarkable recorded case of this kind is one by Fürstner and Zacher,[3] in which there was almost perfect reduplication of the lumbar cord. This, of course, must have been a purely developmental aberration, and need not, as far as one can see, necessarily have given rise to any symptoms. The patient, however, died of general paralysis. The well-known tendency of abnormally developed organs to disease must be borne in mind. A slight or even considerable asymmetry between the two halves of the transverse section of the cord is decidedly common, as anyone who has examined many will testify. An extreme degree of this asymmetry is figured by Schiefferdecker[4] from a case which gave no signs during life which could be referred to the condition of the cord.

The question now arises whether the appearances in heterotopia be secondary to inflammation or whether they existed before as a developmental abnormality, which has since become the seat of acute or chronic inflammation. An inquiry into the diseases to

[1] Kronthal, "Ueber Heterotopie grauer Substanz im Rüchenmark," 'Neurolog. Centralbl.,' 1888, p. 97.

[2] Jacobsohn, "Ein Fall von partieller Doppelbildung und Heterotopie des Rückenmarkes," 'Neurolog. Centralbl.,' 1891, p. 38.

[3] Fürstner und Zacher, "Ueber eine Eigenthümliche Bildungsanomalie des Hirns und Rückenmarkes," 'Arch. f. Psych.,' 1882, p. 373.

[4] Schiefferdecker, 'Asymmetrie der grauen Substanz des Rückenmarkes," 'Arch. f. Mikroskop. Anat.,' Bd. xii, 1876.

Digitized by Google

which the recorded cases succumbed does not throw much light upon the subject, except to show that they, most of them, died of some chronic nervous disease, several from general paralysis. The examination of the cord in the case which is the subject of this communication leads one rather to the conclusion that a widely spread inflammation of the grey matter is at the bottom of the affection. *April 7th*, 1891.

---

6. *Heterotopia of the grey matter of the spinal cord.*

By C. M. Campbell, M.D., and William Aldren Turner, M.B., M.R.C.P.

The patient in whom this very rare abnormality of the spinal cord was found consulted Dr. C. M. Campbell in June, 1887, for an obstinate and painful affection of the skin. The notes taken then and subsequently we have epitomised as follows:

History.—A. P—, aged 26, has suffered from an affection of the skin, with occasional remissions, since ten years of age. He has been treated by Sir Erasmus Wilson and other well-known dermatologists. He is a tall, strong, well-developed young man, and there is no history or sign of syphilis, either congenital or acquired.

Present condition.—Upon the skin of the shoulders, loins, thorax, abdomen, genitals, and upper and lower extremities, are areas, varying in size from a pin-head to a foot or more in diameter, having convex, sharply-defined borders, and in many places being confluent. These areas are slightly raised, rugged and scaly, varying in ground colour from rose-red to raspberry, or almost purple. They are sometimes dry, but as often exhibit copious exudation. The scales are mostly buff-yellow in colour, nowhere silvery as in psoriasis, and are in places intimately mixed with exudation crusts; large flakes are constantly being exfoliated. The nails of both hands and of both feet are hypertrophied, but are friable and opaque. They are constantly being shed, and the nail-beds and matrices are swollen and erythematous.

The itching of the lesions on the skin is at times intolerable. Treatment produced only temporary palliation, and the disease with each recrudescence increased in area and intensity.

Digitized by Google

About a year later the following additional lesions were recorded:—Great effusion and severe pain in nearly all the joints, large and small, of the upper and lower extremities, on both sides, also in the costal and sterno-clavicular articulations. There was slight pain on pressure over the tenth, eleventh, and twelfth dorsal vertebræ. The knee-jerk on both sides was exaggerated, and there was general muscular hypertonicity. The urine was alkaline, slightly albuminous, and contained pus-cells. Attacks of subacute bronchitis recurred from time to time, and there was intractable insomnia.

From this time onwards until his death in April, 1890, the chief points noted were: continued recurrence of arthritis, involving nearly all, if not all, the articulations of the extremities; contraction of extensor muscles of both forearms; increasing emaciation, extension of the diseased areas of skin, and flexion of the lower extremities. Decubitus occurred on the sacrum, and the patient died of exhaustion.

Post-mortem notes.—A quantity of blood-stained mucoid fluid was found outside the dura mater in the dorsal region. The lower dorsal portion of the cord was so soft that there was great difficulty in removing it intact. On the posterior surface of the tenth dorsal vertebra there was a small carious erasion, but there was no collection of pus, nor pressure on the cord. The microscopical examination of the cord presents two features of interest.

1st. An abnormal arrangement of the grey matter in a limited portion of the cord—heterotopia.

2nd. Myelitis occupying the region of this abnormality.

1. At the level of the cervical enlargement of the cord the relations of grey and white matter are perfectly normal. About the level of the sixth dorsal nerve the anterior median fissure passes right up to the grey matter, so that the anterior white commissure is divided. The posterior cornua are considerably attenuated, but the posterior median fissure is at this point normal. At the level of the seventh dorsal nerve the anterior median fissure becomes diverted from the middle line, closely approaching the left anterior horn, the latter being prolonged considerably forwards. At this point the posterior median fissure does not extend to the periphery under which the posterior columns are united by a bridge of white matter. The central canal of the cord is absent.

At the level of the eighth dorsal nerve all these points are still

Digitized by Google

evident, and, in addition, the posterior horns have become constricted in front of the substantia gelatinosa Rolandi, but remain joined to the anterior parts of the grey crescents by a narrow bridge of grey matter.

The deepest part of the posterior median septum has now become obliterated. A short distance below this the posterior or grey commissure becomes considerably broadened, whereby the anterior median fissure is shortened.

A segment lower down we reach the area of softening, which involves the portion of the cord corresponding to the origins of the tenth, eleventh, and twelfth dorsal nerves. At the highest part of this region we note the following points:—The anterior median fissure is markedly curved, the convexity being to the right, and it reaches up to the grey commissure.

The posterior median septum is absent, its site being indicated by a small island of connective tissue, lying midway between the grey commissure and the posterior periphery of the cord. The posterior columns are fused together. The right grey crescent is completely divided into two portions in front of the substantia gelatinosa; the anterior horn is atrophied, but contains a few nerve-cells; the posterior horn is broadened out into a large triangular-shaped mass, the base of which is turned towards the periphery. The fibres of the posterior nerve-roots pass into this mass, but in considerably less number than on the opposite side. The vesicular column is represented by a few scattered nerve-cells.

On the left side the two parts of the grey crescent are connected by a bridge of grey matter; Clarke's column is well developed, as also are the nerve-cells of the anterior horn and the anterior nerve-roots.

Passing downwards to the middle of the softened region, we find that the left anterior horn is represented by a triangular mass of grey matter, the apex of which is drawn out into a serpentine narrow streak, connecting it with the remains of the posterior horn. The anterior median fissure is in close relation to the median face of this triangle, and the grey commissure is represented by a spur-like process from the right grey crescent. The left posterior horn is represented only by a small portion of the substantia gelatinosa.

The right anterior horn is here placed very far posteriorly in the cord, and it contains multi-polar nerve-cells. Some distance in

Digitized by Google

front of it there is a small island of what is apparently grey matter, but which has no connections with the other grey structures. The right posterior horn is a mere small appendage to the anterior grey mass, there is no central canal nor posterior median septum.

In the next section we reach the climax of abnormality. The four horns of grey matter are now completely separated into four islands, without any connection between them. The left anterior horn appears as a narrow atrophied island without any nerve-cells in it. The left posterior horn is entirely absent, but a horizontally placed island of grey matter, which appears to be a part of the posterior nerve-roots, occupies the periphery. On the right side the anterior grey mass is large, and contains nerve-cells, but it has no connection with the grey mass which represents the posterior horn.

The anterior median fissure is represented by a short spur-like process, cutting the cord for a short distance from the anterior periphery. There is no trace of the posterior median fissure.

The columns of white matter occupy their normal position and course, except that from the central part of the section. Horizontally running fibres pass outwards and encircle the posterior ends of the anterior grey islands, which are separated mesially by fibres, which are cut transversely and obliquely in cross section of the cord.

The arrangement of the grey and white matter in the lumbar enlargement and conus medullaris is perfectly normal.

2. The myelitis is indicated by the usual characters: considerable dilatation and engorgement of the blood-vessels, with surrounding leucocyte infiltration; enlargement and varicosity of the axis cylinders, and peripherally an increase of the delicate connective tissue of the cord. The whole transverse section is involved in the myelitis, but its results are more evident near the circumference than around the grey matter. This condition is maintained in the cervical enlargement, where, in addition, we observe an early degeneration in the tracts conducting upwards, viz. the postero-median, direct cerebellar, antero-lateral ascending. The small border tract of Lissauer is also degenerated. In the lumbar enlargement the meningo-myelitis above described is also recognised to a slight extent.

The points of importance noticeable in the skin sections taken from the tip of an affected finger are:

Digitized by Google

FIG. 4.

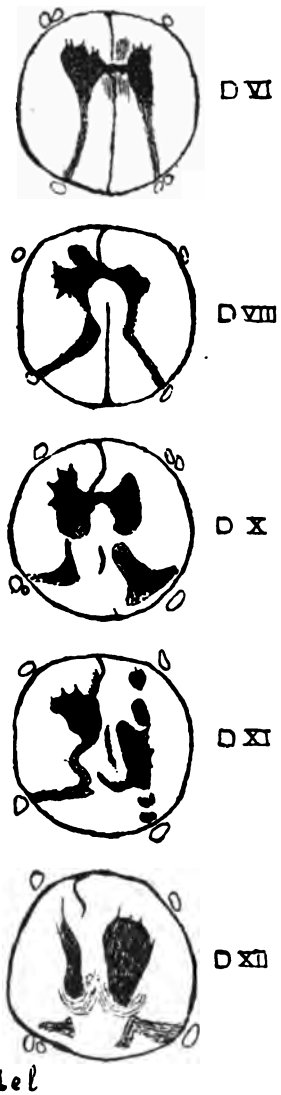

Sections of the cord described in the text. The letters indicate the levels at which the sections are taken.

Digitized by Google

1st. Obliterative connective-tissue growth in the arteries. In cross section many of the vessels appear with the lumen completely closed by the shrivelled intima, which is surrounded by many concentric layers of connective tissue; while the adventitia remains normal. Some vessels, both large and small, are still permeable although reduced in calibre, but none appear to have escaped entirely.

2nd. The derma is crowded with leucocytes, which are also found in the intercellular spaces of the prickle cell layer of the epidermis.

3rd. The interpapillary epidermal cones are unusually prolonged as compared to normal skin from the same region, piercing the derma to a great depth.

4th. The prickle cells in many cases retain their nuclei, do not become cornified, and do not join firmly with each other as they advance to the surface.

No true stratum lucidum is formed, and the outermost layer of epidermis consists of loosely coherent cells, some still nucleated interspersed with which are some small round cells. These abnormalities are, however, not present in all parts of the sections.

This case is of interest pathologically, in that it exhibits a very rare structural abnormality, and exemplifies the liability to myelitis possessed by such abnormal formations. Clinically we believe it to be of great importance; but we deeply regret that circumstances prevented our obtaining all the pathological material necessary for an exhaustive inquiry. Thus we have no. specimens of the posterior root ganglia, and only these of the peripheral nerves, which may be found in the skin sections from the finger tip.

We therefore refrain from drawing any conclusions; but would merely suggest what appear to us to be points for speculation.

1st. The persistent and ever increasing inflammatory condition of the skin, lasting for about twenty years, and most fitly described as an exfoliative dermatitis.

2nd. The severe polyarthritis in relation to the advancing disease of the spinal cord.

3rd. The possibility of a long-continued source of peripheral irritation initiating central inflammatory changes in a spinal cord structurally predisposed thereto.

4th. Conversely, the possibility of trophic changes in the skin,

Digitized by Google

being the earliest manifestation of progressive degeneration affecting trophic nerve centres.

References.

(1) *Fürstner and Zacher.*—'Archiv für Psychiatrie,' Bd. ii, S. 373, *et seq.*

(2) *Kronthal.*—'Neurol. Centralblatt,' 1888. No. 4. Twelve cases have been recorded up to this time.

(3) *Kronthal.*—'Neurol. Centralblatt,' 1890. No. 13.

(4) *Jacobsohn.*—'Neurol. Centralblatt, 1891. No. 2.

April 7th, 1891.

---

7. *A case of syringomyelus.*

By James Galloway, M.B.

[With Plate I.]

The specimen of which the description is given has been in my possession since the end of 1886, but I have thought it worthy of being placed on record, partly on account of the somewhat rare condition of which it is a good example, and also on account of the increased interest which has been shown in this subject of late, especially by French observers.

The following are a few extracts from the clinical records of the case to emphasise the more important facts observed during life:

"Charles R. B—, aged 43, was admitted to Bethnal House Asylum on the 20th May, 1886."

"May 30th.—Patient is evidently suffering from general paralysis of the insane, in an initial stage, accompanied with great excitement. The facial tremors are well marked, and there are fibrillar twitchings of the tongue on protrusion. Pupils contracted, reflexes exaggerated, but gait is perfectly steady."

"June 8th.—Patient spends his time developing grand schemes for the welfare of his fellow-patients. There is great irritation and itching of the skin to-day, which, he says, is due to a cayenne

Digitized by Google

pepper bath given him by the attendant last night. There is great motor excitement, and patient has spent most of to-day running round a rockery at full speed."

"July 19th.—Is still excited and restless. Says he is acted on by electricity, and thinks the devil is inside him. Delusions of grandeur still persist."

"August 20th.—He is excited, noisy, dirty, destructive, and happy. He is in the habit of scratching himself till he makes large raw surfaces on various parts of his body."

"September 24th.— . . . He is losing flesh, and rapidly becoming weaker."

"October 2nd.—For the last few days he has been more excited and restless than ever, saying that the devil is inside him and cannot get out. He has torn his skin to pieces, and three days ago he seized the point of his penis between his fingers and thumbs, and split open the urethra longitudinally for half an inch on the under surface." An account is given of other injuries he inflicted on himself, on account of which stringent precautions had to be taken to prevent further self-injury.

"5th.—Patient suddenly collapsed and died in a few hours, death being caused by exhaustion from acute mania occurring in the course of general paralysis."

Report of post-mortem examination.—"Brain firm, considerable accumulation of subarachnoid fluid. Membranes thickened, adherent to brain over the apices of convolutions, especially of frontal lobes. Ventricles dilated, lining membranes granular. Cord appeared healthy externally. . . . . Lungs very œdematous and congested. Liver fatty. Other organs normal."

To the naked eye the spinal cord and its membranes seemed normal, except in the dorsal region, where the cord had the appearance of a collapsed tube. In this region, as will be noted subsequently, the morbid changes in the cord were most extensive. On making sections across the cord a cavity was found to occupy the central portion, extending from the cervical to the upper lumbar region. In certain regions the cavity seemed to be divided into two parts, by a partition stretching from the back to the front of the cord. In the dorsal region the cavity reached its largest size, so that the cord collapsing allowed of the anterior columns coming into contact with the white matter of the posterior regions. Below

Digitized by Google

the upper lumbar region no sign of cavity was noted, and to the naked eye there was no appearance of degeneration of the white substance.

On more careful examination of the cord, after hardening in Müller's fluid, the following notes were made:

Cervical region.—Upper portion. Cord measures 12 mm. transversely by 6 mm. antero-posteriorly. The opening in the centre is distinct, being about 2 mm. transversely by 1 mm. antero-posteriorly, is rectangular with rounded angles. The opening is surrounded by a ring of tissue whiter than the surrounding cord, and corresponding in shape to the opening. This ring is barely 1 mm. in breadth, is very dense, and stands up from the surrounding substance of the cord. At the widest part of the cervical enlargement the cord measures 16 mm. by 7 mm., and the appearance of the central cavity, with its surrounding ring of dense tissue, is similar to that already described. The cavity here measures 2·3 mm. by ·8 mm., and the ring of dense tissue is about 1·5 mm. in thickness. The central cavity gradually changes its shape while passing down the cervical region. It first widens out transversely and becomes narrow antero-posteriorly, so that at one point it is a more transversely placed slit. It then becomes gradually placed obliquely to the transverse axis of the cord.

Dorsal region.—The cord in this region is much smaller in size, measuring 8 mm. transversely by 4 mm. antero-posteriorly in the upper dorsal region. The central cavity increases in size very markedly, and alters its form. It is seen to involve the grey matter of the cord, and to depend on that fact for its somewhat peculiar shape. It first becomes triangular, the two basal angles being situated in the anterior grey cornua, and the apex in the line of the posterior median fissure. While in this condition the firm white tissue is found surrounding the posterior angle only, being absent from the two basal angles and the base, and gradually increases in amount along the sides of the triangle till the apex is reached, where there exist a mass of firm white tissue, about ·5 mm. in breadth. Somewhat lower in this region the apex of the triangle (situated posteriorly) becomes divided off, by a partition of the firm white tissue stretching transversely. At this level, therefore, there are actually three cavities in the cord, one formed posteriorly in the manner described, the other two consisting of the two basal angles, which have gradually crept forwards into the

Digitized by Google

Digitized by Google

DESCRIPTION OF PLATE I.

Illustrating Dr. Galloway's communication on Syringo-myelus. (Page 26.)

From drawings by Mr. J. Angus.

FIG. 1.—Transverse section through the cervical region of the spinal cord, showing complete disappearance of the grey matter, a large central cavity, and almost complete absence of the neuroglia growth. (From Dr. Turner's case, 'Trans. Path. Soc.,' vol. xxxix.)

FIG. 2.—Transverse section, upper dorsal region of the cord, showing alteration in the position of the cavity. The position of the central canal is observed. (From Dr. Turner's case, 'Trans. Path. Soc.,' vol. xxxix.)

FIG. 3.—Transverse section through the cervical region of the case reported in this paper. It shows the abnormal mass of neuroglia, and the position of the cavity; the peculiar frilled appearance of the internal layers of neuroglia is indicated.

Fig. 4.—Transverse section through the dorsal region. The great destruction of the central grey regions of the cord and the position of the mass of neuroglia with its cavity are well seen.

The specimens cut in celloidin were stained by Weigert's Hæmatoxylin-copper method.

Digitized by Google

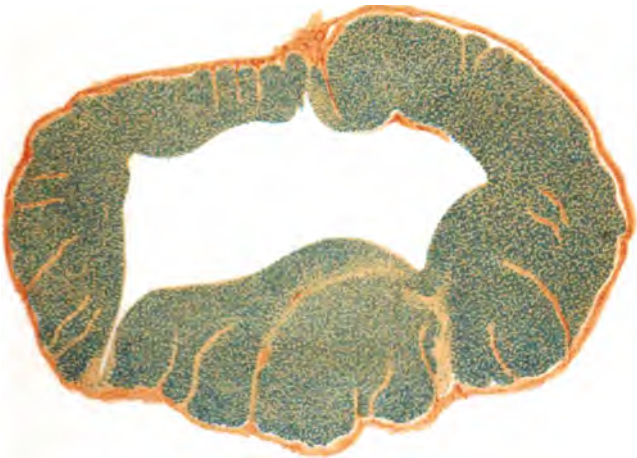

Digitized by Google

Digitized by Google

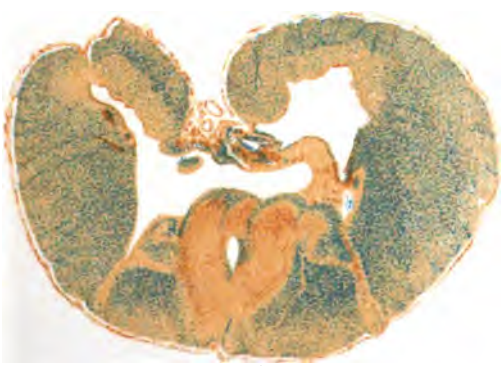

Digitized by Google

Digitized by Google

anterior grey cornua. Those two lateral cavities increase greatly in size, and in the mid-dorsal region come to occupy the position of nearly all the grey matter of each half of the cord. In consequence of the disappearance of the central portions of the cord the peculiar flattened appearance is produced in this region, as has been already mentioned. In the lower dorsal region the two lateral cavities gradually diminish in size, till in the lowest portion of this region much the same appearance is presented as in the cervical region. Here there is again a single cavity, situated somewhat posteriorly, elongated in an antero-posterior direction, and surrounded by a ring of firm white tissue. This tissue is massed at the anterior margin of the cavity, where it measures 1 mm. in width, and gradually disappears at the sides of the cavity, till at its posterior extremity there is practically none of the tissue to be observed. Even when the two lateral dorsal cavities are most developed they do not seem to communicate, being always separated from each other by a fibrous septum containing numerous vessels but no trace of nerve-tissue, and running in an antero-posterior direction.

Lumbar region.—The cord increases in size, and measures 9·5 mm. by 8 mm. at the lumbar enlargement. At the upper extremity of this region a small pin-hole cavity may be observed, surrounded with a relatively thick ring of firm tissue, about ·5 mm. in thickness. Soon the cavity disappears, and immediately afterwards the firm tissue, which is now situated behind the posterior grey commissure, is also lost to sight. Throughout the lower three fourths of this region, and to the termination of the cord, there is no trace of cavity nor of the surrounding dense tissue.

The spinal nerves seem to be given off normally throughout the course of the cord.

Relations of the central canal of the cord to the cavity.—The central canal of the cord is seen to be situated anteriorly to the cavity throughout, except in the mid-dorsal region. In places the central canal seems normal in appearance, being lined with cubical epithelium showing well-marked nuclei; but where the cavity becomes large the central canal assumes a degenerate appearance. It then becomes elongated transversely, and its situation is marked by a number of nuclei somewhat larger than those of the surrounding neuroglia. A change such as this, however, is quite common

Digitized by Google

FIG. 5.

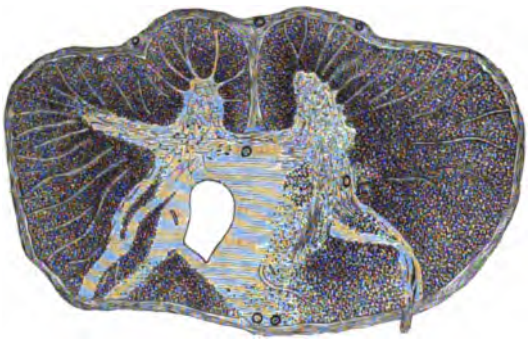

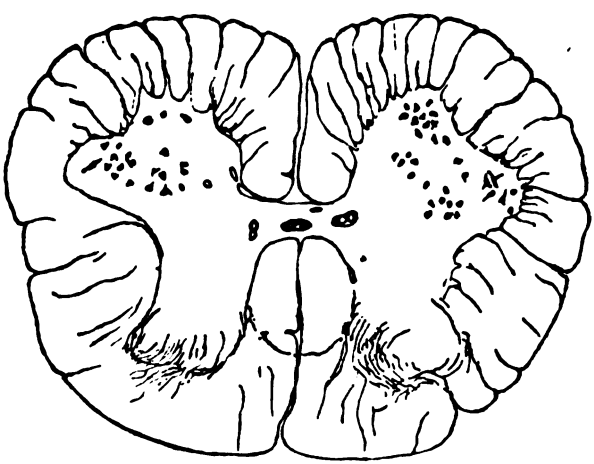

The upper sketch represents a section through the lower dorsal region of the cord described.

The lower sketch is of a section through the upper lumbar region, and shows the position of the mass of neuroglia just before it disappears. Magnified about 200 diameters and reduced.

Digitized by Google

in cords which are otherwise normal.[1] The noticeable feature in this case is that the degenerate appearances of the central canal are gradually assumed as the cavity becomes larger. In the mid-dorsal region, when the lesion is most marked and the cavity most extensive, no trace of central canal can be seen, nor are any remains of the typical cubical epithelium to be noticed on the anterior walls of the cavity. This peculiarity is obviously caused by the extension of the cavity forwards, so that at length the position of the central canal has been involved in the morbid cavity. As the central canal with its epithelium degenerates before the advance of the morbid cavity, when the central canal is actually opened into, there is no longer any epithelium to mark its site on the anterior wall of the cavity. Thus the absence of epithelium on the anterior wall of the cavity, the presence of which has been noted by many observers,[2] can readily be understood.

The position of the cavity and its surrounding ring of dense tissue is thus found to be situated behind the central canal of the cord, involving the posterior commissure to some extent anteriorly, and extending backwards for some distance between the posterior columns of the cord. The exception to this, in the mid-dorsal region, where the cavity involves the central canal and stretches forwards into the anterior grey horns has been noted.

The dense tissue surrounding the cavity.—This tissue is found to consist of an exceedingly dense feltwork of fibrils, studded with numerous small nuclei, the general direction of the fibrils appears to be parallel to the walls of the cavity. Lining the cavity at all points, but most easily observed where the surrounding tissue is largest in amount, is a layer of still denser tissue, in which the nuclei are less apparent. This layer of tissue acts as a sort of lining membrane to the cavity. On its inner surface it is usually smooth, but occasionally a few fibrils are seen projecting into the cavity. There is no trace of a layer of lining epithelium. At its outer margin this lining membrane is frequently remarkably sinuous, and shows very complex contortions, sending projections into the surrounding dense tissue. These sinuosities are followed, though not exactly, by depressions on the inner margin of the membrane. This peculiarly sinuous membrane has been described

[1] Gowers, 'Diseases of the Nervous System,' vol. i, p. 434, Lond., 1886.

[2] Bruhl, 'Contribution à l'étude de la Syringomyelie,' p. 97, Paris, 1890; Taylor, 'Trans. Path. Soc., Lond.,' vol. xxix, p. 23.

Digitized by Google

by several observers, amongst others especially by Dr. Harris,[1] who refers to it as being "shirt frill" like in character.

On teasing out this dense tissue it is found to consist of small distinctly nucleated cells, possessing numerous fine processes, which interlace with each other in a very complex manner. These cells resemble exactly the cells of the neuroglia, and the tissue is thus obviously a dense mass of the normal sustentacular tissue of the cord. The dense layers of the lining membrane are made up of branched neuroglia-cells quite similar to those of the surrounding less dense portions of the growth.

The external margin of this mass of neuroglia is not distinctly marked off from the surrounding cord substance, but fades gradually into the surrounding neuroglia.

The growth is well supplied with vessels. These are most numerous at the outer margin, but many sections of vessels are seen in the growth itself, and at the inner margin, where they are found especially in those portions of the lining membrane which are most contorted. The vessels are peculiar in having very much thickened external coats.

The case is obviously one of true syringomyelus, in contra-distinction to hydromyelus, though in this connection it is worthy of notice that the lateral ventricles of the brain were dilated, while there was no dilatation of the central canal of the cord. The occurrence of dilatation of the cerebral ventricles, along with the formation of cavities in the cord, apart from the central canal, seems not an unfrequent occurrence, and has already been brought under the notice of the Society by Dr. Turner,[2] in connection with a case described by him.

In regard to the origin of the cavities in the present case, there seems little doubt that the primary lesion is the formation of an abnormal mass of neuroglia in the posterior regions of the cord. Probably this is of developmental origin, and is a remnant of the neuroglia which primarily filled up the posterior extension of the original central canal of the cord. This may have originally surrounded a portion of the posterior extension of the central canal, and thus formed the origin of the cavity found in the cord after death, though the non-existence of a lining epithelium may be considered to militate against this view. It is possible, however,

[1] Thomas Harris, 'Brain,' vol. viii, 1886, pp. 466, 467.

[2] F. C. Turner, 'Trans. Path. Soc. Lond.,' vol. xxxix, p. 14.

Digitized by Google

that after the obliteration of this posterior extension of the central canal with its epithelium, that the neuroglia of the enlarging posterior columns had on meeting enclosed a cavity which elongated along with the general increase in length of the cord, and so gave origin to the cavity observed in this case. The more usually accepted explanation that the cavity forms in the rod of neuroglia by a process of liquefaction and absorption of the central parts must be accepted with caution, when the vascular nature of the growth is kept in mind, and also that the cells, even at the margin of the cavity, are healthy and show no signs of degeneration. An exception to this latter proposition, however, is evidenced in the mid-dorsal region of the present case, where the cavity is extensive and involves the grey matter of the cornea. Here, probably, part of the cavity is due to a form of myelitis involving the grey substance, and leading to its liquefaction and absorption. The formation of cavities in the cord owing to the absorption of portions degenerated on account of preceding myelitis is not uncommon, an example of which is furnished by Mr. Silcock's case reported to the Society,[1] and of which other examples have come under our observation.

The increased interest which has been taken in France has been developed from the clinical aspect, and owing to the possibility of diagnosis of this condition. The peculiar mental condition of this patient unfortunately vitiates the clinical observations; and we would only draw attention to the fact that the peripheral irritation which caused so much injury to be self-inflicted in this case may not have been the outcome of delusions merely, but have had its pathological explanation in some of the disturbances of sensation which seem more or less characteristic of syringomyelus. The occurrence of syringomyelus along with general paralysis has already been noted by other observers.[2]

I am sorry that the case is rendered incomplete by the want of a more thorough examination of the brain, which did not come into my possession.

In conclusion, I must record my obligation to my friends, Dr. Will, Medical Superintendent of Bethnal House Asylum, for liberty to report the case, and especially to the late Dr.

[1] A. Quarry Silcock, 'Trans. Path. Soc. Lond.,' vol. xxxix, p. 18.

[2] Fürstner and Zacher, 'Archiv f. Psychiatrie,' T. xiv, 1883 (quoted by Bruhl).

Digitized by Google

McKinnon, who handed over the specimen to my keeping, along with a copy of the clinical records.

I have made no attempt to add a bibliography of the subject, as a very complete enumeration of works is appended to Dr. Bruhl's treatise. An interesting clinical case has, however, been recently reported by Professor Charcot, dealing with the symptoms of an obscure case of nervous disease which he believes to be syringomyelus.[1]

March 17*th*, 1891.

[1] Charcot, 'Le Progrès Médical,' pp. 72—76, Jan. 24th, 1891.

Digitized by Google

II. DISEASES, ETC., OF THE ORGANS OF RESPIRATION.

1. *Ulceration just below right vocal cord followed by subcutaneous emphysema.*

By H. Montague Murray, M.D.

V. S—, a thin, wasted infant, aged 13 months, was admitted into Charing Cross Hospital under the care of Dr. Bruce. There was a history of phthisis on the mother's side. No clear evidence of syphilis could be obtained. The child was one of twins. For the first four months of life she was breast fed, and with the exception of a cough, which had always been present, appeared quite healthy until five months old. Then wasting and chronic diarrhœa set in and persisted until death. For these the child was brought to the hospital and admitted on October 7th, 1890.

Six days elapsed between admission and death. During this time it was noted: that the child had rickets; that its temperature varied between 99° F. and 104° F., its pulse between 120 and 160, and respirations between 44 and 72; that there was an occasional weak cough, aggravated during feeding, and physical signs of broncho-pneumonia; that the stools were frequent—six a day—but, as a rule, normal in colour and consistence; and, finally, that there was slight iritis (left) with a small corneal ulcer.

Twelve hours before death subcutaneous emphysema was observed in the neck. It extended from the lower jaw to the clavicles, and was especially marked on the right side and in the episternal notch. Six hours later, after an attack of coughing, it made its appearance in the right cheek, forming a localised prominence as large as half a hen's egg. No further extension was noted.

Digitized by Google

At the *post-mortem* examination a sharply cut circular ulcer (a third of an inch in diameter) was found just below the posterior termination of the right vocal cord. A probe could be passed downwards for nearly half an inch, where it struck the cricoid cartilage, which itself seemed free from disease. The subcutaneous emphysema occupied the position before described, with the exception of that in the cheek, which had disappeared.

The lungs were tough, and the bronchial tubes uniformly dilated. Excepting a layer (a third of an inch thick) at the surface, the whole of both organs was studded with pneumonic patches. The pleural surfaces were quite normal, and the lungs were of average size.

Besides a few crateriform ulcers in the colon, an unusually tough spleen, and rickety changes in the bones, no other abnormal appearances were noted.

In the ninth volume of this Society's 'Transactions' a very similar sequence is recorded by Dr. Wilks. The patient was a boy of twelve suffering from typhoid. The ulcer was at the posterior part of the left vocal cord, and was connected with a small abscess cavity between the trachea and œsophagus. The only other case with which I am acquainted is one reported by Von Ziemssen in his 'Cyclopædia.' His patient was a girl, aged four, but also suffering from typhoid. The ulcer occupied a very similar position.

The mechanism by which air might be driven through the floor of the ulcer during coughing can be readily understood, though it should be remembered that while the patient was under observation the cough was very slight. Indeed, were ulcers in such a position commoner occurrences, and the rima capable of complete closure, it seems probable that general emphysema would frequently be found present. The etiology of the ulceration is in this case more difficult to determine. The child had not suffered from any acute illness, and the appearances were characteristic neither of syphilis nor tubercle. No tubercle-bacilli could be found in scrapings from the floor of the ulcer.

November 18*th*, 1890.

Digitized by Google

2. *Extreme leprosy of larynx necessitating tracheotomy.* (*Card specimen.*)

By Dr. Bevan Rake.

R. D—, aged 34, white, was admitted to the Trinidad Leper Asylum on December 3rd, 1886, with mixed leprosy of ten years' duration. The larynx gradually became involved, and tracheotomy was performed for urgent dyspnœa on April 16th, 1890. The breathing became quiet, and his voice improved greatly after the operation. Several cervical glands suppurated, and ulceration and gangrene began in the extremeties. He died on August 6th, 1890.

Necropsy showed thickening and ulceration of epiglottis, ary-epiglottic folds, vocal cords, and mucous membrane below cord. Tracheotomy incision half inch long and one and a half inches below cords.

Pleura adherent. Both lungs stuffed with grey tubercles. These were beginning to break down at right apex. Liver cirrhotic. Spleen 21 oz., simple hypertrophy. Kidneys 14 oz., lardaceous. Median nerves much thickened above wrists. Numerous bacilli in spleen, liver, kidney, femoral gland. *October* 21*st*, 1890.

---

3. *Anomalous tumour of the larynx.*

By Felix Semon, M.D., and Samuel G. Shattock.

The clinical portion of the following paper is by Dr. Semon, the description of the specimen by Mr. Shattock.

On April 4th, 1891, I was consulted by Mr. W. C—, of Brighton, aged 44, who brought me a letter from Dr. M. Malbranc, of Naples, of March 25th of this year. In this letter Dr. Malbranc stated

Digitized by Google

that Mr. C— had been suffering for ten weeks past from a pricking sensation and a feeling of a foreign body in his throat; that he had found a bluish, more or less dark, tumour, with a rather smooth, mammillated surface, floating on the posterior surface of the left arytænoid cartilage, and that this tumour seemed to consist of an erectile tissue, because it changed colour and size, from a pea to a mulberry. Its origin was apparently from below the Wrisberg cartilage. Dr. Malbranc had had a consultation with Professor Massei, of Naples, who, after previous cocainisation, found the root of the tumour in the left pyriform sinus, in the same position in which once a similar tumour had been described by Sir Morell Mackenzie. The joint opinion of both gentlemen was that this tumour presented the characteristics of an angioma, possibly of ancient date but of recent development. As Mr. C— could not stay at Naples to have it removed, they had recommend him to me for that purpose.

On examination I found the description given by Dr. Malbranc fully to be in accord with the facts. A bluish mammillated tumour of a rather angry look and of the size of a mulberry obscured the view of the left half of the larynx, hanging over from the pyriform sinus into the interior of the larynx. The growth was distinctly pedunculated, and exploration with a probe under cocaine showed it to spring from the epiglottidean end of the left arytæno-epiglottidean fold. The voice was unchanged, and there was no dyspnœa, though Mr. C — stated that he had occasionally choking sensations. There was no enlargement of glands in the neck, and no evidence of malignancy. In short, I entirely agreed, from what I had read in laryngeal text-books of that extremely rare form of laryngeal tumour, angioma, but of which I had never seen an instance, that the growth was in all probability of this character. The removal did not present any difficulties. After previous cocainisation I succeeded on the first attempt to pass the galvano-caustic loop round the base of the tumour and to snare it off close to the base, whilst the wire was heated to a dull red heat. There was no hæmorrhage, of which I had been rather apprehensive, and the removal was perfectly painless. The growth, indeed, originated with a rather broad peduncle from the end of the left arytæno-epiglottidean fold, close to the base of the epiglottis. The wound healed very quickly, and a few days after the operation even the seat of the former growth could no longer be made out.

Digitized by Google

Description of the tumour after preservation in alcohol.—A flattened spheroidal growth about 1·5 cm. in chief diameter. Its surface is quite smooth and blotched of a deep red colour.

In the macroscopic section is discernible a whiter portion having a lobulated or papillary superficial limit, but this is ensheathed by a reddish structureless substance, which forms everywhere the real surface of the tumour, and is mingled with the other constituent throughout the greater part of the section.

Histology.—The tumour is a papilloma encased within an extravasation of blood. The coagulum consists of a close meshwork of bright, delicate, hyaline strands of fibrin, holding red discs in its meshes, and abundantly strewn with leucocytes, which from their numbers are evidently corpuscles that have wandered from the vessels into the dead substance of the clot. The proper tissue of the tumour is remarkable for its delicacy, and in this resembles the papillomata of the bladder rather than those commonly met with in the air-passages.

It consists of lax connective tissue, arranged in long narrow subdivided processes, invested with epithelium, and separated by wide intervals, which are occupied with extravasated blood continuous with that covering the general surface. The clot is traceable far into the growth amongst the processes of the latter, but nowhere confused with them; and it exhibits no "organisation," *i.e.* it is nowhere traversed by granulation- or connective-tissue, and is everywhere separated from the new growth by the investing epithelium of the latter.

The epithelium is of the columnar kind; in some spots it is disposed in a single layer, whilst in others additional elements are interposed between the deeper ends of the columnar cells.

1. It is extremely rare to find a papilloma springing from the arytæno-epiglottidean fold, unless there be almost universal papillomatous disease of the laryngeal mucous membrane. In the large number of papillomata of the larynx which I (F. S.) have seen, I have never come across a solitary papilloma in a similar situation.

2. The occurrence of spontaneous hæmorrhage from a laryngeal papilloma is, so far as our experience and knowledge of laryngological literature goes, unique. Although analogous growths in the bladder regularly give rise to spontaneous hæmorrhage, no single instance of a similar occurrence in the larynx has to our knowledge ever been described.

Digitized by Google

3. The formation of a complete casing of blood-clot about a papilloma so changing its clinical character and simulating the appearance of an angioma is equally unique, and will have to be kept in view by future observers. *May 19th*, 1891.

---

4. *Fibroid polypus of the trachea.*

By Leonard A. Bidwell.

J. B—, a well-nourished child, 5 years of age, was admitted into the Evelina Hospital on February 13th, 1890, under Dr. Tirard, to whom I am indebted for permission to publish the case. There was nothing of importance in the previous or family histories. A fortnight before admission the child suffered from paroxysmal fits of coughing after swallowing, with pain referred to the epigastric notch. Since February 10th the child had attacks of dyspnœa, with intervals of quiet breathing.

When admitted the child was a good colour, the temperature 97° F., the pulse good, and there was no difficulty in swallowing, or sore throat. There was a frequent and croupy cough, and the breathing became distressed after fits of coughing. The fauces were slightly injected, and the tonsils were enlarged, but no diphtheritic membrane was seen. There was some sucking in of the lower ribs. The other organs were healthy.

On February 14th the following note was made:—The child slept well without dyspnœa, but the cough is still frequent and croupy. At noon the respirations become much more embarrassed; there was considerable sucking-in of the lower ribs with orthopnœa; the larynx was moving up and down. Tracheotomy was then performed without the dyspnœa, which was chiefly inspiratory, being relieved. No false membrane was coughed up, but there was constant expectoration of blood-stained mucus, and marked stridor. The tube was frequently changed without affording any relief.

On February 15th the child seemed much the same, the dyspnœa

Digitized by Google

and frequent blood-stained expectoration continued, and the face became cyanosed at times.

The child was put under chloroform and a probe passed down the trachea without striking any foreign body. The breathing gradually become more distressed, the child frequently complained of pain in the chest, and died early the following morning.

A *post-mortem* examination was made forty hours after death. The body was well nourished; rigor mortis was absent. There was a wound an inch and a half long in the middle line of the neck, opening the trachea just below the thyroid cartilage.

The heart was enlarged, the right side being much dilated, and filled with decolorised clot, which also partially filled both ventricles.

The mucous membrane of the larynx was slightly swollen and the vessels injected.

On opening the trachea from behind some thick mucous was found, and its calibre was apparently completely blocked up by a globular polypus, the size of a small marble, which was attached by a distinct peduncle to the posterior wall opposite the eighth and ninth cartilaginous rings, at a point two and a half inches from the cricoid cartilage and one and a quarter inches above the bifurcation. There was some ulceration of the mucous membrane of the trachea opposite the polypus.

On microscopic examination the growth was found to consist of fibrous and cellular elements, without any definite evidence of sarcomatous tissue, although in parts some of the cells appear to be becoming spindle-shaped. It must, therefore, be considered a fibroma. The other organs were healthy, except that the bronchi contained a little muco-purulent frothy fluid, and the lungs appeared over-distended.

Polypi attached to the trachea are of very rare occurrence; one other case has been brought before this Society by Sir M. Mackenzie.[1] That, however, was a case of papilloma which had recurred in the trachea after having been removed from the larynx. No case of pedunculated fibroid polypus has, I believe, been shown here. Dr. Solis Cohen[2] has collected forty-five cases of polypi of the trachea, but of these only about sixteen were fibromata or fibro-sarcomata; most of the other cases being due to tubercle.

[1] 'Path. Trans.,' vol. xxv, p. 39.

[2] Ashurst, 'Encyclopædia,' 1885, p. 143.

Digitized by Google

Most of Dr. Solis Cohen's cases were only discovered at the *post-mortem* examination, as in my case. The commonest point of attachment is at the upper part of the trachea. Fibromata are more common than any other true tumour, but lipomata, adenomata, and cystomata are recorded.

They are much rarer in children than in adults. If I might mention a clinical point, I would add that no laryngoscopic examination was possible owing to the enlargement of the tonsils. The short duration of the symptoms, namely, only fourteen days, is also worthy of note. *November 4th*, 1890.

---

5. *Complete rupture of right bronchus.* (*Card specimen.*)

By H. D. Rolleston.

There is complete rupture of the right bronchus, just below the bifurcation of the trachea. The solution of continuity is irregular, anteriorly there is about $\frac{1}{8}$ of an inch of the bronchus left in continuity with the trachea, while posteriorly the rupture extends into the trachea. The pulmonary artery and veins were severed The lung was attached to the proximal end of the bronchus and trachea by some bruised connective tissue. From a soldier who was run over by a road car, and who sustained also fracture of the first five ribs of the right side and of the second to ninth inclusive on the left, as well as fracture of the dorsal spine.

The accident is a rare one. Mr. Shield recorded a case of complete rupture of the left bronchus, in vol. xl of the 'Pathological Transactions,' and I have met with a case[1] not previously published, in a man run over by a train, whose thorax was very extensively fractured; both the bronchi were sharply cut across close to the bifurcation of the trachea. *February 17th*, 1891.

[1] Vide this volume (Series III, No. 1).

Digitized by Google

6. *Case of plastic bronchitis.*

By Samuel West, M.D.

John C—, aged 23, a soldier in the Artillery, had been under Mr. Batson's care in Dorking since the end of January, and for the last three months and a half had been spitting up casts of his bronchial tubes. I had the opportunity of seeing him in the early part of May.

He gave the following history:—He was one of three children, his brother and sister being living and well. His mother died when he was very young, and he cannot say of what disease. His father died at 60, having suffered from bronchitis in his later years. He himself had been always well and strong, and had had no special illness. He entered the army in 1884, and was only once on the sick list, in the winter of 1889, for a little tightness on the chest and difficulty in breathing. Though there is no definite name given to this attack, he was on the sick list for five weeks. He got quite well and remained well till he was seized with influenza in Ireland in January, 1890. He was in hospital from January the 7th to the 11th, and had on the first day a temperature of 102·9°, but the next day it was 99°, and then became normal.

On January the 11th he was back on duty and felt quite well. On January 21st he went on furlough, had a very rough passage across the channel, and got very wet. He never felt quite himself after that, and found it necessary to consult Mr. Batson at Dorking on January 31st for a troublesome cough and some pain in the right side, from which he had suffered for three or four days before consulting him.

Mr. Batson found him looking ill, but with no fever. No physical signs could be detected in his chest, except some fine crepitation at its right base. The percussion was a little flat but not dull, and the vocal vibration and vocal resonance not altered. The diagnosis was made of congestion of the base of the right lung. This part was well poulticed and counter-irritated, but no definite change occurred in the condition, the crepitation still persisting.

The patient felt languid, weak, and ill, and remained in bed

Digitized by Google

almost entirely for a month. During this time he expectorated some viscid mucus in no large quantity.

At the end of February he spat up his first cast. He feels sure that he had never expectorated anything of the kind before; both he and his sister were struck with its peculiar appearance, and thought it to be a piece of an orange he had eaten. It was saved for Mr. Batson and shown to him. It came up without any paroxysm of dyspnœa or special effort.

From this time till seen by me on May 12th the patient has continued to bring up the casts, generally five or six in a day. At first they were smaller and more numerous, about one sixteenth of an inch in the stalk. Latterly, they have become a good deal larger but fewer. They now measure about one fourth of an inch in stalk. On one or two occasions, certainly not exceeding six times in all, an interval of four or five days has elapsed during which no cast has been expectorated at all.

Hæmoptysis has been absent, except that on one or two occasions a little streak of bright blood fringed the cast.

The patient has never had any attack of severe dyspnœa; at the most only a feeling of tightness of the chest and discomfort in breathing.

The difficulty in breathing has usually been worst at night. The casts have, however, not usually been expectorated until the morning, nor has the difficulty in breathing lasted all the night, though the patient volunteered the statement that he was worse in bed, and that when he was able to get up he had less difficulty in breathing and expectorated fewer casts.

No bronchitic expectoration has been present at any time, nothing was brought up but the casts. I saw some myself which had been expectorated that day, and no fluid was in the vessel except a small amount of saliva.

The general condition of the patient offers nothing to note. He had lost flesh a little during his illness, but not much; had never suffered from night or sleep sweats, or from shivering, and his cough had not at any time been very severe.

He had never been abroad, had never had ague, had suffered once from a subacute gonorrhœa, but never from syphilis.

Condition on May 12th, 1890.—Patient looked pale and somewhat anæmic, yet not specially ill, nor was he particularly thin.

The pulse was of good tension and power. The appetite good,

Digitized by Google

the tongue clean, and bowels regular. The urine natural. The temperature normal. The respirations were a little accelerated. The cardiac dulness natural, and the action healthy. The liver was in its normal position.

The left side of the chest presented normal physical signs all over back and front, except for a little occasional crepitation of a very fine character at the lowest part of the back, probably due to his lying in bed.

On the right side in front the shape and movements were normal, and the percussion normal, except that there appeared to be a little hyper-resonance below the right nipple.

The vocal resonance and vocal vibrations beneath the clavicle down to the second space were somewhat increased. Inspiration was also lengthened and a little too loud, but expiration was hardly audible in the first space, but in the second space was distinctly heard.

Below the third rib in front the vocal vibration, voice, and breath-sounds became diminished, and the air entered here, as also in the axilla, very imperfectly, and from the nipple line to the posterior axillary line on this level a sound was heard which resembled most of all a dry leather creak, but which seemed to me to be probably of pulmonary rather than pleuritic origin.

Posteriorly the percussion was impaired though not dull from the top to the bottom.

In the supra-spinous fossæ the vocal vibration and vocal resonance were still more increased than front, yet though the breath-sounds were louder than natural and expirations were slightly heard, still nothing amounting to bronchial breathing was present.

Below the level of the middle of the scapulæ the vocal vibrations and resonance became rapidly diminished as well as the breath-sounds, while at the base all were absent, and nothing was heard except some fine crepitation, which was increased on deep inspirations.

The physical signs pointed to obstruction to the tubes of the lower part of the right lung, which it was fair to conclude was the seat of formation of the casts.

The patient had been placed upon a variety of remedies, which, however, had not seemed to have an effect upon the disease, and it was now decided to try the effect of full doses of iodide of potassium.

Digitized by Google

The casts exhibited which Mr. Batson gave me were some of those which had been expectorated during the two days preceding my visit.

From this time, May 12th, the patient gradually improved, but continued to spit up casts, though less and less frequently, until the end of June. At that date the last was seen, and since then the patient has continued in good health. He did not return to the army, having got his discharge during his illness, but has since earned his livelihood as a labourer at and about Dorking, where he has from time to time been seen by Mr. Batson, though not on account of ill-health.

---

7. *Gangrene of lung secondary to bronchiectasis.*

By G. Newton Pitt.

A dense fibroid lung with large bronchiectatic cavities. In the upper lobe the tissue is shreddy and gangrenous. At the inspection the cavities were full of the necrotic lung-tissue, such as is now in the bottle, and this had also gravitated into the lower lobe.

From a young man who died in a septic condition soon after admission. A history of chronic lung disease with the physical signs of consolidation and of cavities.

---

8. *Tuberculosis of the lung arising from tuberculosis of the bronchial glands.*

By Arthur Francis Voelcker, M.D.

The cases I have the honour of bringing before the Society to-night illustrate some of the effects which caseous bronchial glands may produce by invading the lungs. The cases have all occurred at the Hospital for Sick Children, Great Ormond Street,

Digitized by Google

and I am indebted to Dr. Sturges and Dr. Barlow for their kindness in allowing me to make use of their cases.

Case 1.—E. B—, 10 months old, was admitted under Dr. Sturges with a history of wasting and diarrhœa for the previous two months. There was a strong tubercular history in both patients, and for seven months the child had been constantly with his father, who was dying from phthisis.

He died two days after admission, and at the autopsy there was found a large mass of caseous glands spreading from above around the left bronchus.

On removal there is seen to be a large cavity in the otherwise dark purple and solid left upper lobe. This cavity has been sealed externally by pleuritic adhesions. It would contain a large walnut. The walls are smooth, and the posterior and inner portion is covered with a yellow caseous material. This can be traced directly to the caseous glands at the root of the left lung, and the cavity has evidently originated from the softening of caseous matter produced by the invasion of the lung-tissue by the caseous gland. The rest of the lobe is studded with small caseating tubercles. The right upper lobe showed a few small cavities at the apex, but no large caseous masses. There was no ulceration into the trachea or bronchi detected One small caseous mass was found in the spleen, and numerous small tubercular ulcers were found in the small intestine, and a few in the upper part of larger intestine. Some caseous nodules were found in the mesenteric glands.

Case 2.—G. L—, aged 1 year and 7 months, was admitted under Dr. Sturges with a history of wasting for over a year, and of convulsions on the day of admission. There was no family history of tubercle.

At the autopsy there was found tubercular meningitis and general tuberculosis. Numerous caseous glands extend from the neck into the thorax. The right lung is firmly adherent, and on removal a rupture takes place in the lower lobe, from which about a drachm of pus escaped. On section there is seen to be a cavity in the lower lobe, which is ragged and contains breaking-down caseous matter, which is in direct continuity with caseous nodular masses which extend from the root of the lung in between the lobes of the lung. The rest of the lung is riddled with tubercle, but there is no other breaking down. The glands at the bifurcation of the

Digitized by Google

trachea are continuous with those at the root of the right lung, and are large and caseous. There is a perforation of the trachea just above its bifurcation. Numerous tubercles are found in the left lung, but no excavation.

The next case illustrates how localised the results of ulceration of a bronchial gland into a bronchus may be.

CASE 3.—F. C—, aged 1 year and 11 months, was admitted under Dr. Barlow for vomiting, wasting, and cough. She had had measles four months ago, and had been ailing since. There was a history of phthisis on the father's side. At the autopsy the lungs were not adherent. The right middle lobe is converted into a firm pale caseous mass, which is adherent to the pericardium. On section it is seen to be the seat of caseous tubercle. There is a cavity the size of a hazel-nut in which a large firm caseous mass surrounded by pus is found. The caseation of the lobe is seen to be due to more or less rounded areas in which a central depression (bronchus) can be seen; no trace of spongy lung tissue can be made out. The bronchial glands are caseous, especially on the right side, and on the slitting up the trachea and bronchi a perforation 1 cm. long is found in the right bronchus, and a little above it is also a small perforation. Both lead down to a cavity extending along the anterior surface of the right bronchus. The cavity is smooth; there is a caseous gland behind the right bronchus, but it has not softened. A probe passed through the perforation can be passed right down into the solid right middle lobe, and made to emerge in the cavity or through a bronchus in the midst of a caseous mass; thus it appears that a gland has ruptured into the right bronchus, and leaving its capsule, has set up a tubercular caseous peribronchitis in the middle lobe.

Remarks.—The direct invasion of the lung by caseating bronchial glands is not very common, although caseous glands are frequently found reaching for some distance into the lung, but here they are generally merely the glands which are normally found at the bifurcations of the bronchi and which have become caseous. In the cases I have read, however, we have to deal with actual destruction of lung tissue, and not merely with the additional presence of enlarged and caseous glands.

No one who has made many *post-mortem* examinations of children can fail to have been struck with the frequency of the occurrence of caseous glands at the roots of the lungs. In the

Digitized by Google

last 300 *post-mortems* I have made on children I have found caseous bronchial glands in no fewer than 110 cases. In only eight of these cases was no tubercle found in the lungs, and of these eight one was in a case of tubercular peritonitis, one of hip disease, one a case in which calcareous glands were found in the neck, two were cases of diphtheria, in two others the lungs could not be properly examined, being required to demonstrate other points, and in the eighth case the gland is described as presenting a few small caseous points. Although much has been said of the occurrence of caseous glands after measles and whooping-cough, I should like to ask those who have had greater experience whether they have often, or even ever, met with caseous bronchial glands apart from any evidence of tubercle in the lungs, or some other organ; as my limited experience, as I have just mentioned, is in favour of regarding the existence of caseous bronchial glands as an evidence of the existence of tuberculosis. Of course it may be urged that the cases I have mentioned are merely examples of primary mischief in the lungs with secondary involvement of the bronchial glands; and while I believe that this is the case in so far as the production of the glands is concerned, yet I think the destruction of lung tissue is due to the local effects produced by the glands; and for these reasons: caseous bronchial glands are met with apart from any caseous processes in the lungs. The excavation in the first case is most marked in the parts in immediate relation to the caseous gland. In the second case, where a cavity existed in the lower lobe, we have an unusual position for a primary lesion, and we have the continuous caseous tract from the walls of the cavity to the enlarged pulmonary and the bronchial glands, and in the third case we have a single lobe of the lung rendered entirely caseous; and it seems more rational to find in the rupture of the caseous gland into the bronchus, and the subsequent infection of the whole middle lobe with a peribronchial caseous tuberculosis, an explanation of what has happened, than to imagine the caseation of the lung to be primary, the ulceration of the gland to be of later occurrence. It is striking that all three cases occurred in children under two years of age.

May 5th, 1891.

Digitized by Google

9. *Necrosed pulmonary tissue and exudation becoming tubercular.* (*Card specimen.*)

By Sheridan Delépine.

The section exhibited was obtained from the lower part of the upper lobe of the left lung of a drunkard. It shows side by side the nearly healthy tissue composing the greater part of that lobe and the infarcted necrosed portion which has become invaded by the bacillus tuberculosis. The block was a large one, measuring about two inches by one, and was sharply defined from the surrounding tissues, and distinctly visible through the pleura. It gave one the impression that there must have been in that region some hæmorrhage, and that the blood had slowly degenerated, the surrounding tissue providing a fibrous capsule for it. The indurated patch is composed of granulo-fatty *débris* and fibrinous material, filling up the alveoli in many of the vessels. Many of the interlobular septa and alveolar walls are thickened, but there are no indications of any true pneumonic process having existed previously in that region. The necrosed intra-alveolar products and alveolar walls contain large numbers of bacilli of tuberculosis and other micro-organisms. The surrounding parts, *i. e.* those neither consolidated nor necrosed, do not contain any bacillus. The case is interesting in showing the influence which necrosis may have on the spread of tuberculosis. *November* 18*th*, 1890.

---

10. *Gumma of lung.*

By H. D. Rolleston.

The specimen shows a section of the right lung in the long axis of the body in the neighbourhood of the root. There is a localised thickening of the pleura, one eighth of an inch thick, situated over the upper part of the lower lobe posteriorly, and close

Digitized by Google

to the spine. The two layers of the pleura were here firmly adherent. The interlobular septum is much thickened. Corresponding to the thickened pleura there is an area of lung tissue which is markedly fibrosed; bands of thick greyish fibrous tissue pass inwards from the pleura, and, joining with each other, form a firm meshwork. Situated in this fibrosed portion is a caseous mass as big as a marble; it is somewhat loose.

Taken from a man, aged 28 years, who died August 31st, 1890, under Dr. Dickinson's care in St. George's Hospital. At the *post-mortem*, in addition to the above, the following points were noticeable:

Lungs: No tubercle at apices. Left lung and pleural cavity normal. Bronchial glands normal.

Heart: 12 oz.; no hypertrophy of left ventricle.

Liver: Surface scarred from perihepatitis; large caseous gumma near portal fissure, with smaller ones in its neighbourhood, two or three being situated in the wall of the gall-bladder. Liver substance cirrhotic and lardaceous.

Spleen: 18 oz.; supra-renals, kidneys, 12 oz. each, and intestines lardaceous. Gummata in both testes. Left testis has thickened tunica vaginalis with old hydrocele.

Dr. Sheridan Delépine, Lecturer on Pathology to St. George's Hospital Medical School, has kindly furnished me with the following report on the microscopical appearance of the specimen.

Report by Dr. Delépine.—Two parts of the lung were examined microscopically. (i) One where the pleura and the interlobular septa were considerably thickened and densely fibrous, and where the intervening parenchyma was consolidated. (ii) Another part where the interlobular septa and peribronchial tissue were distinct, the intervening parenchyma being unconsolidated and rather emphysematous-looking. The nature of the interstitial changes was the same in both situations.

Pleura.—The membrane on the part examined measured one fifteenth to one eighth of an inch, being thickest in parts corresponding to the interlobular septa. The serous layer was more thickened than the subserous, but in many places the demarcation between the two was not clear. Both layers were replaced by a tolerably dense and very transparent connective tissue, composed of homogeneous-looking, wavy, fibrous bundles, separating spindle-shaped or stellate corpuscles. These cells were not very abundant,

Digitized by Google

but stained well. Vessels were large and abundant; some showed distinct traces of proliferation of their endothelium, and a few were surrounded by small round cells staining deeply. Several patches of similar lymphoid cells were found here and there independently of vessels. Some of these patches situated in the subserous layer were contained in lymphatic vessels.

The interlobular septa have the same characters as the pleura. Many of the vessels (older vessels), however, have a thickened intima; a few are obliterated, while many have around them one or two rather thick layers of elastic fibres.

The peribronchial tissue has the same appearance. The cartilages are, however, undergoing degeneration or fibrous metaplasia preceded by multiplication of cells and degeneration of the matrix.

The terminal bronchi are very difficult to recognise. Owing to a very considerable accumulation of lymphoid cells in their mucosa, and to desquamation of their epithelium, many of them are almost completely obstructed.

The larger bronchi show catarrhal proliferation of epithelium, congestion and small-cell infiltration of the mucosa, atrophy of the muscular fibres and cartilages, swelling of mucous glands, the acini of which are filled with many cells distended with clear mucus.

The alveolar walls are thickened almost universally; their elastic fibres are very distinct, and in places brittle. Here and there accumulations of lymphoid cells occur.

The alveolar cavities are almost all obliterated, either by great thickening of their walls or by the accumulation of cells in their cavity. Blood-corpuscles, lymphoid cells, large catarrhal cells, some full of carbon particles, others of blood-pigment, are found in various parts of the preparation.

The lesions found are—chronic interstitial pneumonia and proliferative pleuritis and peribronchitis, chondritis and perichondritis, chronic congestion and hæmorrhages, lymphanitis, small granulomata, bronchial stenosis, catarrhal bronchitis, great inflammation of glands of bronchi, catarrhal pneumonia, hæmorrhages, collapse and emphysema, slight anthracosis.

Of all these lesions the most striking are the patches of small lymphoid cells found in the pleura, interlobular septa, alveolar walls, and often alveolar cavity. Some of these patches are distinctly vascular, and differ much in appearance from tubercles. They do not contain any bacilli of tubercles.

Digitized by Google

For the following notes I am indebted to the courtesy of Dr. W. L. Dickinson, Medical Registrar to St. George's Hospital.

Past history.—C. T— contracted syphilis early in 1884. Under Mr. Holmes in the hospital in May, 1886, with syphilitic disease of testes and sores on the right elbow; readmitted in September, 1886, with same complaint; urine at this time natural. Readmitted May, 1887, with fractured leg. Urine sp. gr. 1006. Readmitted 1888 with pneumonia.

History of present illness.—Was able to work till June 4th, 1890, when on his legs beginning to swell he took to bed.

Admitted under Dr. Dickinson June 18th. Fairly well nourished, moderate amount of soft œdema of the legs, tongue clean and dry, temperature slightly raised; no cardiac abnormality; crepitation at bases of lungs, no ascites; liver tender, size and shape masked by the intestines. Urine high coloured, 1022—1031, acid, nearly solid with albumen; the average daily quantity was 80, but on some days as much as 105 oz. was passed. The œdema gradually lessened, and by the middle of July was considerably reduced. The man, however, was obviously losing ground, his bowels were loose, and he began to vomit; he died of uræmia. Two weeks before his death he developed a macular erythema, which rapidly faded with copious desquamation on stopping the (iodide of potassium) medicine he had been taking. *November 4th,* 1890.

---

11. *Diffuse syphilitic fibrosis of the lungs.*

By E. C. Perry.

Portion of a right lung in which there is a considerable increase of fibroid material, appearing on the cut surface as a delicate network traversing the pulmonary tissue in all directions. This fibroid change is less marked at the apex than at the base; in the latter situation the air-vesicles are many of them dilated. The pleura is slightly thickened, and was adherent. Histologically the dense fibroid tissue that pervades the lung shows scattered through it numerous collections of small round cells not under-

Digitized by Google

going caseation. No giant-cells are seen. The walls of the small arteries are thickened.

John A—, aged 54, was admitted into Guy's Hospital under Dr. Taylor, with severe dyspnœa of one week's duration, and bronchitis. He had suffered from winter cough for some years. At the autopsy the testes were fibroid, the liver was scarred, and the kidneys were lardaceous. The condition of the left lung was similar to that of the right.

Cf. Dr. Percy Kidd's case of "Diffuse Symmetrical Pulmonary Cirrhosis," 'Trans. Path. Soc.,' vol. xxxvii, p. 126.

November 11*th*, 1890.

---

12. *Myxo-sarcoma of lung.*

By H. D. Rolleston.

The left lung is occupied by a mass of new growth, the whole weighing 10 lbs. 7 oz. The growth occupies the lower lobe, replacing almost completely the lung substance. The upper lobe is compressed, disorganised, and towards its lower part infiltrated with new growth. In parts the growth is calcified. The growth projects into the cavity of the pericardium. The growth in parts is honeycombed—there are cysts containing gum-like fluid, which chemically contained albumen and mucin. Microscopically the growth was a myxo-sarcoma.

The bronchial glands were much enlarged and were occupied by new growth. There was a similar small growth on the eighth, ninth, and tenth ribs in the left hypochondrium. From a man, aged 33 years, paracentesis thoracis gave mucous fluid.

May 19*th*, 1891.

Digitized by Google

13. (1) *Primary carcinoma of lung.* (2) *Mediastinal glands from same case.*

By E. Lycett Burd, M.D.

From patient, aged 55, admitted to Salop Infirmary, August 30th, 1890, with right-sided pleurisy. Discharged much relieved September 20th, 1890. Readmitted October 6th with stitch, œdema of face, hands, arms, and chest, and considerable dyspnœa. Great enlargement of veins over shoulders and front of chest.

Slightly marked dulness on percussion over limited area in front on right side. No adventitious lung-sounds. No hæmoptysis. Died November 23rd.

Post mortem.—Upper lobe of right lung infiltrated with new growth. Mediastinum occupied by mass of carcinomatous gland tissue, adherent to pericardium, root of lung, œsophagus, and great vessels. Right bronchus occluded. *December 2nd*, 1890.

---

14. *Tuberculosis of the pleura.*

By E. C. Perry.

A section through a left lung, showing the visceral layer of the pleura and the interlobar septum universally thickened, in some places to the extent of one third of an inch. The surface presents delicate membranous adhesions, and in contact with it at the apex of the lung there are some caseous lymphatic glands. The pulmonary tissue contains miliary tubercles. Histologically the thickened pleura shows many caseous foci, crowded by the bacilli of tuberculosis.

George R—, aged 10, was admitted into Guy's Hospital under Dr. Goodhart for an abscess in the temporal region associated with caseous disease of the bone. Symptoms of bronchitis and pleurisy

Digitized by Google

developed soon after admission, and the patient died six months from the first onset of his illness. At the autopsy there was found extension of the caseous disease of the temporal bone to the subjacent dura mater, with general tuberculosis of the viscera. The right pleura was unaffected. *March 3rd*, 1891.

Digitized by Google

III. DISEASES, ETC., OF THE ORGANS OF CIRCULATION.

1. *Rupture of the heart and of the arch of the aorta.* (1) *One inch above the aortic valves.* (2) *At the junction of the transverse and descending parts of the arch.*

By H. D. Rolleston.

The specimen shows the heart, the arch, and thoracic aorta. There are two ruptures into the right ventricle, close to each other, to the right of the interventricular septum.

One inch above the upper limit of the semilunar valves the aorta is cleanly cut across, all connection being completely severed.

At the junction of the transverse and the descending parts of the arch of the aorta there is a second solution of continuity, the two segments of the vessel being connected by two delicate threads derived from the tunica adventitia.

From A. T—, aged 60, who was run over by an express train. The heart lay loose in the thoracic cavity, the pericardium being torn open; the heart lay transversely, its apex to the right. The left branch of the pulmonary artery was the only great vessel not cut across. The right lung lay quite unattached, and could be lifted out of the thorax. The left bronchus was sharply cut across close to the bifurcation of the trachea. The liver was ruptured.

Spine fractured at levels of (α) second dorsal, (β) fifth dorsal, (γ) seventh dorsal vertebræ. The third and fourth dorsal vertebræ completely dislocated forwards, the cord being quite cut across. All the ribs on both sides broken in at least two places.

Symphysis pubis separated for extent of half an inch. Right sacro-iliac joint loose and separated. *November 4th*, 1890.

Digitized by Google

2. *Simple atrophy of heart.*

By G. Gulliver, M.B.

The specimen was taken from the body of a woman, aged 28. Except for its small size, the organ is in all respects normal. Its weight is only 3¾ oz. The wasting affected not only the heart but the body, and nearly all the other organs. The body, which was entirely devoid of fat, weighed only 3 st. 10 lbs., although it was that of a woman of quite the average height. The right lung, which was œdematous, weighed 11½ oz., the left only 5½ oz. The liver was very flabby, and weighed only 1 lb. 14½ oz., the spleen 2 oz. The uterus was exceedingly small, and the coats of the intestines thin and translucent. The kidneys, which weighed 8 oz., and the brain, which weighed 41¾ oz., had escaped the general wasting.

There was no actual disease of any organ. The patient died after an illness of eight months' duration, the symptoms of which were diarrhœa, occasional vomiting and emaciation, with œdema of the legs, and a temperature never above and almost always below the normal. Although she was in St. Thomas's Hospital for five weeks before her death, and although the diarrhœa yielded in great measure to treatment, and the vomiting was never more than an occasional symptom, liquid food being taken and retained in considerable quantity, the emaciation and weakness progressed till the time of her death.

The condition of the heart and other organs seems in all respects to correspond with that found in cases of starvation.

November 18*th*, 1890.

Digitized by Google

3. *Tricuspid stenosis. Partial obstruction of right auriculo-ventricular opening by partly calcified and organised fibrinous vegetations. Localised fibrous thickening and calcification of endocardium of left auricle.*

By Sheridan Delépine.

The two auricles and the right ventricle being opened, the following lesions are evident.

The cusps of the tricuspid valve are thickened and partly calcified, and covered with dense fibrinous vegetations, which are almost entirely calcified (through infiltration with phosphate and carbonate of calcium which are in a crystalline form).

In *the left auricle* there is a fibrous ridge extending from a little above and behind the orifice of the auricular appendix, towards the posterior part of the cavity. This ridge is partly calcified.

(The vegetations have been examined for micro-organisms, but, owing to the necessity of decalcifying them, the results obtained have not been satisfactory.)

History.—The patient was a butler, aged 40. He was under the care of Mr. W. Bennett at St. George's Hospital. (The following abstract has been prepared from the notes of Mr. C. E. Cotes, the Surgical Registrar.)

Six years before death: hæmaturia. Treatment for stricture by catheterism. Recovery apparently good.

Six months before death: hæmaturia and rapid loss of flesh, but no night-sweat or cough.

Five weeks before death: *anal abscess*, which burst and healed well.

Three weeks before death: hæmaturia, passage of clots, admission into hospital. Patient was then very thin and anæmic, bladder distended, pain on micturition, pulse very rapid and small. Patient continued to lose blood, and gradually sank.

Remark.—Possible relation between the septic inflammation affecting the perinæal organs (and consequently veins) and the cardiac lesion. In this case the right side is affected. In valvular disease secondary to lung disease (pneumonia) the left is affected.

October 21*st*, 1890.

Digitized by Google

4. *Aneurysmal dilatation of wall of left ventricle.* (*Card specimen.*)

By G. Gulliver, M.B.

Heart taken from the body of a woman, aged 54. The organ generally is enlarged, but the left ventricle towards the apex and to the right is dilated so as to form an aneurysmal sac, over which the cardiac wall becomes thinner and thinner, so that at the apex of the sac there is no muscular tissue at all. At this point the two pericardial layers were adherent. When taken from the body the sac was filled with laminated clot.

November 18*th*, 1890.

---

5. *Aneurysm of heart.*

By J. A. Ormerod, M.D.

On opening the pericardium a pouch was seen projecting from the left side of the heart towards the left and slightly upwards. It was slightly adherent to the pericardium.

It consists of an aneurysmal bulging of the wall of the left ventricle, the size of an orange, originating from the left and upper part of the wall behind the *small* flap of the mitral. It contains much laminated clot. It is unruptured.

Except for slight dilatation of the cavities, the rest of the heart, including the valves, was normal.

The aorta was not atheromatous.

Liver and spleen large; kidneys large and hard. Otherwise all the viscera were normal.

The patient was brought to the hospital dead, having died suddenly while at work. His age was 35.

November 18*th*, 1890.

Digitized by Google

6. *Gummatous infiltration of the muscular wall of the heart, leading to aneurysmal pouching and rupture.*

By G. Newton Pitt, M.D.

A man, Richard W—, aged 28, was brought up dead to Guy's Hospital, with the statement that while he was trying to lift a heavy weight at his work he suddenly fell down, and very shortly died. But little further information could be obtained about him. He was living at a common lodging-house, and was under treatment for syphilis. He had complained of slight pain at his heart, but not sufficient to prevent him from doing heavy work.

Post-mortem inspection.—A well-developed man, with his face severely scarred from smallpox.

The heart weighed 16 oz. It had ruptured into the pericardial sac, which was tightly distended with 21 oz. of fluid and blood-clot, which had poured out from the heart. The enlargement of the heart was due to dilatation and hypertrophy of the left ventricle. A globular, gelatinous, gummatous mass, three quarters of an inch in diameter, projected on the outer surface of the wall of the right ventricle, pushing the visceral layer of the pericardium forwards, and causing it to adhere to the parietal layer. On section the wall was found to be free from infiltration, and as the fluid soon drained from the mass, it shrank up and almost disappeared.

On laying open the left ventricle it was found that there was very extensive gummatous infiltration of the inner portion of the wall; this yielding had led to the formation of a thin-walled sac, which presented a V-shaped rupture, each limb of which was three quarters of an inch long. These projected from the left and posterior portion of the apex of the heart; it communicated with the left ventricle by a small aperture, barely admitting the tip of a finger.

The gummatous growth extended over an area three inches vertically and one and a half transversely, occupying the posterior portion of the septum, and the adjacent portion of the posterior wall extending from the apex to the right musculus papillaris. Another

Digitized by Google

mass covered an area two inches by one, extending from the apex to the left musculus papillaris, which was enlarged into a mass the size of a thumb. On section, except at the apex, the gummatous material did not extend to the pericardial surface.

The tissue was soft, and almost of the consistence of jelly; none of it was suppurating, or actually fluid. In colour, the material was stone-grey; caseation had commenced at places, and round these there appeared to be a layer of cell infiltration. There is a general, irregular, fibroid degeneration of the whole of the ascending, and of the greater portion of the transverse aorta. The degeneration in the descending portion was much less, and consisted of only one patch.

The prepuce was indurated, swollen, and inflamed. When up, it was found to retain some purulent secretion, and on the inner surface there were two excoriations, one half an inch across, and the other smaller. The urethra was not strictured.

Both the testicles were markedly fibroid and dense. On the left side the tunica vaginalis was partially adherent, allowing only a small hydrocele; but on the right side there was a hydrocele containing about 2 oz. of fluid.

Microscopically.—The infiltrated cardiac muscle showed a dense cell aggregation running along the connective-tissue planes, in places replacing the cardiac muscle entirely. The muscle fibres in the least infiltrated parts show no degeneration, their striation being still present; they appear to play a purely passive part. The infiltrating cells are round, and none show any tendency to become fibroblasts. Their readiness to stain varies greatly; where degeneration has commenced all the cells stain badly.

The present is a beautiful example of an early gummatous infiltration of the heart muscle. This condition is uncommon, but it is still more rare to find an aneurysm developed. As in other examples, reparative changes leading to a fibroid degeneration have taken place. Dr. Goodhart described an almost identical case in the 'Transactions' of this Society in 1887, where he refers to two other cases recorded by Drs. Barlow and Sharkey.

The appearances are characteristic of syphilis, especially the gelatinous condition of the mass on the outer surface of the right ventricle. The collateral evidence in the form of a double fibroid condition of the testicles with hydrocele, and the extensive atheroma of the aorta in a young man, corroborate this view.

Digitized by Google

7. *Myocarditis limited to the right side of the heart.*

By H. D. Rolleston, M.B., M.R.C.P.

Myocarditis of a chronic type is said to attack more frequently the walls of the left ventricle and the septum ventriculorum than the auricle or the right ventricle. In the instance I am about to describe there was subacute myocarditis affecting almost exclusively the right auricle and ventricle.

The heart weighed 20 oz., the pericardium was adherent universally, but the adhesions over the right or anterior surface of the heart were both thicker and firmer than over the left.

The right auricle was dilated, the myocardium appeared thickened and of a pale yellowish colour, the endocardium was rather opaque. The tricuspid valve was widely dilated; its segments, however, were quite healthy. The right ventricle was dilated and hypertrophied.

The two layers of the adherent pericardium merged into the myocardium, which was profoundly altered. The myocardium was pale, slightly streaked, and flabby in appearance; it had lost the elasticity of healthy heart-muscle, and was brittle. The musculi papillaris were not markedly affected, and the chordæ tendineæ were fairly normal. The septum was very slightly affected.

Microscopically the myocardium in the affected area was altered in three ways: (1) fatty infiltration, (2) interstitial inflammation with production of young fibrous tissue, and (3) degeneration of the muscular tissue.

The fatty infiltration is considerable, layers of well-formed fat-cells intervening between muscular bundles. The fatty infiltration was probably antecedent to and independent of the inflammatory changes to be described.

There is well-marked interstitial inflammation, most marked underneath the pericardium; the muscular fibres are widely separated from each other, and the layers of fat-cells in many cases surrounded by exudation of recent origin and young developing fibrous tissue. The muscular fibres are almost absent from the outer part of the myocardium; elsewhere they are separated from each other as described above. They are smaller than natural, and

Digitized by Google

in many places, though not universally, have lost their transverse striation and appear granular.

The endocardium appeared normal. It was covered in the recent condition by a film of adherent decolourised clot. From this circumstance it may be conjectured that its nutrition had been somewhat impaired by the inflammation of the underlying myocardium; its blood-vessels, perhaps, being compressed by exudation.

The left auricle was dilated but not hypertrophied; its myocardium was of a reddish rosy pink, and contrasted forcibly with that of the right auricle.

The mitral orifice just admitted two fingers; its segments were united, thickened, and somewhat rigid; the valve was somewhat depressed towards the ventricle, and the chordæ tendineæ thickened.

The left ventricle was hypertrophied but not dilated. The aortic valves were healthy. The myocardium was of a good colour, and microscopically was quite healthy.

From a woman, aged 54 years, who died with pleural effusion under Dr. Whipham in St. George's Hospital. She had suffered from rheumatism, but had been in fair health until a short time before her death.

In this case the changes in the myocardium are to be considered as secondary to the inflammatory process between the layers of the pericardium. There had been a pericarditis of rheumatic origin, and as a result adhesion of the two layers of the pericardium. The adhesions were thicker and more marked on the anterior surface of the heart than on the posterior, thus suggesting that the two layers of the pericardium became united and adherent earlier in front than on the posterior surface of the heart. I have on several occasions noticed adhesions over the front of the heart when they are absent posteriorly, and in some cases, such as the present one, when the adhesions are universal, have found them thicker, and apparently therefore of older date, anteriorly.

This might be accounted for by supposing that in these cases the two surfaces of the pericardium have been kept apart posteriorly by effusion, while anteriorly they remain in contact, and so contract early and form adhesions.

If this be so, why should the effusion collect posteriorly? It may be that at the back of the heart, in the region of the reflexion of the pericardium, over the pulmonary veins and inferior vena cava (the great oblique sinus), the cohesion between the two layers

Digitized by Google

of the pericardium is weaker than elsewhere, and therefore gives in first in this situation, and that as a consequence the effusion collects here in preference to the rest of the pericardial sac.

May 19*th*, 1891.

---

8. *Patent foramen ovale in an adult.*

By W. B. Hadden.

The foramen ovale is quite patent, and measures three quarters of an inch in its long diameter. The septum around is thin, membranous, translucent, and devoid of muscular structure. The right ventricle was much dilated and hypertrophied, and the left auricle was very capacious. The mitral orifice was three and a half inches in circumference, and rather slit-like; the edge of the valve was thick and fibrous. The lungs were emphysematous and œdematous, and the lower half of the right lower lobe was collapsed. The patient was a woman of 60, who had had rheumatism several times since the age of twenty-two. She has been subject to bronchitis since she was twenty years of age.

On admission, she had the physical signs of bronchitis and emphysema, and there was general dropsy. The heart was feeble and very irregular, but no murmur was heard.

She died three days after admission.

February 17*th*, 1891.

---

9. *Communication between the ventricles of the heart—congenital.* (*Card specimen.*)

By H. D. Rolleston, M.B.

The communication between the ventricles passed through the upper part of the septum and just admitted a medium-sized probe.

The orifice in the left ventricle was rounded, its edges formed of

Digitized by Google

smoothed somewhat thickened endocardium. It was situated immediately below and in contact with the middle of the right lateral aortic segment. The "undefended space" was immediately posterior, so that this foramen is not a deficiency in the undefended space or pars membranacea septi. In front of the orifice there is thick myocardium, and behind it thickened endocardium, which latter separates it from the undefended space. The aortic cusp immediately above the orifice is not specially altered.

On the right side of the heart the orifice is somewhat triangular, with the base directed upwards; it is larger than in the left ventricle. It is situated three eighths of an inch below the left lateral pulmonary segment, and just above the origin of the posterior or fixed, and of the anterior cusps of the tricuspid valve. Its margins are formed of smooth endocardium more thickened than in the left ventricle. Its lower margin is crescentic with the concavity looking upwards and projects a little in front of the orifice, so as to form a partial valve, to the lower margin the fixed cusps of the tricuspid is attached. The upper margin is smooth. The orifice is as a whole slightly funnel-shaped. From the orifice a thickened condition of the endocardium spreads (i) up to the left lateral pulmonary segment, and (ii) outwards transversely; in the latter direction it fades away, and then terminates in a thick patch which was opposite the orifice, as in the case Dr. Coupland described in vol. xxx of 'Path. Trans.,' p. 266.

The foramen ovale was closed. The pulmonary valves were normal, except for thickening of the left lateral segment. The pulmonary artery was normal, and the ductus arteriosus was impervious.

There was no sign of ulceration about the communication, and it appears probable that it was congenital. Examples of deficiency of the septum without any gross malformation or stenosis of the pulmonary artery are recorded in the 'Transactions' of the Society by Dr. Hare (vol. i); Sir W. Jenner (vol. ii, p. 337); Dr. Wilks (vol. vi, p. 143); Dr. Hillier (vol. xii, p. 76); and Dr. S. Coupland (vol. xxx, p. 266). Dr. Wilks was inclined to regard his case as due to ulceration, the others were probably congenital. What is the cause of the septum being imperfect in this case it is not possible to say, but it is conceivable that just before the septum should have closed some temporary interference with the circulation through the ductus arteriosus occurred, which was sufficient to prevent the closure taking place at its normal time, and which then disappeared

Digitized by Google

without leaving any permanent record in the pulmonary artery or ductus arteriosus.

This specimen was taken from a boy, aged 11 years, who died in St. George's Hospital Nov. 20th, 1890. His mother and a maternal aunt had had rheumatic fever. He had been perfectly healthy till February, 1890, when he had rheumatic fever, from which, however, he recovered, and was quite well until October, 1890, when he had dropsy of the legs. He died with all the symptoms of advanced mitral regurgitation on November 20th.

Post-mortem.—The heart weighed 16 oz., the two layers of the pericardium were firmly united all over the heart, the tricuspid valve segments were normal, the right ventricle was dilated and hypertrophied, the left ventricle was hypertrophied and greatly dilated, the mitral valve was considerably thickened, its orifice but little larger than normal. The aortic valves were opaque. The lungs showed broncho-pneumonia, and at the left base there was a pulmonary apoplexy. It is probable that these extensive cardiac lesions resulted from the attack of rheumatic fever in February, 1890, and that the condition of the septum described above is of independent origin. *January 20th*, 1891.

---

10. *A heart with bifid apex.* (*Card specimen.*)

By Samuel G. Shattock.

The heart of an adult of which the apex is bifid. When placed with the septum vertically the apex of the left ventricle projects 1 cm. beyond the lower termination of the inter-ventricular septum; the apex of the right lies ·5 cm. below the same point. The ventricular cavities are fully prolonged into the subdivisions of the apex; the heart is otherwise perfectly normal.

Fissure of the apex is a condition of rare occurrence, and must undoubtedly be classed in its genuine form as a malformation.[1]

[1] Peacock ('Malformations of the Heart,' p. 141, 2nd edition) cites from Dr. John Paget ("On Congenital Malformations," 'Edinburgh Med. and Surg. Journal,' vol. xxxvi, p. 281, 1831) references to two examples only; he had never observed the condition himself. One of the cases is recorded by M. Parise in

Digitized by Google

For neither will a general enlargement of the heart lead to it, nor will dilatation and hypertrophy of either ventricle alone. The result brought about by dilatation of the right ventricle, for instance, is blunting of the cardiac apex; the dilated ventricle comes to take a share in the formation of the apex, or so surpasses the left as to form the proper apex in its stead. So, too, when the left ventricle is the subject of dilatation, its apex may project far beyond the right. But under none of these circumstances does a subdivision arise. In the fœtus at birth, at which time the ventricles are about equal in thickness, they combine to form the apex.

Protrusions of the myocardium may affect either ventricle as aneurysms due to fibroid substitution of the muscular tissue, &c., and were the walls of both ventricles concerned might conceivably lead to duplication of the apex.

But setting aside such possible spurious forms, fissure of the apex is a malformation which, like the chief part of malformations in general, is due to an untimely arrest in the normal gradus of

FIG. 6 *a*.

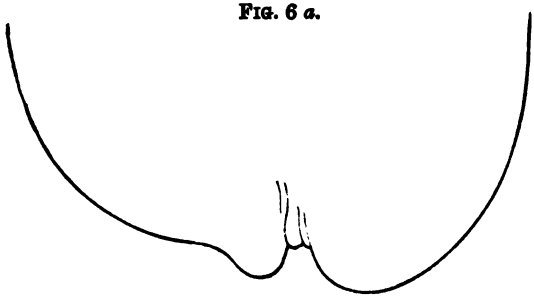

the 'Société Anatomique de Paris,' 1837, p. 100. The only report in the original is that the heart shown by M. Parise was found in a child, and that the fissure which divided the end of the organ was prolonged for a distance of two lines. The instance recorded by Bartholinus is to be found in the 'Historiarum Anatomicarum Rariorum,' centuria 1, hist. lxvii, cor bifidum. He cites it as having been related to him, but gives no measurements, though the fissure would not appear to have involved more than the apex—"Mucrone non acuto, ut fieri solet, sed bifido et distincti ventriculi menifestius externa facie apparuerint, dexter nempe, et sinister, interjecto hiatu."

There is in the Museum of St. Thomas's Hospital the heart of a fœtus at term showing well pronounced division of the apex without other malformation. The fissure has a depth of 3 mm.

Digitized by Google

FIG. 6 *b*.

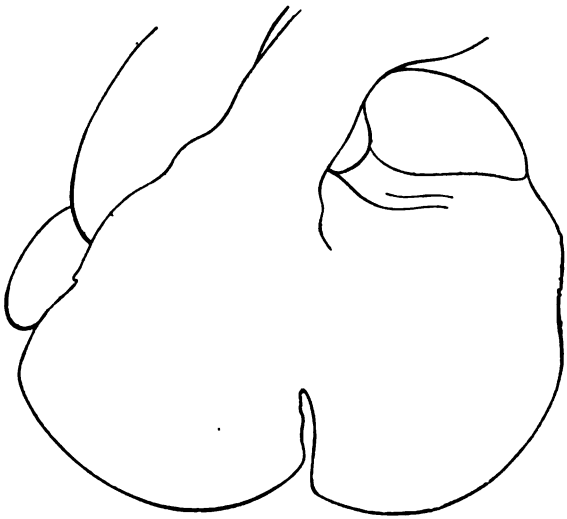

FIG. 6 *c*.

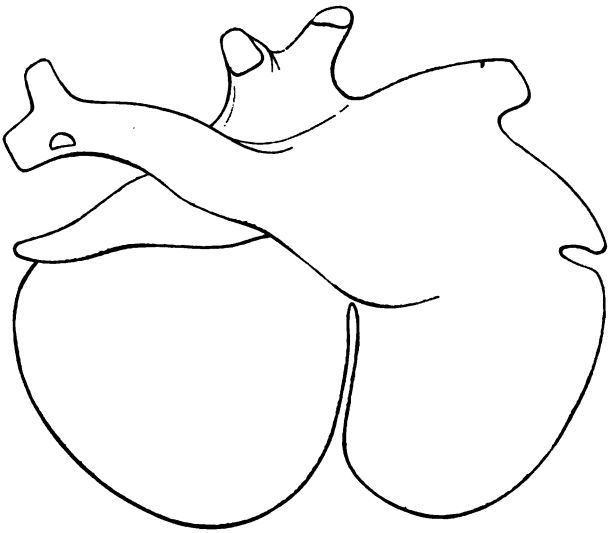

Fig. 6 *a* represents the apex of the human heart, described.

Fig. 6 *b* represents the heart of a Manatee in the Royal College of Surgeons' Museum.

Fig. 6 *c* represents the heart of a Dugong, viewed from behind, in the same Museum. All the figures are reduced to two-thirds of the natural size.

Digitized by Google

development; and it is interesting to observe that, like so many other such, it represents the permanent and normal condition in the adult of certain vertebrates.

As an adult condition it is limited, in any pronounced degree, to the aquatic Herbivora, the Sirenia—the dugong and manatee.

In the dugong the ventricles are quite distinct; the right is completely separated from the left by a cleft which reaches as far as the auriculo-ventricular orifices.

In the manatee the subdivision is confined to the apex, which it involves to a somewhat greater relative degree than in the specimen under notice. Amongst the Cetacea (whales and dolphins), it obtains to a slight extent in the porpoise; amongst the Pinnipedia, it is fairly well pronounced in the Greenland seal, but it is not constant amongst the seals and is absent in the walrus.

The condition is thus limited to mammals which are aquatic, though it is found only in a comparatively small number of such.

It will be remembered that the heart of mammals is primitively represented by two completely separate and not even contiguous tubes; these subsequently coalesce to produce a single median undivided cavity, the highest or most anterior portion of which is the aortic bulb, the next the ventricular, and the lowest or posterior the auricular segment of the heart and sinus venosus.

This simple tubular cavity becomes subsequently bent upon itself, whereby the auricular portion is brought into relation with the aortic bulb.

The permanent subdivision of ventricles and auricles into right and left is still later brought about by the ingrowths of inter-ventricular and inter-auricular septa, the growth of the inter-ventricular septum being associated with the appearance of an external groove, which remains evident in the heart of the adult when the muscular tissue is exposed by dissection.

The separation of the ventricles in the dugong, therefore, is most probably due to the persistence in the ventricular division of the heart of the primitive condition in which the organ is bitubular and its halves discontinuous.

The lesser grade of the same condition present in the manatee is best explained in the same way, and so, I should think, is the still lesser degree of subdivision shown in the specimen under notice. This would make fissure of the apex genetically like fissure of the lip; and the median form of the latter, in a similar

Digitized by Google

way, though a malformation in man is the normal conformation in Rodentia.

A complete independence of the ventricles as well as a complete community of their cavities, though conditions so opposed, are thus both results due to developmental arrest, but to arrest occurring at different periods in embryonic life. *May* 19th, 1891.

---

11. *Aortic aneurysm communicating with superior vena cava.*

By William Miller Ord, M.D.

C. B—, aged 43, police constable, was admitted into George Ward, St. Thomas's Hospital, on November 14th, 1890.

Family history.—This presented one interesting point, viz. that his father, an apparently healthy man, died suddenly of a fit of coughing.

Previous history.—The patient appears to have led a life of very hard work, beginning at eight years old. From the age of twelve onwards his work was for some time very laborious, consisting in occupation at a coal wharf. He served subsequently for six years in the Scots Guards, and as a police constable for thirteen years. He had typhoid fever when seventeen years old, and scarlet fever at the age of twenty-four. He presented no history of syphilis or intemperance,

Present illness.—About five months before admission he began to experience a pricking sensation in the right side of the chest, accompanied by difficulty in swallowing and inability to lie on the left side. He states that these conditions followed a violent attack of sneezing.

At the time of admission he complained of swelling of the right side of the neck and face, which had come on suddenly seven days before, of dysphagia, of dry cough, of inability to lie on the left side, and of occasional shooting pain in the right shoulder. His face was swollen, congested, and somewhat livid; the ears were distinctly livid. There was œdema of the right side of the neck and chest, with numerous turgid superficial veins. There was some swelling also of the left side of the neck. On inspecting the chest no tumour could be seen, nor was there any visible pulsation. On palpation pulsation was distinctly felt over the inner ends of

Digitized by Google

the second and third ribs on the right side. No thrill was felt. On percussion an area of dulness was defined, extending to the right from the middle line of the sternum, at a level corresponding above to the upper border of the second rib, below to the upper border of the fourth rib. The dulness was marked in the horizontal direction for three inches, beyond which point it gradually faded away. On auscultation a loud continuous humming murmur was heard over the dull area. Although never ceasing, the murmur varied in intensity, being more sonorous at the commencement of the cardiac systole, fainter during diastole. It was well conducted upwards into the neck on both sides, and was also heard over the whole of the right side of the chest posteriorly. The cardiac dulness had for its upper limit the fourth left costal cartilage, and on the right encroached very slightly on the sternum. The impulse was felt in the fifth interspace, just external to the nipple line; it was feeble. A musical systolic murmur was heard here, and was conducted into the axilla. This murmur appeared to be quite distinct from the continuous murmur over the pulsating area, there being an intervening tract where no pronounced murmur could be heard. The pulse at the wrist was equal on the two sides, full, and somewhat jerky. The arteries were thickened. The carotid pulses could not be felt. The lungs were resonant; a few rhonchi were heard at both bases. The liver dulness began, above, at the sixth rib in the nipple line, and the edge could be felt at the level of the umbilicus. No enlargement of the spleen could be detected. The urine was clear, high coloured, of sp. gr. 1029, and of acid reaction. It contained neither albumen, sugar, nor blood. There was no ascites or anasarca. The temperature was normal at the time of admission, and remained normal.

For some days after admission the patient appeared to improve, the dysphagia became less distressing, and he could rest fairly comfortably when lying on his right side. It was noted on November 21st that the murmur over the tumour was not so continuous as at first, being mainly systolic. On the 24th his breathing had become easier, and it was possible to examine the larynx. The vocal cords were found normal, and acting equally. On the 26th there was an increase of œdema on the right side of the chest, and the breath-sounds were diminished over the upper part of the right lung in front and behind. On this day a sharp attack of dyspnœa

Digitized by Google

occurred. During the next few days the œdema on the right side of the chest increased, the dulness gradually extended upwards to the clavicle, and the breath-sounds over the upper part of the right side of the chest became fainter. On December 3rd it was noted that, whereas the pupils had hitherto been equal, the right was slightly dilated. Death occurred somewhat suddenly in the night between the 3rd and 4th.

Post-mortem report by Dr. Hadden.—Body fat; some œdema of the subcutaneous tissue of chest and neck; none elsewhere.

Liver displaced downwards, the upper limit corresponding to the costal margin, the lower being seven inches below the tip of the ensiform cartilage.

The right pleural cavity contained six pints of fluid blood, and between two and three pints by measure of clot. A small perforation covered by recent coagulum was found in the sac of the aneurysm, opening into the right pleural cavity near the root of the lung.

The heart, aneurysm, and lungs were removed together. The aneurysm began two inches from the aortic valves, but the first part of the aorta was not healthy. The coats were thickened, the inner surface showed raised patches of atheroma, and the vessel was a little dilated. The aneurysm was about the size of an orange, and, except for a little adherent pale clot, was empty. The sac stopped short at the innominate artery; none of the great vessels (innominate, left carotid, and left subclavian) were involved.

In the interior of the aneurysm a small slit in the sac, about half an inch in length, opened directly into the superior vena cava, two inches below the union of the innominate veins. There was a little adherent partially decolorised clot in the last two inches of the left innominate vein, but the other large venous trunks were empty. No signs of pressure by the sac were made out.

Heart: Aortic valves normal in structure, edges somewhat stretched. Left ventricle hypertrophied. A little thickening at junction of two segments of mitral valve, but no contraction of the chordæ or puckering of the edge.

Lungs: Some emphysema and œdema; lower part of the right lower lobe collapsed.

Liver: Normal.

Spleen: Rather firm.

Digitized by Google

Kidneys: Rather heavy and firm (some chronic congestion).
Brain: Vessels at base normal. *December 4th*, 1890.

A card specimen, showing a communication between an aneurysm of the arch of the aorta and the superior vena cava, was brought before this Society by my lamented colleague, Dr. George Gulliver, on May 17th, 1887. It resembled very closely the preparation exhibited this evening. The patient from whom it had been removed had been for some time under the care of my colleague, Dr. Bristowe, in St. Thomas's Hospital. Dr. Bristowe also, in the 'Lancet' of May 27th, 1884, published the notes and results of the *post-mortem* examination in another case of the same kind which had been under his care in St. Thomas's. The symptoms presented by these cases were, in many respects, like those related. As regards the diagnosis, I think it right to state that before I saw the patient, Dr. Hawkins, the Resident Assistant Physician to St. Thomas's Hospital, had recognised the indications of the lesion subsequently found, and that the whole case was carefully presented to me in this aspect by my house physician, Mr. W. W. Stabb. *February 17th*, 1891.

---

12. *Aneurysms above and involving the sinuses of Valsalva. Death from rupture of one into the pericardium.* (*Card specimen.*)

By Francis H. Hawkins, M.B.

This specimen was removed from a man, aged 46, who, while working in a drain, suddenly became faint and giddy; he apparently recovered from the faintness, but shortly afterwards felt a pain in his stomach; he then walked about a hundred yards, and on being admitted into the casualty room, expressed desire to go to stool at once; this he did, but with no result. Shortly afterwards the patient died. A period of one hour and a quarter elapsed from the time of feeling faint and the death of the patient.

The patient was not examined during life. Height five feet seven and a half inches. Circumference round the shoulders forty-four inches. Well-developed muscular man. Rigor mortis marked.

Digitized by Google

On opening the thorax the pericardium was found to be distended, and the anterior free borders of the lungs were slightly retracted.

On opening the pericardium a large blood-clot was seen covering the whole of the anterior surface of the heart. This clot weighed 5 oz. Ten fluid ounces of blood were found in the pericardium. A small slit-like aperture was noticed in what at the time appeared to be the upper and anterior part of the right auricle close to the appendix.

Examination of the heart.—The heart with part of the pericardium and the ascending aorta weighed 16 oz.

The left ventricle measured from base to apex two inches and three quarters.

The ventricular wall measured in its thickest part half an inch.

The aortic cusps, which were competent, were much larger and thinner than usual.

A patch of atheroma was seen on the aorta, just above and over the left half of the anterior sinus of Valsalva.

The aorta to the right formed an aneurysmal dilatation, about the size of a filbert, and involved the right half of the anterior sinus of Valsalva. The wall of the aneurysm was thin. The opening of the right coronary artery was in the base of the aneurysm.

The aorta above the left posterior sinus formed an aneurysm, which also involved the sinus. The aneurysm was about the size of a hazel-nut. The left coronary artery was not situated in the aneurysmal dilatation.

Just above the right posterior cusp is a round opening, nearly one square inch; this involves the whole of the right posterior sinus and the aorta above for nearly three quarters of an inch. This opening leads into an aneurysmal sac, the size of a hen's egg, and which also has two small aneurysms, one anteriorly and one posteriorly. This aneurysm is situated between the ascending aorta and the right auricle, and burrows back a little to the posterior of the ascending aorta. Anteriorly and to the right it has the appearance of being part of the right auricle and on its upper and outer part, just where the aneurysmal sac comes in contact with the right auricular appendix, is a small aperture communicating with the pericardial sac. These three aneurysms are all distinct and separate from each other.

With the exception of the liver, the other organs, although

Digitized by Google

larger than usual and weighing more than the average, presented nothing of pathological interest.

The liver weighed 64 oz., and measured ten inches transversely and nine vertically. The surface was covered with small nodules, giving the appearance of hob-nails. The liver was firm and leathery-like on palpation. Section showed small islets of liver tissue surrounded by connective tissue (the appearances, in fact, of well-marked cirrhosis). No history could be obtained in this case beyond the fact that the man had been a heavy drinker.

May 19*th*, 1891.

---

13. *Saccular aneurysm of aorta in a woman; rupture into left bronchus.* (*Card specimen.*)

By H. D. Rolleston, M.B.

Arising from the descending part of the arch of the aorta, and from the upper part of the thoracic aorta, was a saccular aneurysm, which measured four and three-quarter inches in its long axis, and three inches transversely. Its communication with the aorta was very extensive, measuring four inches. It arose immediately distal to the origin of the left subclavian artery, which it compressed.

It appears to have expanded chiefly in anterior direction. It has compressed, and to a large extent taken the place of the upper lobe of the left lung, which is solid and adherent to the aneurysmal sac. The compressed lung forms a covering about half an inch thick over the aneurysm.

The left vagus is expanded and firmly adherent to the aneurysmal sac.

The aneurysm has burst into the left bronchus, which it compresses, together with the left branch of the pulmonary artery. Projecting into the left bronchus, and partially occluding it, was some old laminated clot. The aneurysmal sac is lined with a well packed laminated clot, the surface of which is smooth, and closely resembles the slightly roughened surface of the atheromatous aorta. The laminated clot forms a layer overlying the aneurysmal

Digitized by Google

sac, which is made of the coats of the aorta, and is in some places an inch and a quarter in thickness. The clot can be fairly easily separated from the aneurysmal sac. The sac is deficient opposite the left side of the third and fourth dorsal, which are eroded. Where the sac is deficient laminated clot is exposed.

The heart was small, and its valves healthy. There was no pericarditis. There was considerable atheroma of the aorta.

From a woman, aged 33 years, under the care of Dr. Ewart in St. George's Hospital, who had suffered from cough and shortness of breath for one year. She had paralysis of the left vocal cord for eight months. *January 20th*, 1891.

---

14. *Saccular aneurysm of descending aorta rupturing into left bronchus.* (*Card specimen.*)

By W. Lee Dickinson.

From a man, aged 34, who had been suffering from hæmoptysis for six weeks. He died with sudden profuse hæmoptysis.

The aneurysm is of remarkably small size, so that it at first appeared as though an atheromatous ulcer had ruptured into the bronchus. It spreads from the front of the aorta, just at the spot where the ductus arteriosus is attached. The left vagus was compressed, but the recurrent laryngeal nerve was free.

April 21st, 1891.

---

15. *Aneurysm of abdominal aorta compressing common bile-duct and rupturing into duodenum.* (*Card specimen.*)

By W. Lee Dickinson.

From a man, aged 28 (meat porter), who had had syphilis and much rheumatism. The duration of symptoms was about six months. There was much pain in the epigastrium and in the

Digitized by Google

back, and great emaciation. Three days before death he became jaundiced. He died after sudden profuse hæmatemesis.

The aneurysm is a large saccular one, springing from the front of the abdominal aorta, just below the cœliac axis. It is covered by the head of the pancreas, which is expanded over it, and it probably contains much clot. The substance of the pancreas is remarkably hard and fibrosed, and the pancreatic duct is considerably dilated. The common bile-duct has been compressed. The aneurysm has burst into the second portion of the duodenum, a short distance above the bile-papilla. *April* 21*st*, 1891.

---

16. *Aneurysm of superior mesenteric artery; extravasation into mesentery; hæmorrhage into peritoneal cavity.* (*Card specimen.*)

By James Galloway, M.B.

The patient from whom the specimen was obtained was a male, aged 35, under the care of Dr. Cholmeley, in the Great Northern Central Hospital. He had been in the Royal Navy for thirteen years, and subsequently was a bricklayer. The history of syphilis given was doubtful.

The duration of his illness was two years. For the greater part of the time the tumour in the abdomen did not trouble him. During the last two months he was much troubled with persistent vomiting. He died suddenly from hæmorrhage into the peritoneal cavity on the 5th May, 1890.

The specimen shows a saccular aneurysm affecting the upper portion of the superior mesenteric artery. In the lower portion of the sac is a rent through which blood had penetrated between the layers of the mesentery, and had distended the portion of the mesentery corresponding to the jejunum with blood, which had formed a soft clot at the time of death. Blood had penetrated through the layers of the mesentery, and death occurred from hæmorrhage into the peritoneal cavity, which was found to be filled with blood-clot. The aorta is extensively atheromatous.

January 20*th*, 1891.

Digitized by Google

17. *Partial rupture of the right subclavian artery with extensive separation of the internal and middle coats.*

By Anthony A. Bowlby.

THE patient from whom this specimen was taken was a woman aged 60. She had been knocked down and run over in the street, and had sustained a fracture of several ribs as well as of the right clavicle.

On admission into St. Bartholomew's Hospital it was noticed that, in addition to the injuries already mentioned, the whole of the right upper extremity was cold, white, and pulseless, and was also very feeble. This condition continued until the death of the patient the following day, with the exception that the limb became warmer. There was at no time any threatening of gangrene.

A *post-mortem* examination showed that the lungs were much congested and the seat of old emphysema. The right clavicle was broken in its middle, and the first rib on the right side was fractured close to its cartilage. The second part of the right subclavian artery, for a distance of an inch or more, was soft and flattened, and was removed together with the arch of the aorta and the axillary vessels. On cutting it open it was found that the arterial walls were healthy, and that the softened part of the artery was blocked by clot. When this was washed out it was found that the lumen of the artery was completely occluded on the distal side of the softened area by the torn middle and internal coats, and a further examination showed the following conditions:—At the junction of the first and second portions of the subclavian the internal and middle coats had been cleanly divided, as if by a narrow ligature, at right angles to the long axis of the vessel. On the cardiac side of this injury the coats had not retracted at all, nor had they curled in towards the lumen of the vessel. On the distal side, however, the inner and middle coats had been entirely stripped from the outer for a distance of more than an inch, and had been completely invaginated and thrust as a plug into the lumen of the artery beyond, so that the third part of the subclavian was plugged by the torn coats which ought to have lined the second part of the vessel, and on the rough inner surface of

Digitized by Google

the second portion of the artery the blood had subsequently clotted. The scalenus anticus was not torn.

It is quite evident that in this case the artery must have been nipped up by the ends of the broken clavicle, which, being driven inwards and backwards, had been thrust with great violence into the vessel, in spite of the protection afforded by the scalenus anticus. It is further clear that after the division of the internal and middle

FIG. 7.

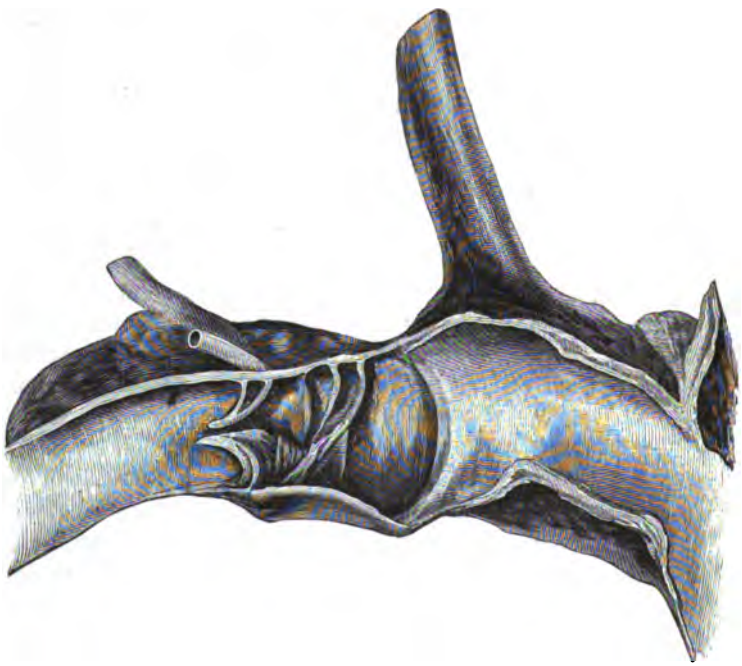

Showing the rupture of the inner and middle coats of the subclavian artery, and the displacement of these into the distal end of the vessel.

coats in this manner the blood-stream had made its way between the middle and external coats, and, having stripped up the former, had thrust it, together with the inner coat, into the lumen of the vessel beyond, and had so prevented the further passage of blood along the damaged trunk.

The specimen is of interest, as I believe it illustrates a hitherto

Digitized by Google

unrecognised pathological process. It is, of course, well known that the inner and middle coats of a vessel may be torn by external violence whilst the outer coat remains intact; and it is generally stated that as a result of this the inner and middle coats tend to curl up a little by reason of their elasticity, and that the blood clots on the damaged parts. I have myself had the opportunity of examining *post mortem*, or after amputations, two specimens of ruptured brachial arteries and one ruptured popliteal, in all of which the outer coat was intact. In none of these, however, was there any considerable retraction or separation of the torn coats although the vessel was occluded by clot.

In the specimen under notice, however, the process was not a mere mechanical retraction, for on the cardiac side of the injury the inner coats were in no way separated from the outer, and it is evident that the exceptional separation of the coats on the distal side of the tear must be attributed to the force of the blood-stream. The reason that such an event does not commonly occur and has not previously been described, must be sought for in the size of the vessel, the larger area exposed to the blood-stream, and the force of the blood-current so near to the aorta. It is very rarely that the vessels in the neck are injured as they were in this case, and opportunities for noticing the result of such an accident must be proportionately few. *November* 18*th*, 1890.

Digitized by Google

IV. DISEASES, ETC., OF THE ORGANS OF DIGESTION.

1. *On a case of pressure diverticulum of the œsophagus.*

By Thomas F. Chavasse.

A farmer, aged 49, was sent to me by my colleague, Sir Walter Foster, and admitted into the General Hospital, Birmingham, on July 17th, 1890. The history given was one of constantly increasing difficulty in swallowing food, extending over a period of ten years. Many methods to give relief had been ineffectually tried by many men.

The main symptom of the case was that the food was brought back in a softened but undigested condition at varying times after being swallowed. The patient was exceedingly emaciated, and although standing 5 ft. 9 in., and well made in proportion, his actual weight was under 8 stone. Inspection and palpation failed to detect any abnormality in the cervical region. On my proposing to pass a No. 10 œsophageal bougie, he remarked, "No one had been able to pass one of that size for a number of years, and the smallest filiform instrument will fail to penetrate the stricture." On the attempt being made, the instrument was arrested seven inches from the teeth, and all manipulations to enter the stomach proved ineffectual. Immediately afterwards portions of an orange and other food that had been taken some hours previously were vomited in an undigested condition. The patient had been fed by enemata for fourteen days, but as these were now rejected, he voluntarily requested that an opening might be made in his stomach.

On July 18th the first stage of gastrostomy was performed, and on the 19th the operation was completed. He died exhausted on the evening of the 21st.

The day after death a *post-mortem* examination of the body was

Digitized by Google

made by Dr. Ratcliffe, pathologist of the hospital, by enlarging somewhat the operation wound in the abdomen.

The right lung revealed a patch of hypostatic pneumonia in its lower lobe posteriorly; the middle lobe was entirely consolidated. The left lung and the heart were normal.

FIG. 8.

The larynx with part of the pharynx, trachea, and œsophagus, and the diverticulum of the latter, described in the text.

The liver, very slightly fatty, weighed 2 lbs. 2 oz. Spleen small, pale, and fibrous, weighed 2 oz. The small intestines flaccid. The cæcum, the transverse and descending coli, were distended with fæces. The kidneys revealed a retention cyst at the apex of the right; both somewhat firm; capsules adherent; cortical substance not diminished.

Digitized by Google

On removing the lungs and examining the apices of the pleural cavities a soft fluctuating mass could be detected on the inner side behind the trachea, rather more marked on the right. On removing this with the œsophagus and stomach, it was found to be a saccular dilatation of the pharynx and upper part of the œsophagus. The sac was of a flattened pear shape, with the following dimensions :—four inches deep from the level of the arytænoids, three and a half inches broad and two and a half inches thick antero-posteriorly. Mouth one inch in diameter; capacity six ounces; the walls were as thick as those of the œsophagus, and lined throughout with mucous membrane. On its anterior wall the œsophagus commenced an inch and a half below the base of the arytænoid cartilages. When the sac was full of fluid the slit-like opening in the œsophagus was compressed and firmly closed. The œsophagus itself was normal, and showed no malignant growth. The stomach was opened in the vicinity of the pylorus.

The diverticula of the œsophagus are classified by Zenker and von Ziemssen (vol. viii) into: 1st, those due to traction which are found on the anterior wall of the tube; 2nd, those due to pressure from within outwards, and are a lesion of the posterior wall. The case recorded comes under the latter category.

The authors quoted above have collected and tabulated thirty-four cases of pressure diverticula, twenty-seven of which were verified by *post-mortem* examination, all of them being men.

Mr. Walter Whitehead has recently ('Lancet,' January 3rd, 1891) added another case, occurring in a married woman, who died aged sixty-three, six years after gastrostomy had been performed.

These diverticula occur singly and in varying sizes; the smaller ones ranging from a pea to a hazel-nut, the larger ones appear as a sac directed downwards between the œsophagus and the vertebræ. They may be pyriform, spherical, or cylindrical; the opening is sometimes wide, sometimes narrow. The walls of the sac appear as thick and as firm as the rest of the œsophagus, and are formed of thickened mucous membrane and a layer of connective tissue As a rule muscular tissue is not found; if it should be present, it is only apparent at the neck of the sac, and is derived from the inferior constrictor of the pharynx and the upper circular fibres of the œsophagus.

The sac is slowly formed by the mucous membrane protruding between the separated transverse fibres of the inferior constrictor

Digitized by Google

muscle, which at the lowest part of the pharynx are the weakest, and are unsupported. Anatomically the distribution of the fibres above and below this point are better adapted to resist pressure from within.

Concerning the origin of these diverticula there are two theories: 1. That they are due to a hernia of the mucous membrane of the fully formed tube. 2. That they are a congenital defect.

With regard to the first, it is suggested that, owing to some local influence, a limited portion of the posterior wall of the pharynx loses its power of resistance to the pressure caused by the act of swallowing. A slight bulging follows, which ultimately becomes pronounced enough to arrest a portion of food for a longer or shorter interval. This, in its turn, acts as a distending force, until at length a sac is formed which hangs downwards between the vertebral column and the œsophagus, and causes the normal opening in the latter to be thrown out of axis, and to be closed by the pressure of the abnormal sac filled with particles of food. The following have been noted as exciting causes:

I. Impaction of a foreign body. Those that have been traced are (*a*) a cherry stone, which remained *in situ* three days, and was then expelled (Ludlow's case); (*b*) a peppercorn remaining eight days (Dendy); (*c*) a piece of chicken bone; (*d*) a portion of hard crust.

II. Traumatism. In one case a fall from a horse caused a rupture of the fibres of the inferior constrictor muscle. The symptoms of a diverticulum commenced with convalescence. This specimen is in the museum at Giessen, and has a capacity of 3½ oz. In another instance, in a woman, prolonged pressure on the side of the neck during a quarrel is ascribed as the cause. In another, a man, bruising of the pharynx by a piece of hot meat is suggested as the starting-point.

III. Stenosis of the upper end of the œsophagus causing a backward pressure is said to have been the cause in two cases.

IV. Enlargement of the right lobe of the thyroid gland compressing the pharynx has been noted in two cases.

V. Constriction of the neck by tight clothing.

That the defect is primarily a congenital one is asserted by Kœnig and Klœbs, who hold that the symptoms only become marked as the sac increases in size. The presence of muscular fibres in the sac is adduced in favour of this theory.

Digitized by Google

Zenker and von Ziemssen stoutly oppose this view, and maintain that in some of the cases in which a complete muscular coat has been described as existing (notably Gassner's case) careful dissection has proved that the muscular tissue could only be found at the neck of the sac, and was evidently derived from the inferior constrictor muscle.

In the present instance it was at first thought that a distinct layer of pale muscular fibres was distributed over the sac, but, on dissecting off some of the supposed muscle, and submitting it to microscopic examination, it proved to be vascular tissue, and no muscular elements could be detected. As far as this single case is concerned, therefore, it bears out the contention of Zenker and von Ziemssen.

The lesion is one of later life. In ten cases in which the date of commencement could be accurately fixed, eight of them began after forty years of age (three being between forty and fifty, four being between fifty and sixty, and one in the sixty-sixth year), the remainder being seventeen and thirty-five.

In nineteen cases recorded in Zenker and von Ziemssen's tables as terminating fatally, and in which the ages are given, seventeen died after fifty, fourteen of them being more than sixty, one of them being in his eightieth year.

Of the causes of death in twenty-seven cases in which a *post-mortem* was obtained, thirteen died in consequence of the diverticulum, eight from some intercurrent malady, and in six the mode of death is not given.

Summarised, the clinical points of interest in this and similar cases are that the condition is a rare one, occurring in elderly men most commonly; that its duration is long and that its diagnosis is a matter of more or less uncertainty; that death results from starvation, and that gastrostomy is the most likely surgical procedure to prolong life. The operation should not be postponed, as in the present instance, until it is evidently too late.

(*January* 20*th*, 1891.)

Digitized by Google

2. *Caseous gland opening into the œsophagus.*

By Arthur Francis Voelcker, M.D., M.R.C.P.

The specimen was obtained from a boy, aged 9 years, who was admitted to the Hospital for Sick Children, Great Ormond Street, under the care of Dr. Cheadle, to whom I am indebted for permission to make use of the case.

He was admitted with typhoidal symptoms, and was found to have cystitis and septicæmia. He died in seven days, and at the *post-mortem*, in addition to bladder, kidney and liver mischief, a mass of cretaceous glands was found at the hilum of the right lung, but there was no ulceration into the bronchus, and no tubercle was found in the lungs.

On opening the œsophagus a perforation was found on the anterior wall, a little to the right of the middle line and a little below the level of the bifurcation of the trachea. The opening was about 5 mm. in diameter, the edges puckered and led into a cavity in which caseous material could be seen.

During life there was no history of any œsophageal trouble.

I have brought this case forward as an example of an unusual result of the presence of caseating glands at the root of the lungs.

In the *post-mortem* records of the Hospital for Sick Children for the last thirty years, that is to say, of 2504 *post-mortems*, I have been able to find three other cases of caseous glands rupturing into the œsophagus, but in two of these the gland had also ruptured into the air-passages. In addition to these is one case in which an oval ulcer, three quarters of an inch long, existed at the level of the bifurcation of the trachea, but in this case the note says, "The muscular coat remains, the floor is smooth as if healed up, although in the neighbourhood of a caseating bronchial gland. The ulceration, as far as could be seen, had not started from or been in any way caused by the gland." The bronchial glands were enlarged and caseous. In all these four cases there was general tuberculosis, which was not the case in the present instance.

Caseous glands at the root of the lung in children are extremely common, and their rupture into the air-passages by no means a rare event and is frequently attended by no clinical symptoms.

Digitized by Google

The frequent occurrence of malignant disease in the œsophagus at the level of the bifurcation of the trachea, has suggested to me the possibility of some local cause for this event, and I think that the cases I have mentioned, together with one derived from the same records in which there was marked hyperæmia of the œsophagus opposite an enlarged caseous gland, lend some support to the view that the irritation caused by enlarged bronchial glands may favour the development of malignant disease in this situation.

November 18*th*, 1890.

---

3. *Malignant disease of the œsophagus communicating with trachea and aorta.* (*Card specimen.*)

By W. B. Hadden.

There is a malignant ulcer of the œsophagus beginning four inches below its upper end and extending downwards for two inches and a half. The limits of the ulcer above and below are well-defined, and marked by raised masses of new growth. About the centre of the affected surface and on the anterior wall there is an irregular communication, about an inch in length, with the lower end of the trachea and the beginning of the right bronchus. There is also a small opening, with rather smooth edges, a sixth of an inch in length, seen on the inner aspect of the lower part of the descending part of the arch of the aorta. This also communicated with the œsophagus at the seat of disease. The œsophagus above was not dilated, below it contained some black clot, and the stomach was quite filled with a coagulum, which weighed 13½ oz. The growth was a squamous-celled carcinoma.

The patient was a man, aged 61, who began to suffer from difficulty in swallowing three months before admission into St. Thomas's Hospital. He began to bring up blood two weeks after admission. A few days later liquids when swallowed caused much cough with laryngeal spasm, and the fluid was found to be mixed with the expectoration. A month after admission he brought up half a pint of pure blood and died suddenly.

February 17*th*, 1891.

Digitized by Google

4. *Epitheliomatous tumour occluding the œsophagus.*

By Lauriston Shaw, M.D.

The specimen consists of the middle portion of the œsophagus laid open in front to show, attached to its posterior wall just above the level of the bifurcation of the trachea, a somewhat flattened conical tumour, measuring about two and a half inches from above downwards, and an inch and a half from side to side. The shape of the tumour is determined by the capacity of the tube, which it so completely filled that at the autopsy a small probe was with difficulty passed by the side of it. The upper part of the growth is free, and presents a ragged sloughy surface, while the lower half has a broad attachment to the posterior wall of the œsophagus. At the point of attachment the growth has invaded and destroyed the muscular coat. Immediately below the tumour there is a ring of ulceration encircling the gullet. Histologically the growth is an ordinary squamous-celled carcinoma.

The patient from whom the preparation is taken was a male, aged 55, who was admitted into Guy's Hospital under Mr. Symonds in 1890 for dysphagia of five months' duration. For nine weeks he had only been able to swallow liquid food, and that with great difficulty. It was found impossible to pass a bougie down the œsophagus, and the patient was fed with nutrient enemata. He died from exhaustion and broncho-pneumonia fourteen days after admission. At the autopsy no secondary deposits were found.

Actual obstruction of the œsophagus by a mass of growth protruding into the lumen of the tube is a rare condition. Such a specimen was shown to the Society by Mr. Targett, and the details are recorded in vol. xl of the 'Transactions,' but in that case the growth was a sarcoma. This form of obstruction must be much more difficult to deal with by intubation than the common epitheliomatous ulceration and stricture of the gullet.

March 17*th*, 1891.

Digitized by Google

5. *Sarcoma of the œsophagus perforating the trachea.*

By Lauriston Shaw, M.D.

The specimen consists of a pharynx and œsophagus with the larynx and trachea of a woman. There is an ulcer with well-defined raised edges encircling the œsophagus, having a more extensive distribution on the anterior than on the posterior wall. In front it extends up to within one inch of the level of the cricoid cartilage, and has a vertical measurement of three inches. For the most part the ulceration merely destroys the mucous membrane, but in the middle line in front it involves all the coats of the œsophagus, and has perforated the posterior wall of the trachea a short distance above its bifurcation. Some of the neighbouring lymphatic glands are enlarged by secondary deposit. Microscopical examination of sections through the base of the ulcer shows that the wall of the œsophagus is infiltrated by sarcoma consisting of round and oval cells.

The patient from whom the preparation was taken was a female domestic servant, aged 38, who was admitted into Guy's Hospital in 1855 for dysphagia of six months' duration. She was extremely emaciated, and any attempt to swallow was followed by regurgitation through the nostrils, and produced a rattling noise in the chest. She died one week after admission. At the autopsy some purulent serum was found in the left pleural cavity, and there were secondary deposits in the lungs and kidneys.

The only other sarcoma of the œsophagus shown to this Society is recorded in vol. xl of the 'Transactions,' and consists of a large mass of growth protruding into the lumen of the tube. The pharynx and upper part of the œsophagus are quite free from disease, so that it cannot be an extension downwards of a pharyngeal sarcoma. The naked-eye appearances of the preparation and the histological characters of the growth are both, I think, opposed to the view that the affection of the œsophagus is an invasion of its wall by primary sarcoma of the mediastinal glands.

March 17th, 1891.

Digitized by Google

Report of the Morbid Growths Committee on Dr. Shaw's specimen of sarcoma of the œsophagus.—We have examined the microscopic sections submitted to us by Dr. Shaw, and have only to confirm his statement that the growth is a sarcoma of round and oval cells. And we agree with the author in thinking that it has not arisen in the mediastinal glands, partly on the general grounds he states, but partly also because it does not correspond in its histology with the form of malignant new growth most likely to have arisen in these structures. Its cells are larger and less spheroidal than those of a lympho-sarcoma, nor has the stroma the disposition met with in the last-named form of growth.

ROBERT WILLIAM PARKER.
SAMUEL G. SHATTOCK.
H. H. CLUTTON, *Chairman.*

---

6. *A tumour involving trachea and œsophagus in the neck.*

By JOHN CAHILL.

THE preparation is taken from a women, aged 49, upon whom I was requested to make a *post-mortem* examination by my friend Mr. Tegart, who had the patient under his care at St. John's Hospital, Great Ormond Street.

It consists of the larynx, trachea, and bronchi, with the upper two thirds of the œsophagus. Immediately below the level of the cricoid cartilage there is a tumour, about two inches in its longest diameter and deeply pigmented in parts, which embraces the œsophagus and the sides of the trachea. The growth has penetrated the tube of the œsophagus, which is displaced to the left, and forms a fungous constriction barely admitting a No. 6 catheter. The trachea is similarly penetrated by the growth, both posteriorly and at the sides, with erosion of the cartilaginous rings. The thyroid body is natural and lies in front of the growth on each side.

There is another and larger tumour lying immediately below the bifurcation of the trachea and firmly adherent to both bronchi and to the pulmonary vessels. This mass is of the size of a tennis ball, and is apparently of lymphomatous nature. It pre-

Digitized by Google

sents a caseous condition in its greater part, and the rest of its substances is deeply pigmented. There are several enlarged and pigmented lymphatic glands attached to the specimen.

The lungs in this subject were œdematous and affected throughout with purulent bronchitis. The upper lobes of both lungs were thickly studded with shotty tubercles and tubercular abscesses.

The other organs were natural. There was no obvious enlargement of the lymphatic glands in other parts of the body.

The patient was in Brompton Hospital from July to November, 1889, and I have obtained the history of the case during that time through the kindness of Dr. Kershaw, the resident medical officer. When admitted there was cough, soreness of throat, and difficulty of swallowing. No abnormality was then detected in the larynx or trachea. Early in September, 1889, there was found to be complete paralysis of the right vocal cord. A slight swelling in the neck at the level of the larynx was first noticed in the preceding month. There was orthopnœa and increasing dysphagia throughout the last five months of the patient's life. Fixation of the left vocal cord was observed about two months before death, and the slight swelling on the right side of the neck persisted until her death, which occurred in January, 1890.

On first dissecting the cervical tumour the growth appeared, from its apparent invasion of the œsophagus and trachea, to be probably of a carcinomatous nature. But upon examination of section of the growth, its character appears rather to be lymphomatous. There is a richly nucleated fibrous stroma, enclosing numerous alveoli, which are packed with small rounded cells. The contents of the larger alveoli are seen to be disintegrating at the centre. The pigmentation of the growth and its distinct peripheral limitation increase its resemblance to the lymphomatous mass in the posterior mediastinum.

For the histological preparations I am indebted to Mr. H. H. Taylor, late resident medical officer at Brompton Hospital, who had been much interested in the case while it was at Brompton.

December 16*th*, 1890.

Report on Dr. Cahill's specimen of tumour of the neck.—We have examined the microscopical specimens prepared by Dr. Cahill, and find that they exhibit all the characters of a carcinoma. The stroma is abundant and strongly fibrous, the alveolar spaces are

Digitized by Google

large and well defined. The cells are rounded and fill the spaces. The whole appearances, in fact, are most typical of spheroidal-celled carcinoma. One of the sections shows degeneration of the cells. We do not find any characters of lymphoma in the sections. We have made sections from the large glandular mass situated below the bifurcation of the trachea, and find this to exhibit the same structure. We look upon this mass as secondary to the main growth. This latter is placed between the œsophagus and the trachea, at a point one inch below the cricoid, and infiltrates both tubes. The whole thickness of the trachea is involved for about a third of the circumference, and the œsophageal wall is also occupied by growth for the same length as the trachea, but only at the lower part does the growth penetrate into the lumen, the mucous membrane remaining entire though adherent over the rest. The whole mass is everywhere hard and nodular, with a thick advancing margin. This growth must have started either in the trachea or in the œsophagus, and as both are about equally infiltrated, and as the œsophagus is the more common site for such growths, we are of opinion that the specimen is one of carcinoma of this tube, the disease beginning in the mucous glands.

CHARTERS J. SYMONDS.
ANTHONY A. BOWLBY.
H. H. CLUTTON, *Chairman.*

January 24th, 1891.

---

7. *A case of chylous ascites and chylous hydrothorax, due to thrombosis and contraction of veins at the root of the neck on the left side.*

By SIDNEY MARTIN, M.D.

FOR the use of the clinical notes of this case I am indebted to Dr. Cayley, for the pathological notes I am myself responsible.

The patient, Mary W—, a cook, aged 39, was admitted to the Middlesex Hospital on March 13th, 1890, under the care of Dr. Cayley, suffering from enlargement of the abdomen with

Digitized by Google

dyspnœa and vomiting. The patient's parents both suffered from asthmatic attacks; she herself had been troubled with shortness of breath and palpitation when a girl, and at the age of 19 had an attack of whooping-cough.

The present illness commenced about five months ago, after getting wet and chilled, but the patient did not lie up during the first three months. There was from the first a good deal of cough with expectoration resembling white of egg and marked dyspnœa. During the last six weeks she had been repeatedly sick, the vomited matters being sometimes streaked with blood. She has quite lost appetite, and has been much troubled with flatulence. During this period also the abdomen has notably enlarged, though there has been progressive loss of flesh in the limbs.

The patient has always been temperate. The urine has been high-coloured and usually exhibited a pink deposit.

Examination disclosed some shifting dulness over the dependent parts of the abdomen, with some tenderness below the costal arch, and very great flatulent distension. Neither liver nor spleen extended below the ribs, and there were no enlarged veins over the surface; the girth at the umbilicus was forty-five inches.

The normal area of cardiac dulness was almost obliterated, but some want of resonance could be made out beneath the sternum. Movement on the right side of the thorax was defective; there was a slightly impaired note on percussion, and the breath-sounds were feeble and accompanied by rhonci and some crepitant râles. On the left side both movements and breath-sounds were exaggerated, and a few crepitations could be heard at the extreme base.

The pulse was 132 and respirations 48. The urine was scanty, high-coloured, with a sp. gr. of 1035, and exhibited a copious deposit of pink lithates.

On March 27th the feet and legs had become swollen and shiny, and the girth at the umbilcus had increased to forty-eight inches.

A week later the left arm was also swollen, the right retaining its normal bulk, though the patient did not recline towards the affected side nor was any local cause of pressure discoverable.

On the 7th of April it was noted that the patient suffered from occasional attacks of dyspnœa, was sometimes sick, and had a dry irritable cough. There has been some diarrhœa, and the abdominal girth is reduced to forty-six inches. The sputum was examined for tubercle bacilli with a negative result. Two days later the

Digitized by Google

swelling disappeared from the left arm, but returned again after a couple of days.

On the 15th some relief was afforded by draining away clear serum from puncture in the legs, which continued to exude for a week. At the expiration of this time the abdomen had become more tense, and 48 oz. of alkaline milk-like fluid were withdrawn, having a sp. gr. of 1022, and solidifying on boiling. Under the microscope leucocytes and numerous small fat globules were recognised. The fat was partly dissolved on shaking with ether, leaving a greasy stain on paper after evaporation. Five days later it was necessary to perform paracentesis again, and 16 oz. of fluid were removed having the same characters as the last. The same night she was seized with sudden dyspnœa, and died of asphyxia in about an hour. The temperature throughout was subnormal.

Post-mortem (twelve hours after death): Rigor mortis, slight. The body was well-made and well-nourished. One inch of subcutaneous fat was present over the abdomen. The face and neck were of a uniform purple tint. There was great œdema of the legs below the knees, and also above the knee on the left side.

Abdomen is greatly distended, containing over 180 oz. of yellowish milky (chylous) fluid, in which are several long shreds of fibrin. Over the peritoneum in the right iliac fossa (which is completely covered by the serous membrane) there are numerous yellowish-white masses, soft, pultaceous, and easily removable from the subjacent congested membrane. This exudation extends into Douglas' pouch, and behind and below the uterus there is on each side a large mass of this exudation, uniform yellowish white on section, and softer than cream cheese. No recent peritonitis. The cæcum was displaced to the right hypochondrium, and lay just under the liver. The ascending colon (which occupied the normal position of the transverse colon) was enormously distended with gas.

Lymphatics.—The surface of the small gut, and to a much less extent that of the large gut, was marked by the ramification of dilated lymphatics containing a milky fluid. The whole surface presented a milky arborescent appearance, which extended throughout the elongated mesentery.

Thoracic duct could not be found in abdomen or thorax, after careful dissection. Receptaculum chyli was not found. The lymphatics on whole of the surface of the left lung were dilated, and presented a milky arborescent appearance; partly

Digitized by Google

also over right lung (see Lungs). There was some thickening of the connective tissue in front of the right kidney, but this did not extend over to the left side.

Liver: Not enlarged. Rather pale on surface, which is smooth. On section, lobules are distinct, substance is dark and firm (normal).

Spleen: Not enlarged. Dark, firm (normal).

Supra-renals: Normal.

Kidneys: Not enlarged. Capsule not adherent; surface smooth. On section, general mottling of substance, with yellowish streaks in parts. Cortex not diminished, firm (normal).

Bladder: Normal.

Uterus: Rather small; otherwise normal. Tubes patent.

Ovaries: Enlarged somewhat. Capsule thickened; one small cyst in right ovary. Ovarian tissue firm and fibroid.

Heart: Pericardium contained a small quantity of clear straw-coloured fluid; lymphatics not distended. Endocardium and valves normal. Adherent clots at apices of both ventricles. Muscle dark, firm.

Lung: Left pleura is not adherent, and contains about 10 oz. of milky fluid like that in the abdomen, only thinner. Right pleura is very firmly adherent, especially over lower two thirds. Lymphatics are distended with an opaque milky fluid (rendering surface aborescent) over the left lung, and the small area of the right lung when the pleura is not firmly adherent.

Right lung is firm on section; there is a general increase of connective tissue, with great œdema; many pin's head points exuding a yellowish liquid (distended lymphatics). *Left* lung is similar on section, but is not so tough.

Veins: The azygos and intercostal veins are greatly distended. The left innominate vein is small but patent; just at its commencement it is completely occluded by contraction, the small orifice being filled with a firm adherent clot. The left subclavian vein is completely occluded about two inches from its junction with the jugular, which is also occluded for the last two inches. Both the points of occlusion of the vessels are marked by a contraction of the walls of the vessels, and a complete transverse band of fibrous tissue; the part of the vessel between the occlusion and the innominate vein is a mere fibrous band.

The internal mammary vein enters the innominate vein and is patent, but has thickened walls. The supra-scapular vein is plugged

Digitized by Google

FIG. 9.

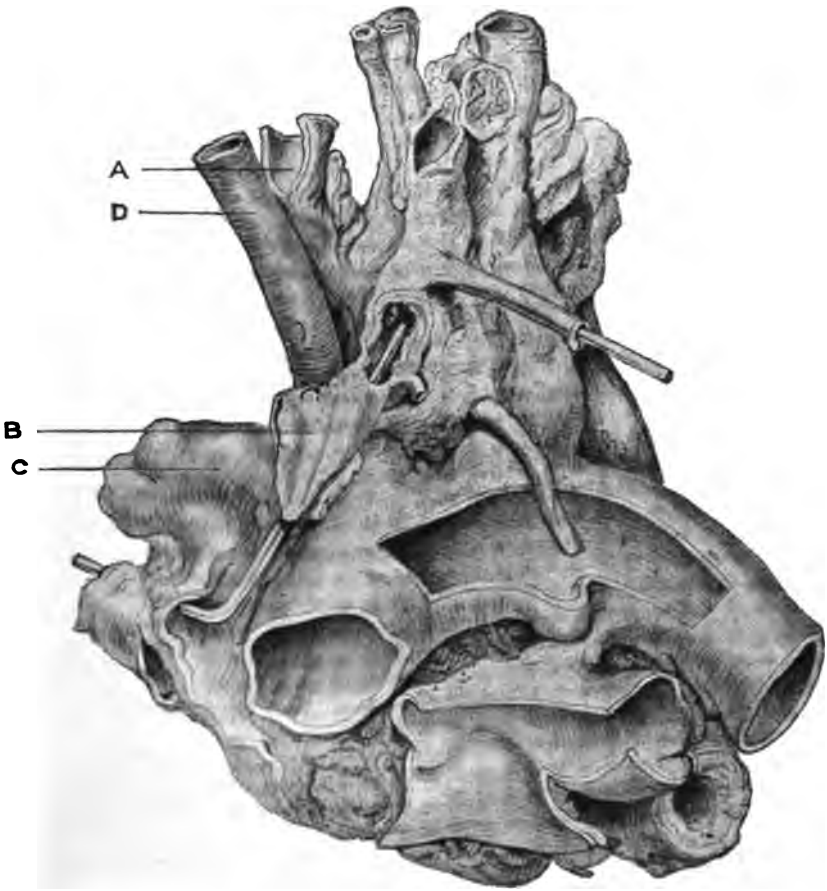

A dissection of the veins at the root of the neck in the case described. A. Left internal jugular vein. B. Left innominate vein. C. Innominate artery; by its side the right innominate vein. D. Left common carotid artery. A bent probe has been passed from one innominate vein into the other.

by a decolourised and adherent clot. The veins in the right side of the neck are normal. Arteries are normal.

Examination of the chylous fluid.—Microscopically it presents numerous minute refracting granules as in a fat emulsion; a few leucocytes are also seen.

Chemically it contains coagulable albumen and globulin, fat, and inorganic salts. It contains no albumose or peptone, and no sugar.

Digitized by Google

Chemical composition in 100 *parts.*

Water	92·98	
Total solids	7·02	
Proteid		4·46
Fat and cholesterin		1·78
Ash (chiefly chlorides)		0·48
Error of analysis		0·3

The fat is solid at the ordinary temperature, and is liquid at 38° C. The characteristic of the fluid is therefore the presence of a large amount of fat in the form of an emulsion. Ascitic fluid in cirrhosis of the liver (according to two analyses of Hoppe-Seyler [1]) contains only a trace of substances soluble in ether—0·034 to 0·043 per cent. The amount of fat present in other cases of chylous ascites and hydrothorax varies between 1·03 and 1·87 per cent. In a case examined by Hoppe-Seyler the amount of fat present was 0·7226 per cent., with 0·215 per cent. of lecithin and cholesterin. Chyle contains about 0·9 per cent. of fat, but the amount varies with the quantity of fat ingested. In the following table the various percentage analyses of chylous extravasations are compared with those of chyle and of ascitic fluid.

Percentage composition.

	Sp. gr.	Water.	Total solids.	Proteid	Fat.	Extractive.	Salts.	
1. Chyle	—	90·5	9·5	7·1	0·9	1·0	0·5	
2. Case here recorded	1022	92·98	7·02	4·46	1·78	—	0·48	(error 0·3)
3. Quincke's case of chylous ascites	—	—	—	—	1·68–1·87	—	—	
4. Quincke's case of chylous hydrothorax	—	—	—	—	1·078–1·263	—	—	
5. Wilks and Ormerod's case (analysis by Marcet)	1012·5	94·773	5·227	1·965	1·993	1·269		
6. Whitla's case (analysis by M. Hay)	—	94·085	5·915	2·878	1·030	1·012	0·995	
7. Hoppe-Seyler's case	—	94·07	5·92	3·66	0·93 [3]	·598	·719	
8. Ascitic fluid (Hoppe-Seyler)	—	98·45	1·55	0·617	0·034	0·024	0·846	(error 0·038)

[1] 'Physiologische Chemie,' 1881, p. 597.

[2] Sugar 0·21 per cent.

[3] Fat, cholesterin, and lecithin.

Digitized by Google

The composition of the chylous extravasations is similar to that of chyle in the large proportion of fat present in the form of emulsion. It differs from chyle in the lower percentage of proteid matter, although not to so great an extent as ascitic fluid differs from serum.

Remarks.—In considering the mechanism of the production of chylous extravasations, these may be due either to an obstruction to the flow of chyle, or to rupture of the thoracic duct or receptaculum chyli. Rupture of the duct may occur from injury without apparent lesion of the pleura or lung, as in one case recorded by Quincke,[1] where chylous hydrothorax occurred, and there was a blood-clot in the upper end of the thoracic duct; rupture has occurred during an attack of whooping-cough (Wilhelm[2]), or rupture may follow obstruction of the duct. Rokitansky[3] has described a case of chylous hydrothorax and ascites, with dilatation of the visceral lymphatics and of the thoracic duct, associated with mitral regurgitation and cardiac dilatation. Obstruction to the flow of chyle may occur at the junction of the intestinal with the mesenteric lacteals,[4] or from pressure on the thoracic duct by tumours, or by closure of the opening of the thoracic duct by thrombosis of the veins. Oppolzer[5] has described such a case, in which the patient was tapped seven times, the last tappings producing a turbid fatty fluid, the appearance being ascribed by him as due to fatty degeneration of the epithelium-cells. In most of these cases rupture of the duct is supposed to have occurred, and it is possible that such an event occurred in the case here recorded, since the duct could not be found in the thorax.

October 21*st*, 1890.

[1] 'Deutsche Archiv für klin. Med.,' xvi, 1875, p. 121.
[2] Abst. in 'Gaz. Hebdomad.,' 1875, No. 28.
[3] 'Path. Anatomie,' vol. ii, p. 388.
[4] See Quincke, op. cit.
[5] Quoted by Quincke, op. cit.

Digitized by Google

8. *A case of chylous ascites.*

By Fred. J. Smith, M.B., M.R.C.P.

On October 21st of last year Dr. Sidney Martin read a paper on chylous ascites. In the discussion that followed I mentioned a case then under Dr. Fenwick's care in the London Hospital, and you, sir, asked me to bring it before the Society at some future date.

In accordance with your wishes, and by the kindness of Dr. Fenwick, I am now able to give the full details, which are as follow:

The patient, J. G—, was a female, aged 67. Her family history is quite free from carcinoma. She has been a governess all her life. As a child she was delicate, and enjoyed but poor health, but when about fourteen years old she became stronger. Her menstrual periods were always painful, and she has constantly had a pain in the right iliac fossa, which increased during the menstrual flow. She has always been troubled with indigestion, but has never suffered from jaundice.

The history of her present and last illness dates from May, 1889, when she felt her food lie very heavy on the stomach, and was much depressed in spirit. Pain was so severe as to prevent her from walking, though she had previously been a good walker.

In August, 1889, she came to town to consult a physician, who told her that the bladder was at fault, though she had no symptoms on the urinary side; the stomach swelled very much, but it is doubtful whether this was due to wind or ascites; at the same time she noticed that she was beginning to lose flesh. During the succeeding months she gradually improved, and by March of this year was tolerably well again.

In May, 1890, precisely the same symptoms as before reappeared, weight and pain after food, but no sickness; her stomach began to swell again as it had done previously. She came to London in June, and was admitted to the hospital in July; paracentesis abdominis was performed three times between then and September 8th, when she was discharged, but returned on September 20th, and was at once tapped, and again on about

Digitized by Google

October 6th or 7th. The fluid withdrawn at each operation always presented the same features; to the naked eye it was exactly like milk, and under the microscope showed only a fine emulsion of fatty matter. An exact examination, I regret to say, was not made with regard to its precise chemical composition.

On October 24th her condition was noted as follows:—The veins over the abdomen are much distended, and there is considerable œdema of the abdominal walls; the peritoneum gives the impression of being thickened, and a large mass is to be felt in the epigastrium. Pain and tenderness are complained of in both iliac fossæ, while *per vaginam* another large mass is to be felt.

From this time the patient steadily emaciated, and she died on December 11th. During the last six weeks the ascites never became sufficiently marked to call for another tapping operation, so that I was unable to obtain a specimen of fluid for detailed analysis.

A *post-mortem* examination made thirty hours after death revealed the following condition:—The body was much wasted, the legs were still œdematous; no enlarged glands were to be felt. On opening the abdomen a little fluid escaped, but it presented the appearance of simple serum; the peritoneum was so firmly adherent to the underlying intestines that it had to be cut off with the knife.

The heart was small, firmly contracted, and healthy.

The lungs were emphysematous and œdematous, otherwise healthy, except for a very slight calcareous puckering at each apex.

In the right pleural cavity was about one pint of simple serous fluid, and a few roughened spots were found at the base.

The liver was the first abdominal organ removed; its capsule was much thickened, and the organ itself dragged out of place by the contraction of most dense peritoneal adhesions; the mass felt in the epigastrium during life was seen to be the right lobe of the liver dragged down below the margin of the ribs. The gall-bladder was enormously distended with thick ropy mucus, the cystic duct being blocked by two large gall-stones, though when these were pushed back the duct was still impervious; the common duct was quite free, thus accounting for the absence of jaundice.

The spleen, stomach, omentum, small intestines, and colon were so inextricably bound together by dense old adhesions that they had to be removed *en masse* and then examined. On superficial

Digitized by Google

view they formed simply a round mass firmly bound together by old dirty-looking fibrous tissue soaked in serum; in two places white patches about two inches in diameter appeared, which I at first took to be masses of carcinoma, but a little careful dissection showed them to be small subperitoneal extravasations of chyle. The contents of one were still quite fluid, but those of the other squeezed out like sebaceous material or clotted cream. A specimen is under the microscope, showing that they consist of an emulsion of fat, with here and there a few leucocyte-looking cells.

It was impossible to separate the coils of gut even with great care, but at the posterior surface of the mass it was found that the mesentery was thickened, œdematous, and puckered up into a very firm and dense stratum of connective tissue, infiltrated in all directions with minute shotty nodules of carcinoma.

The thoracic duct with its receptaculum chyli were carefully dissected up to the entrance into the subclavian vein, and found to be perfectly healthy.

Both kidneys, though very closely involved in the matted mass, were quite normal in appearance.

The spleen was small and fibrous, but otherwise perfectly normal.

The pelvic organs were taken out *en masse* like the abdominal ones.

The bladder was small but healthy.

The uterus was affected with three separate fibro-myomata, each about the size of a walnut, two intra-mural and one subperitoneal.

The ovaries were *per se* healthy, but in each broad ligament was a cyst about as large as a Tangerine orange.

The peritoneum covering these organs was studded with small nodules of growth like that in the abdomen; it was œdematous, and had formed very dense fibrous adhesions between the various pelvic organs.

The case regarded as a whole is a most interesting one from many points of view.

Firstly, as to the sequence of pathological changes, my own impression is that the gall-stones (firmly fixed as they were at the neck of the gall-bladder) were the primary irritant; I believe that they started a peritonitis of a slowly progressing chronic character, which eventually spread all over the membrane. Contraction followed with obstruction of the lymphatic tributaries; starvation consequently ensued, and caused death.

Digitized by Google

Secondly, what share had the carcinoma in producing death? I believe that it acted the part of the proverbial last straw in breaking the camel's back, and was a mere accident due to the diminished vitality of the peritoneal tissues brought about by chronic simple inflammation. That it could and would have ultimately killed the patient no one can doubt, but that it did so in this case I am disposed to disbelieve, briefly on these grounds:

1. The nodules were not numerous enough by themselves only to cause such serious lymphatic obstruction.

2. The verified presence of mechanical cause sufficient to produce a wide-spread simple peritonitis.

3. The duration of the case; cancer of the peritoneum usually kills much under a year from the onset of symptoms, while this case lasted nearly twenty months.

Thirdly, why did this patient have chylous ascites instead of the common serous form? That there was a damming back of the chyle after its absorption was evident *ante mortem* from the nature of the aspirated fluid, and *post mortem* from the islands of extravasated chyle; but the precise immediate cause of this is, I think, not quite so simple. I attribute it, however, firstly to a large occlusion of numerous lymphatic vessels from simple peritonitis, followed by a secondary more complete blocking from new growth. To my friend Dr. Galloway I am indebted for specimens of the primary and secondary growths, an examination of which shows that the secondary nodules have much more simple inflammatory tissue around them than exists in the primary tumour.

January 6th, 1891.

---

9. *Loose body in peritoneal cavity.* (*Card specimen.*)

By H. D. Rolleston, M.B.

The specimen is oblong ($1\frac{1}{4} \times \frac{1}{2}$ inch); its surface is slightly roughened, and at one extremity a short projection is seen, the remains probably of its stalk-like attachment. It appeared probable that it was a calcified lymphatic gland, which from the wasting of surrounding fat had become pedunculated. No base of

Digitized by Google

attachment could be found on the peritoneum. On section a thick fibrous capsule was found surrounding a calcareous centre.

From a man aged 68 years, who died of diabetes mellitus; he had calculi in the prostate and in the pancreatic duct, and extensive calcareous degeneration of his arterial system.

October 21*st*, 1890.

---

10. *Contraction of the stomach from chronic inflammation.* (*Card specimen.*)

By Lauriston Shaw, M.D.

The preparation consists of a stomach with the lower end of the œsophagus and first part of the duodenum. The cavity of the stomach is so greatly contracted as barely to hold an ounce of fluid, and it measures but four inches from the cardiac to the pyloric orifice. The walls of the organ are thickened to the extent of half an inch, and the mucous membrane is for the most part replaced by cicatricial tissue. On the anterior wall there is an irregular patch of ulceration disclosing the muscular coat. Histological examination of the wall of the stomach, taken through a part where the mucous membrane is intact, shows that there is a large amount of fibroid material in the submucous tissue, and that there is small-celled infiltration of all the coats of the organ. There is no evidence of malignant growth.

Thomas F—, aged 34 years, was admitted into Guy's Hospital in 1854, suffering from great emaciation with constant regurgitation of food. These symptoms had been gradually increasing for eight months. He died from lobar pneumonia. No history of the patient having taken poison was obtained. *May* 19*th*, 1891.

Digitized by Google

11. *Extreme cicatrisation and contraction of the stomach, due to a corrosive poison taken three months previously.*

By C. H. Golding-Bird and G. Newton Pitt, M.D.

Chas. C—, aged 34, admitted on February 2nd, 1889, under the joint care of Dr. Pavy and Mr. Golding-Bird. In November, 1888, he had been admitted into the Gravesend Infirmary with symptoms of acute irritant poisoning; he was constantly sick and vomited blood. He had now great epigastric pain. He was very reticent, and no history of poisoning could be obtained. From knowledge subsequently gained it is certain that an irritant poison had been swallowed, but this was not known until after the patient's death. His state on admission suggested to Dr. Pavy stricture of the œsophagus, who, therefore, desired him to be seen by a surgeon.

On examination he had all the appearance of starvation; he incessantly vomited all his food, unchanged, after a lapse of time, generally in about half an hour. Milk was returned curdled but undigested. There was no dysphagia, but after swallowing anything he complained of a "bursting pain" aross the body, at the level of the ensiform cartilage, on the right side of which point pain could be produced by deep pressure; at the same moment he always complained of an accompanying pain in his throat. An œsophagus tube of full size could be easily passed, a little blood and some acid liquid returning as it was withdrawn; if fluid food were passed down the tube it was immediately returned, none was retained. Mr. Golding-Bird concluded, from the above symptoms, that it was a case probably of contracted pylorus, and suggested gastrostomy with a view to dilatation should this condition be found to exist. He performed the operation on January 23rd, the incision being an oblique one below and parallel to the left ribs; the surface of the liver could only be found, however, so the wound was prolonged vertically. The edge of the liver was then raised, and an opaque white hollow viscus presented itself, appearing exactly like stomach; no omentum was seen. The viscus was attached to the parietes in the usual way, but was not opened. The patient's condition remained as before the operation for

Digitized by Google

eighteen hours; there was no local inflammation; he was (as lately) nourished by enemata. The viscus was at the end of this time opened, as starvation appeared imminent, and 2 oz. of milk and beef-tea were administered. The first introduction of the food caused a gush of bile to flow out through the short tube that was being employed; after waiting a few minutes, however, the remainder of the meal was administered without difficulty. He was fed at intervals in the same way, some regurgitation of food and bile occurring each time; he improved at first, and on January 28th he sat up in bed, but was evidently much weaker though in no pain; the same evening he was apparently sinking from inanition. He died the following day.

The day after the operation the total urea in twenty-four hours' urine was estimated; it only amounted to 105 grains.

Inspection.—There was broncho-pneumonia chiefly in the left lung; at the apex of the lowest lobe there was an abscess cavity with ragged walls.

The margin of the left lobe of the liver and the duodenum were adherent to the abdominal wound.

The transverse colon was much distended with fæces, and formed a large U-shaped bend down to the pubes; the descending colon was empty. The splenic flexure was high up under the ribs.

The duodenum had been opened half an inch below the pylorus, and the omentum was adherent around it. There was a local acute peritonitis, with lymph over an area two inches across on the surface of the liver. The stomach was hidden out of sight, with its axis almost vertical. On opening the œsophagus and stomach a most remarkable appearance was presented.

The œsophagus, above the bifurcation of the trachea was healthy, the mucous membrane of the remainder being destroyed, the surface scarred and pigmented, and the lumen irregularly contracted.

There was a marked thickening with increase in density of the wall, extending from a spot two inches above the cardia for one and a quarter inches, leading to some constriction. At this level the circumference was three quarters of an inch; above, one and a quarter inches; below, one and one eighth inches; cardiac orifice, three quarters of an inch.

The stomach was very small, being five inches long and two and a quarter broad. The mucous membrane, especially on the posterior

Digitized by Google

surface, was very abnormal, being replaced by scar tissue, which formed numerous raised fibroid trabeculæ running in various directions. The ulceration and scarring was most extensive near the lesser curvature, where no healthy mucous membrane remained. In addition to the small irregular depressions there were scars of larger ulcers; and six sacculi on the posterior wall large enough to admit a finger-tip. The pyloric portion of the stomach was much contracted and the wall thickened. The pyloric orifice was so small that a probe could only be introduced with difficulty, and even when the duodenum had been slit up the orifice only admitted a No. 8 catheter.

The kidneys weighed 8½ oz., and showed many fibroid glomeruli with increase in the glomerular nuclei. The arteries were tortuous and thickened. Heart 7 oz. There were no lardaceous changes in any viscera.

The size and position of the stomach explain how it was that the duodenum was opened in its place; and this being done, the sudden gush of bile on the introduction of food is also accounted for. This is not, however, a necessary or constant accompaniment of feeding directly into the duodenum. It is very rare for so much cicatrisation and contraction of the stomach as is present in this case to occur. A case shown by Dr. Hadden this session, and another specimen shown to-night by Dr. Shaw are, however, even more extreme. In the present case the stenosis of the pylorus was so great that the orifice was only sufficiently large to admit a catheter.

May 19*th*, 1891.

---

12. *A case of extreme contraction of the stomach.*

By W. B. Hadden, M.D.

The patient was a woman, aged 30, who had suffered from pain and vomiting for ten months. For the three months preceding death she had lived on liquid food, which she took with marked slowness. The vomiting ceased during the last month of life.

The body was much emaciated, and weighed only four stone.

Digitized by Google

The upper half of the œsophagus was healthy, but the inner surface of the lower half was rough and ulcerated. The stomach, which was tube-like in shape, was extremely small, measuring only four and a half inches in length, and having a circumference of one inch. The walls were half an inch thick, this being due to a chronic inflammatory œdema of the submucous coat. For the first two inches the stomach, like the œsophagus, was rough and ulcerated, but the inner surface elsewhere was smooth, white, and firm. The duodenum was healthy. There was some patchy œdema and congestion of the mucous membrane of the small intestines. The upper lobe of the left lung was smooth, solid, and grey, and in the centre there was a rather recent cavity, about three inches in diameter. The lower lobe showed much increase in connective tissue with embedded caseous masses.

On examining microscopically sections of the wall of the stomach the mucous membrane was found to have disappeared. There was great fibrous thickening of the submucous coat, with an open-textured appearance suggesting œdema. The other coats of the stomach were normal.

It is possible that the extreme contraction followed the action of some corrosive poison, although no information on this point was obtained from the friends of the patient. *April* 21*st*, 1891.

---

13. *Anthrax œdema of stomach.* (*Card specimen.*)

By G. Newton Pitt, M.D.

From a butcher, aged 30, who dealt in foreign meat.

March 8th.—Pimple on cheek, which he scratched.

12th.—This increased to the size of a pea, and contained fluid.

14th.—A mass two inches across, a quarter inch thick on left cheek, black at centre, with vesicular ring around, was removed.

The man died on the 16th of acute blood-poisoning. Temp. 101° —99·6°, pulse 136, resp. 39, having had much dyspnœa.

Post-mortem.—No lesions except in the stomach and face. There is a transverse fold of œdematous mucous membrane six inches

Digitized by Google

Digitized by Google

DESCRIPTION OF PLATE II.

A drawing by Mr. Toogood to illustrate Dr. Newton Pitt's case of Deposit of Lead-Sulphide limited to the Cæcum and Colon. (Page 109.)

The drawing shows the ileum absolutely free from pigment, and the cæcum darkly mottled with deposit, which was shown by analysis to contain lead.

Digitized by Google

Digitized by Google

Digitized by Google

long, the thickness of a finger, on the surface of which are hæmorrhages, and one part of which has sloughed. On section this is found crammed with innumerable anthrax bacilli; these were also found in the blood-serum. *March 17th*, 1891.

---

14. *Colon pigmented black throughout with lead.*

By G. Newton Pitt, M.D.

[With Plate II.]

This specimen was removed from the body of Charles H—, aged 45, who died from epistaxis and chronic Bright's disease with granular kidney. He had been a worker in lead, and had suffered with lead colic and gout. At the inspection the whole of the small intestine was healthy, but the cæcum and colon down to the anus were deeply pigmented; in the region of the cæcum and colon the colour was almost black. At present but little pigment remains, as the specimen has been kept in spirit.

Dr. Stevenson was kind enough to analyse nine inches of the colon, weighing 47·51 grains. This contained ·0086 per cent. of lead. *April 7th*, 1891.

---

15. *Ulcerative colitis.*

By Seymour J. Sharkey, M.D.

For the notes of the first case I am indebted to Dr. C. D. Green, in consultation with whom I saw the patient.

M. P—, aged 33 years, married, one child aged six years; no miscarriages. I first saw her in January, 1890, when she had a longitudinal fissure on the dorsum of the tongue, which took several weeks to heal. Iodide of potash had no marked effect upon it.

Digitized by Google

There was no evidence of syphilis. On September 16th, 1890, I was sent for to see her. She complained of diarrhœa and abdominal pain, which did not yield to treatment, but got steadily worse. The motions were mostly finely divided and dark in colour, with from time to time an admixture of blood. There was occasional vomiting. I took the temperature often, but not every day, and on one occasion only did I find any rise, and that only to 101° F. The diarrhœa was constant and uninfluenced by diet. The patient had an attack of erythema nodosum involving both arms and both legs, which ran an ordinary course.

She gradually and slowly emaciated, and died exhausted in about ten weeks from the commencement of her illness. There had been abdominal pain and tenderness for some days prior to death. At the autopsy I found the whole length of the large intestine, from the cæcum to the termination of the rectum, extensively ulcerated, and so thin that it was difficult to remove it from the body without tearing it. Two perforations had taken place, one in the cæcum and the other in the sigmoid flexure. The ulcers were for the most part confluent, but here and there were some more isolated, the edges of which were well defined. In one or two places a slough could be seen. Only one ulcer was found in the small intestine, rather high up. There was a patch of hypostatic congestion in the left lung. The right lung, heart, liver, spleen, and kidneys were normal. The brain was not examined.

In the large intestine it may be seen that inflammation and ulceration have made great havoc. The greater part of the mucous membrane is gone. Here and there irregular islands remain, but over the greater portion of the bowel the muscular coat is exposed to view, and the surface as a whole is pretty smooth. One or two perforations are seen.

The second case was that of a single lady between fifty and sixty years of age, who for many years had been a nurse or "Sister" at St. Thomas's Hospital. She had always been healthy, except about the time of the climacteric, when she had a curious attack, to which it is difficult to give a name. She gradually got pale, very short of breath, and finally had dropsy in the lower extremities. When I saw her she was pale, rather too stout, and had a very rapid pulse. She always had slightly prominent eyeballs. She had, however, no increase in the size of the thyroid gland. She gradually improved under treatment, and after going away for a

Digitized by Google

holiday got quite well. She remained so, doing active useful work for several years.

About May, 1890, she took it into her head to paint with her own hand all the furniture both in her bedroom and sitting-room, and the painting extended over two months. Meanwhile she lived during the day and the night in an atmosphere which smelt strongly of paint. I only mention this because, rightly or wrongly, she attributed her illness to this circumstance. She noticed then for the first time blood occasionally in her motions, but she felt well, and had no pain or diarrhœa. After her painting was over she went to Switzerland for a month, where she was very well and saw no more blood.

On the 21st of October, 1890, she had some diarrhœa, which continued for five days, and then was associated with abdominal pain. It was at this period that I was first asked to see her, but I found nothing abnormal on a general physical examination. The diarrhœa, however, became very severe, the actions of the bowels numbering from ten to twenty-three in the day. A very large quantity of mucus and a good deal of blood was passed, and there was great tenesmus. Such fæcal matter as was evacuated was very offensive, but many of the motions consisted simply of clear mucus and blood. There was little if any pus, and no sloughs were recognised. There was very rarely any rise of temperature, and the latter was never high. Very little vomiting occurred, but a good deal of mucus was expectorated.

A week after I first saw her I got Dr. Bristowe and then Mr. Pitts to see her with me. Mr. Pitts felt something projecting and pressing inwards the coats of the bowel just within reach of the fingers. Nothing, however, could be made out with certainty about its nature. As all sorts of remedies had been tried without avail, and the tenesmus was extreme and painful, and the motions very numerous, it was thought advisable to do a colotomy. The great tenesmus and large amount of mucus and blood, the pretty advanced age of the patient, the fact that she had never been exposed to conditions likely to give rise to dysentery, and lastly the fact that a projection could be felt far up in the rectum, made us hope that the disease was local, and that if the fæcal matter could be directed the ulceration, if simple, might heal, if malignant, might be dealt with subsequently. On the fifteenth day of her illness Mr. Pitts operated and examined the sigmoid flexure and rectum

Digitized by Google

through an incision in the iliac region. Nothing definite was discovered except that the walls of the colon were thickened and very easily torn. The colon was then opened. There would be no use in recording the subsequent history of the case further than to state that the diarrhœa continued through the artificial anus, that the tenesmus was relieved, and that the patient died three weeks and three days after the operation, *i. e.* in from five to six weeks from the beginning of her illness.

At the *post-mortem* examination no serious disease was found, except in the large intestine. The latter was the seat of ulceration from one end to the other. It will be seen, on examination of the portion of intestine which I show, that the mucous membrane has an irregular worm-eaten appearance. The ulcers are of various sizes, some round, some longitudinal, some quite irregular. Their base is uneven and granular, their edges usually ragged and thin, and some are spanned by arches of surviving mucous membrane. Some involve the mucous and submucous coats only, some the muscular as well. There are, in addition, punctiform orifices through which the products of inflammation probably found their way from below.

The projection from the bowel felt *per rectum* during life was due to one of the appendices epiploicæ, which were of very large size.

The third case which I have to relate is one in which the disease showed itself in a very severe way, and with constant high fever.

E. O—, aged 24, an unmarried girl and general servant, was admitted into St. Thomas's Hospital under my care on September 5th, 1887, and died on October 11th. Her family and personal history revealed nothing of importance; she had always been a perfectly healthy girl.

During the four months which preceded her admission into the hospital she had been getting weak, losing flesh, and had become less able to do her work. All this time she had been very constipated, and had often passed small quantities of blood with her motions. For one month she had vomited pretty constantly after food, and for three days she had violent diarrhœa.

On admission (September 5th) she was still moderately well nourished; her abdomen was slightly distended, and there was a little tenderness in the left iliac fossa. The stools were liquid, dark, and contained neither blood nor mucous.

Pulse was 126, and temperature ranged from 100·2° F. to 103·8° F.

Digitized by Google

in the twenty-four hours. The pulse remained rapid, the tongue became red and dry, stools were very frequent, and sometimes contained mucus, blood, and sloughs. She was sick occasionally, and the abdomen became more distended and tympanitic.

The urine contained one third albumen, but no casts or other evidences of serious kidney disease were found. She gradually emaciated, the diarrhœa remained excessive and uncontrollable, and she had constant high fever. On October 11th sudden collapse with a pulse of 160 occurred, and she died in a few hours.

The following numbers represent the number of stools daily. Early in her illness:—5, 7, 5, 11, 9, 10, 9, 9, 9, 8, 6, 7, 9, 8, &c. In the last week of life:—5, 5, 6, 5, 5, 8.

The following figures represent the highest and lowest temperatures in twenty-four hours. Early in her illness:—100·2° F., 103·8° F.; 100° F., 104·6° F.; 99·2° F., 103·6° F.; 100·2° F., 103·6° F.; 99·4° F., 104° F.; &c. In the last week:—99·4° F., 102·2° F.; 97·2° F., 102·6° F.; 97·2° F., 99·8° F.; 98·4° F., 101·4° F.; 97·6° F., 101·2° F.

Autopsy.—A large rent in the cæcum and acute peritonitis were found, which no doubt gave rise to the fatal collapse. Besides this large hole, innumerable little perforations were found in the floors of the ulcers after the adhesions which they had produced between the coils of intestine had been broken down. The colon was the seat of very advanced ulceration, which was most extreme in the lower half, least in the upper. The cæcum presented large irregular ulcers, with smooth floors and clean edges. Then came about nine inches where the mucous membrane, though pigmented, was comparatively healthy. Just below this the ulceration again commenced. The ulcers were large, irregular, clean-cut. The earlier ones were mostly long, and ran transversely across the bowel, and appeared to have originated between the natural folds of the gut. A large part of the mucous membrane had entirely disappeared, and relics of it alone remained in isolated, irregular islands, dotting the thick white submucous membrane. In some parts more of the internal surface of the bowel was stripped of mucous membrane than was covered by it.

The stomach and small intestines were healthy.

The liver and kidneys were in a condition of extreme cloudy swelling. The other organs were free from disease.

The three cases which I have brought before the notice of the

Digitized by Google

Society to-night are specimens of disease which are not often recorded, or often mentioned clinically. It may be that they are very rare, but my belief is that they are not. It is not unusual to meet with patients who relate symptoms suggestive at any rate of ulcer of the large intestine, such as pain in certain regions of the abdomen, the passage of blood in greater or less abundance and at uncertain intervals, accompanied or not with diarrhœa, and without any severe constitutional disturbance. After a considerable lapse of time they lose their symptoms, and we know nothing for certain of the pathological condition which produced them. These are the mild cases; the severe, and usually quickly fatal cases are represented by those I have spoken about to-night.

The symptoms they present are easily explained by the lesion found. Dr. Allchin reported a case to this Society, which is to be found in the 'Transactions' for 1885; Dr. Hale White has written a paper on such cases in 'Guy's Hospital Reports' for 1888; and there are other references to the subject scattered here and there in medical literature. It seems to me that there is no possibility at present of arriving at the real cause or, probably more correctly, causes which from time to time give rise to the disease. Writers generally assume that it is not the same as true dysentery, basing their arguments partly on the clinical history, partly on the fact that the cases have not lived in foreign countries, and partly on the apparent absence of large sloughs.

Considering how varied the clinical history of true dysentery is, and also the similarity which the older lesions of the bowel in that disease present to the final condition observed in the cases under consideration, I cannot say that I feel convinced that they are not in some instances at least due to the same cause. Meanwhile it seems very probable that many causes of which we are at present ignorant may give rise to an ulceration of the bowel, which sometimes remains local, or even gets well, sometimes rapidly extends and proves fatal.

Clinically, I believe the probability of such a condition as "simple ulcerative colitis" being present is rarely seriously considered when an obscure case of acute diarrhœa presents itself with such accompaniments as have been described in these three cases. At any rate, I have not often heard the disease mentioned at the bedside. Generally, if the patient has not resided in a foreign country, dysentery is eliminated from the diagnosis, and no

Digitized by Google

condition such as ulcerative colitis apart from dysentery is taken into consideration. And although I diagnosed correctly the last case which came under my observation towards the end of last year, I must confess that I went completely astray with regard to the case which I met with in 1887, and which I have described to the Society to-night. As the girl was only twenty-four years of age, and had been quite healthy until this illness, had never been abroad, had a high and intermittent temperature, and evidently had not typhoid fever, I concluded that she probably had tubercular disease of the bowel. I believe that I have seen other cases of the disease, though I have not been able to confirm my opinion by a *post-mortem* examination. In any case I think that although ulcerative colitis may not be a very frequent disease, it is not rare enough to warrant us in neglecting to take it into account at the bedside.

May 19*th*, 1891.

---

16. *Ulcerative colitis.* (*Card specimen.*)

By H. Betham Robinson, M.B.

The specimen was taken from a man aged 66, who for some months had been in a state of debility, but with no definite symptoms except that about one month before admission he had passed blood *per rectum*. Never been out of England.

On admission for cataract extraction he was cachectic-looking, and his urine was slightly albuminous. About three weeks afterwards he had diffuse abdominal pain, not very acute, and there was no marked tenderness except in the left iliac region, where there was some increased resistance over the line of the colon. There had been constipation for two or three days, so the bowels were relieved by enema, a well-formed motion being followed by an acute diarrhœa with plenty of mucus and bright blood. The above symptoms were accompanied by vomiting, which occurred several times. The hæmorrhage from the bowel occurring frequently during the day, from the condition of the patient it was imperative that something should be done to stop it. From the

Digitized by Google

fulness in the left iliac fossa it was presumed that the condition was probably due to malignant ulceration of the sigmoid flexure, and so inguinal colotomy was performed. It was found then that the cause of the hæmorrhage was a large ulcer about two inches by one in the long axis of the bowel, and over the free side of the gut; the base of the ulcer appeared to be practically only peritoneum. As it seemed likely that this would perforate into the abdomen, this segment of gut was brought out of the colotomy wound and fixed there.

No bleeding occurred after the operation, but the patient, who was very feeble, succumbed on the fourth day.

At the *post-mortem* the descending colon was much contracted and thickened, the mucous surface showing several small ulcers with rather punched-out edges, and being covered by flakes of adherent lymph. This change in the mucous membrane extended from the middle of the rectum to the middle of the transverse colon, but it was especially developed in the sigmoid flexure where the large ulcer was. The patient had contracted granular kidneys. Under the microscope the bowel showed no evidence of malignant disease. *May 19th*, 1891.

---

17. *Psilosis or Sprue.*

By Frank J. Wethered, M.D., M.R.C.P.

In bringing this paper before the notice of the Society I beg to offer my thanks to Dr. Thin for allowing me to make use of his notes and to undertake the histological examination of the tissues; and I am also deeply indebted to the proprietors of the 'British Medical Journal' for permission to publish in the 'Proceedings' of this Society an abstract of this case, which appeared in the columns of that journal on June 14th, 1890.

Psilosis, or Sprue, is a tropical disease, occurring chiefly in China. It is characterised by progressive wasting, a peculiar condition of the tongue, looseness of the bowels, and pain on swallowing. The tongue varies much from day to day. In the earlier stages it is

Digitized by Google

preternaturally red on the tip and edges, the latter having a tendency to crack, particularly near the root. Later the tongue is free from fur, smooth, extremely red, and shows no trace of papillæ. Slight superficial ulcers are often seen, but these are extremely transitory.

The motions are very characteristic: they are either of a pale straw yellowish colour, frothy, quite unformed; or they consist of a greyish-white pultaceous mass, often in a state of apparent fermentation, the motion being found covered with froth, and emitting a most offensive odour. On microscopic examination, crystals of the fatty acids are numerous, but it is remarkable the small trace of food matter that is to be seen. This is all the more strange in that milk is the only article of diet that most patients can take; directly anything else is given the motions become more slimy, and the patient grows worse. Yet even if meat has been taken, no trace of it can be found in the stools, indicating that the pathology of the disease is a defect in absorption, and not in digestion.

Though comparatively rarely fatal, the disease ruins the life and prospects of thousands.

The patient from whom these specimens were obtained was one of Dr. Thin's. In the winter of 1887 he was severely chilled by exposure amongst ice, and subsequent travelling in the extreme north of China. In March, 1889, when still in the north of China, he had a severe feverish illness, after which diarrhœa was very marked. He came to England in January, 1890, and unfortunately had a very bad voyage, which added greatly to his already grave condition. On his arrival in England he was seen by Dr. Thin, who found him greatly exhausted and with the characteristic symptoms and signs of sprue. He gradually sank, and died a fortnight after he landed.

I made the autopsy on January 25th, when the following appearances presented themselves. The body was greatly emaciated, and rigor mortis well marked. On opening the abdominal cavity nothing unusual was noticed in the position of its contents; the intestines were of a peculiar brownish-yellow colour. The lungs were emphysematous and rather œdematous. There were evidences of an old-standing pleurisy. The pericardium was adherent, the adhesions being not of recent origin. The heart was small in size and firmly contracted. The mitral orifice was slightly constricted, but no vegetations were seen. The liver was soft and friable, but

Digitized by Google

exhibited no change of structure. The spleen and kidneys were healthy; the pancreas was rather shrunk.

Digestive tract.—The tongue was clean, papillæ rather enlarged, and the epithelium in some places absent. The walls of the œsophagus were a little thickened, but showed no other change to the naked eye. The stomach showed some *post-mortem* digestion, and its surface was covered with an excess of mucoid-like material. The intestines gave a peculiar velvety feel to the hand, as though there was some thickening of their coats. The walls of the duodenum were thin, and the whole of the interior lined with a thick layer of mucoid material, which could be easily scraped off, leaving the mucous coat of the intestine exposed. The walls were so thin as to be perfectly translucent. No other change was apparent to the naked eye. The jejunum and ileum showed similar appearances, the characteristic features being the layer of mucoid-like material and the thinning of the walls. It was this layer that gave the peculiar feel to the intestines described above. Congestion was absent, there being a few patches of injection only. The Peyer's patches could not be made out. Passing to the large intestine, similar changes presented themselves. In the rectum the mucoid-like material was very thick. Nowhere was there any trace of ulceration or deposit of fibrinous membrane.

Microscopic examination.—The tongue: The epithelium was seen to be completely destroyed in some places, the destruction gradually passing into healthy tissue. The muscular layers seemed to be quite healthy.

The œsophagus: Very marked and extensive changes were noticed here: the epithelium was entirely destroyed, and the mucosa densely infiltrated with small round-cells. The inflammatory products were seen to have penetrated to the muscular layer; the submucous coat was thickly packed with exudation-cells, and the glandular substance to a great extent destroyed.

The stomach and duodenum: No abnormal changes were noticed in these.

The jejunum: Effects of the disease were again apparent here. Slight inflammatory action was noticed, as shown by the exudation-cells, and some destruction of the Lieberkühn's follicles.

The ileum: It was here that the most marked changes were found. The mucosa was almost entirely destroyed, being replaced by a structureless substance enclosing leucocytes, and here and

Digitized by Google

there the remains of a follicle. Under a high power it was seen that the epithelium lining the follicle was detached. The submucosa appeared much thickened, and the fibrous tissue abundant and more than usually solid in consistence. The walls of the vessels were also thickened, altogether denoting a more chronic process than in the other parts of the intestinal tract. The muscular layer was thinned.

The cæcum and rectum showed no changes. As is usual with sections of intestine, micro-organisms were found, but they were not more numerous than usual, and no distinctive grouping could be made out. *December 16th*, 1890.

---

18. *Chronic intestinal obstruction from stricture of the ileum, secondary to ulceration produced by strangulation of the bowel in a femoral hernia; death from perforation.*

By G. Newton Pitt, M.D.

[With Plate III.]

The specimen exhibited to the Society was taken from the body of Sarah D—, aged 43, who was admitted into Guy's Hospital under my care on May 12th, 1890. For the last two and a half years she has passed blood *per rectum*, and has had reducible femoral herniæ. Eleven weeks previous to admission she was standing on a chair hanging some clothes, and in so doing strained herself. She felt something give way, and both her ruptures came down. She was in intense pain, and had to be carried to her bed, which she has not left until her admission. She states she has never been well since her confinement in December, when version was performed. The herniæ remained down for a week, after which time they were reduced, the bowels being opened with an enema.

On the fifth day after the accident vomiting commenced, and she has never been free from vomiting since then for any length of time. The vomit now is green or brown, very foul, and almost stercoraceous.

Digitized by Google

The bowels became very irregular; the motions were unformed, slaty in colour, often containing blood. There is always pain in the back with defæcation. The abdominal pain comes on in paroxysms lasting a quarter to half an hour. She has emaciated greatly, and looks moribund.

The abdomen was found to be distended and tympanitic; no tumour was palpable; there was tenderness and pain in the epigastric and right hypochondriac regions. When paroxysms of pain come on the abdominal walls become rigid, and the most marked tenderness is always to the right of the umbilicus. Vaginal and rectal examination reveals nothing abnormal.

She improved greatly with rectal feeding, and regained weight somewhat. Afterwards, although most carefully dieted, it was found that the sickness, after ceasing for a few days, returned as soon as the amount of food was increased, and it was again necessary to still further reduce the amount. Her piles were very painful and bled freely, so that rectal feeding was difficult. The bowels were opened only every second or third day as a rule, and she had increased pain when it was attempted to get them more regular.

It was at first doubtful whether the obstruction was in the large or small intestine, but it appeared from the symptoms more probable that it was in the ileum.

The history of old herniæ and of a troublesome labour suggested that the mischief was possibly due to bands fixing the intestine, or to ulcerative changes set up in the intestine by the hernia; the former appeared the more probable.

The patient's improved condition and the uncertainty as to the lesion decided us not to operate, and later on she refused to undergo any operation. She took Ext. Belladonnæ $\frac{1}{4}$ gr. daily, and occasionally opiates when necessary.

Towards the end of June she became weaker, and died after five days' increasing asthenia with great abdominal pain, becoming unconscious forty-eight hours before death. Although perforation had taken place before death it did not cause any marked symptoms beyond progressive cardiac failure. The first symptoms of obstruction followed immediately on those which had been due to the incarceration of the bowel, and the patient's death occurred four and a half months later.

Inspection.—On opening the abdomen, lines of early peritonitis

Digitized by Google

Digitized by Google

DESCRIPTION OF PLATE III.

To illustrate Dr. Newton Pitt's paper upon Stricture, secondary to ulceration set up by strangulation of the Ileum. (Page 119.)

Extensive ulceration and cicatrisation has taken place at the narrow portion, which had been incarcerated three months previously in a femoral hernia. Above, the ileum is enormously dilated, and a distension-ulcer extends half round the bowel. Perforation occurred at two spots in the distended portion of the bowel, viz. in the small irregular depression on the left hand side of its lower border.

Digitized by Google

P. Huth Lith. Edin.

Digitized by Google

Digitized by Google

are visible along the coils of the intestine, but there is no further evidence of acute peritonitis, and no pus; although in the left iliac region there is a small amount of yellow fæcal fluid. There is also a small amount of fæcal fluid among the coils. The front of the abdomen is occupied by distended coils of ileum, many of which measure four and a quarter inches in circumference; on tracing the ileum down to four feet from the cæcum, the lumen of the bowel suddenly diminishes to its normal size, an inch and a half. At this part there is extensive ulceration with thickening and cicatrisation of the mucous membrane, extending for an inch and a quarter, involving the whole circumference of the bowel, which here was contracted, and measured seven-eighths of an inch. The ulceration is of considerable date; the margins are congested and the floor irregular, being crossed by transverse rounded smooth bands of scar tissue. In this portion there is no actively ulcerating process, but immediately above on the floor of the dilated portion there is an irregular ulcer half an inch wide, extending half round the bowel. This has overhanging edges, and shows no sign of repair. The muscular coat is hypertrophied, the mesentery thickened and fibroid, while on the serous surface there are loose tags of fibrous tissue. Perforation had taken place at two spots in the ulcerated surface at the line where the lumen suddenly enlarges. There was lymph on the surface of the bowel. The femoral rings are both pouched but empty, and there is old blood-pigment on the left one due to previous congestion. There can be little doubt that the bowel had been incarcerated and strangled in the left ring at the time of the sudden attack of pain.

There is an irregular ulcerated patch over an area half an inch across in the cæcum close to the vermiform appendix, and some superficial ulceration in the distal part of the appendix. Microscopically there was only cell-infiltration, and no evidence of tubercle in these ulcers, the nature of which is obscure.

At the apex of the left lung there is a dense fibroid nodule one inch across, with caseous *débris*. Adjacent there are fibroid tubercles, but none of recent date; the rest of the lungs are normal. There is chronic tubal nephritis, the surface of the kidney being also finely granular.

The occurrence of ulceration with a strangulated hernia is not common, and according to Mr. Bryant is more frequent with an inguinal than with a femoral hernia. It is very much more

Digitized by Google

uncommon to find intestinal obstruction ensuing. Treves in his work on intestinal obstruction refers to four out of twenty-six cases of stricture of the small intestine, in which the stricture had been preceded by a strangulated hernia.

Fagge refers to a patient who after an operation for strangulated hernia suffered from continual vomiting, and died two months later. At the inspection, an inch and a half of the intestine was found to be narrowed, and its coats thickened by hard, white cicatricial tissue, while the mucous membrane was almost devoid of villi. Evidently this was the part which had been in the hernial sac.

In vol. xxvii of the 'Transactions' of this Society, on page 161, Dr. Goodhart reports a case in which chronic intestinal obstruction occurred owing to a knuckle of bowel being bound down in an obturator hernia, where it was ulcerated. No stricture had formed, but the obstruction was rather due to the sudden kinking. So far as I have been able to ascertain, no cases of stricture secondary to a strangulated hernia have been recorded in the 'Transactions' of the Society. *April 7th*, 1891.

---

19. *Stricture of jejunum.* (*Card specimen.*)

By H. D. Rolleston, M.B.

Two feet from the duodenum there is marked stenosis of the jejunum.[1] The lumen of the gut is reduced by an approximation of the walls of the bowel, and also by a membranous diaphragm which runs across its lumen. The perforation in this diaphragm barely admits the tip of the little finger. There were two similar though less marked strictures in the neighbourhood of the specimen. They were examined microscopically, but no evidence of tubercle was found. They may be called simple. The existence of the membranous diaphragm suggests that there has been some mal-development of the valvulæ conniventes, possibly congenital, and that the specimen is a stage on the way to the condition of multiple obliterations of the bowel sometimes met with in fœtuses, of which there is a good specimen in St. George's Hospital Museum.[2]

[1] Specimen is in St. George's Hospital Museum, Series ix, 71D.

[2] Series ix, 71A.

Digitized by Google

From a man, aged 25, who died in St. George's Hospital from chronic parenchymatous nephritis. There was no ulceration in the alimentary canal. There was obsolete tubercle in the lungs and caseous glands in the mesentery. *November* 18*th*, 1891.

---

20. *Volvulus in a new-born infant; laparotomy.*

By G. Newton Pitt, M.D.

The specimen is taken from a new-born infant which came under the care of Mr. Lucas, to whom I am indebted for permission to publish the case.

The infant was unable to pass any motions, and was admitted with a distended abdomen. As the rectum was thought to be imperforate, an incision was made in the left inguinal region, and a distended coil of intestine was sutured to the abdominal wall and opened. The child died two days after its birth.

At the inspection the abdomen was found filled with distended coils of intensely engorged ileum. The colon and rectum were normal, empty, and patent. The ileum for two feet above the cæcum was healthy and empty. Above this, but with no very sharp line of demarcation from healthy bowel, such as existed at the upper limit, there commenced a condition of intense engorgement and inflammation. For the next three feet the bowel was almost black from strangulation and engorgement with blood, which had led to thickening of the wall; this area was also the most distended portion of the bowel. At the upper limit there was a sharp line above which the bowel was free from any engorgement or distension, and there was no sign of any linear ulceration or marking such as would probably have been present if the bowel had been constricted by a band. The mesentery presented no abnormality as to length.

A careful search failed to reveal any band or adhesion. On the peritoneal surface of the strangulated bowel there was some lymph; elsewhere the peritoneum was normal. There was no collection of fluid in the abdomen.

There were no evidences of any intussusception. The portion of bowel which had been attached to the left inguinal region was part of the strangled bowel; the spot opened was three feet from the cæcum, and was less engorged than some of the bowel above it.

Digitized by Google

The remaining viscera were normal. Unfortunately the position of the viscera had been disturbed before I saw the condition of the intestines, but I satisfied myself that no band had been cut through, and that a rotation of a dependent loop of ileum round its upper ends was the cause of the strangulation.

In vol. xxxi of the 'Transactions' of this Society Mr. Harrison Cripps brought forward a similar specimen.

The case was supposed to be one of imperforate rectum; a Littré's operation was performed, and the infant died on the third day with peritonitis. The colon was empty and contracted, while a volvulus of the ileum had formed.

So far these two appear to be the only cases of volvulus recorded at this age.

Keating refers to one case at the age of three, but most authors on diseases of children do not refer to any such cases. Cases have been recorded of fœtuses in which portions of the ileum have been found obliterated and reduced to fibrous cords, with obliteration of the corresponding mesenteric vessels. It has been suggested that this condition is due to a volvulus during intra-uterine life, but I am not aware that a volvulus has ever been observed.

---

21. *Ileo-cæcal intussusception with involvement of the duodenum; passage of the cæcum and vermiform appendix from the right into the left iliac region.* (*Card specimen.*)

By Sheridan Delépine, M.B.

The specimen[1] is composed of the contents of the peritoneal cavity, with the exception of the jejunum and greater part of the ileum, which have been removed in order to allow the other parts to be better seen.

The *sheath* is formed by the splenic flexure of the colon, the descending colon, and the upper part of the sigmoid flexure; the *intermediate tube* by the cæcum (with the usual "bourrelet" of ileum), the ascending colon, and the greater part of the transverse colon. The *entering* or *central tube* is composed of ileum. Between

[1] St. George's Hospital Museum.

Digitized by Google

the central and the intermediate tube, *i. e. in the peritoneal sac*, and at the lower end of the prolapsed fold, the appendix vermiformis is found. At the entrance of the same peritoneal sac a portion of the duodenum was also found between the inner and intermediate tubes when the specimen was recent. The part thus most displaced corresponded to the place of junction between the first and second parts of the duodenum, and had evidently been dragged into the sac by the mesocolon.

History.—From a male child, 5 months old, who died with symptoms of intestinal obstruction soon after being admitted into St. George's Hospital.

Remarks.—There is nothing new in the specimen, except perhaps the dragging of the duodenum into the volvulus—a thing which unfortunately is not clearly visible in the preserved state, but was very evident before the organs had been removed from the body. The absence of any lacerations in the peritoneum seems to indicate that the ascending colon and cæcum must have had a distinct and rather long mesocolon.

The obstruction of the duodenum would have rendered the opening of the small intestine perfectly useless as a remedial measure. *October* 21*st*, 1890.

---

22. *Perforation of small intestine caused by a collection of orange pips incarcerated in an inguinal hernia.*

By Bernard Pitts, M.B.

James R—, aged 66, was brought to St. Thomas's Hospital on March 23rd, 1890.

His history was that he had worn a truss from childhood up to the age of twenty-three for a left inguinal hernia. He then left off wearing his truss, and for the next thirty-three years noticed no sign of the rupture returning. Ten years ago, however, the patient was conscious of a small lump in his groin, and this gradually increased in size up till the present time.

During the last seven or eight years the patient had had pain in the swelling at times, and suffered considerable inconvenience from the

Digitized by Google

hernia, but did not wear a truss. For the fortnight previous to admission he had been feeling very unwell, was frequently sick, and his abdomen had become distended. The bowels, however, had been freely opened up to the previous evening.

On examination the man was found to be in a very exhausted state, with distended tympanitic abdomen, and much gurgling in the intestines.

There was a large scrotal hernia on the left side, resonant all over; impulse good; gurgling in the intestine very marked; some tenderness over the inguinal canal, but no œdema or sign of any inflammatory condition; the temperature was normal. The patient was given morphia, and for a few hours he seemed to improve, but the following day he was very sick, bringing up large quantities of most offensive fluid.

On making the incision to explore the hernia I found considerable inflammatory thickening of the deep coverings, and therefore opened the sac as low down as possible, and found a cavity filled with liquid fæces and a collection of twenty orange pips, and apparent grape stalk.

At first I thought adherent bowel had been opened, but on further examination and cleansing of the wound the fæcal collection and the foreign bodies were found to have been in the sac of a congenital hernia, and to have escaped from an opening in the convex surface of a coil of small intestine that had evidently been for a long time adherent at the upper part of the sac. There was no sign of any strangulation, and the bowel was thick and in good condition up to the opening.

A counter opening was now made at the back of the scrotum, and free drainage provided.

For several days the patient greatly improved; the vomiting ceased completely; the distention of the abdomen disappeared, and he took nourishment well. There was, however, a constant discharge of thin yellow fæces from the wound, and the patient became exhausted, and died on the evening of March 30th, one week after the exploration.

In this case an apparently cured congenital hernia had reasserted itself after thirty-three years' interval.

The portion of bowel that came down seems after a time to have become adherent, and the collection of orange pips to have formed very much as occurs so frequently above a stricture of intestine.

Digitized by Google

Such a form of incarcerated hernia is very unusual. There are two cases reported in the 'Pathological Transactions' of foreign body in hernia; one in vol. i, p. 268, when a piece of cinder was found in a strangulated hernia. The hernia had been for a long period irreducible, and the piece of cinder had partially ulcerated through the bowel.

The second case is reported by Mr. T. Smith in vol. xix, p. 228. A child aged one year with an inguinal hernia was brought to Great Ormond Street Hospital with the hernia inflamed and painful. Fourteen days previously the child had swallowed two date-stones. The child was ill and feverish, but with no sign of strangulation. Poultices were applied, and at the end of another fortnight an abscess burst, and the two date-stones escaped. A small fistulous opening in the bowel was left as a sequence.

October 21*st*, 1890.

---

23. *Rupture of vermiform appendix.*

By Arthur Voelcker, M.D.

The vermiform appendix is adherent, bent on itself, and has ruptured about its middle. The edges of the rupture were grey and gangrenous. A small fæcal mass the size of a hemp-seed was found attached to the edge of the gangrenous portion. There was general purulent peritonitis.

From a boy, $4\frac{3}{12}$ years old, admitted to the Hospital for Sick Children under the care of Dr. Sturges.

On December 10th, 1890, quite well; two hours after tea, sharp pain all over the abdomen; given aperients.

11th.—Better, some pain. Bowels not open.

12th.—Small slimy motion with no blood, after more rhubarb. Improvement till—

15th.—Sudden return of pain.

16th.—Vomited for first time.

17th.—Admitted to H. S. C. with signs of general peritonitis.

18th.—Died. No history of any injury.

March 17*th*, 1891.

Digitized by Google

24. *Vermiform appendix in a case of general acute peritonitis.*

By Arthur Voelcker, M.D.

The vermiform appendix is somewhat constricted at its entrance into the cæcum, but beyond is tensely distended. Some lymph on its mesenteric border and a pale patch at the apex. No adhesions and no obvious perforation. The vermiform appendix has been slit up; the lumen is almost entirely obliterated by the swollen mucous membrane, which is greyish in colour. Near the tip was a minute collection of pus in the mucous membrane, but the peritoneal coat was not perforated.

No foreign body found. No evidence of tubercle in the body. The intestines were covered with lymph. There was general purulent peritonitis, but no fæcal extravasation. Peyer's patches not much enlarged.

From a boy, aged 5, admitted to the Hospital for Sick Children under Mr. Morgan.

A few days before admission the boy came home crying, and said he had been knocked down. The next day he seemed all right, but on the subsequent day had abdominal pain and vomiting.

He was admitted on October 28th, 1890, in a moribund condition; temp. 102°, and died in a few hours.

March 17th, 1891.

---

25. *A case of fæcal fistula at the umbilicus with non-development of sigmoid flexure and rectum.*

By William Anderson, F.R.C.S.

The patient from whom the specimen originated was a male child of healthy parentage, prematurely delivered at the end of the seventh month of pregnancy, on the 21st of December last. Dr. M. M. Campbell, of Forest Hill, to whose kindness I am indebted

Digitized by Google

for the early history of the case, tells me that after tying and cutting the umbilical cord he noticed a red tumour of nævoid aspect at the line of section, and perceived that the proximal end of the cord was considerably enlarged. Not feeling certain as to the nature of the tumour, he excluded it from the ligature, but no examination was made of the portion of the cord attached to the placenta. On the following day he discovered that meconium was escaping from the umbilical stump, and also that there was no trace of anal aperture or depression. The child was sent to St. Thomas's Hospital on the 1st of January. He was then of normal weight and size, but somewhat feeble. At the umbilicus was a fæcal fistula, the orifice of which presented a red everted mucous membrane like that of small intestine. The anal region was devoid of any aperture or dimple, and there was no evidence of the existence of a rectum. After admission the various functions were discharged naturally, food was taken well, and the bowels were relieved through the umbilicus at ordinary intervals and without setting up any cutaneous irritation in the neighbourhood; but the child lost flesh and strength rapidly, the temperature fell to an average of little more than 95°, and death took place on the twenty-third day after birth.

The *post-mortem* examination by Dr. Hawkins showed as the probable cause of death hydronephrosis of the left kidney, and imperfect development of its fellow, with dilatation of both ureters. The other organs except the intestine were normal.

The small intestines were well developed, but an inch and a quarter from the cæcum was a prolapse of the ileum through the umbilicus, the gut being firmly attached to the margins of the aperture. The short distal portion of the ileum, extending to the cæcum, was empty and contracted, while the proximal portion was filled with fluid fæces. The fistulous opening at the umbilicus was single, and a probe introduced into it could be passed freely into the ileum in both directions. The large intestine was represented by a capacious and well-formed cæcum, with a short vermiform appendage, and a wide tube extending in the course of the ascending transverse and descending portions of the colon as far as the crest of the left ilium, there terminating in a conical blind extremity. The sigmoid flexure and rectum were unrepresented.

There is little doubt that the umbilical protrusion consisted of a kind of Littré's hernia, a portion of which had been cut off and

Digitized by Google

removed with the placental end of the cord. Its adjacency to the cæcum makes it very probable that the hernia was actually a persistence of the condition which normally obtains during the early periods of fœtal life, viz. the passage of the loop of intestine which is connected with the vitelline duct into the attachment of the umbilical cord, enclosed in a protrusion of the parietal peritoneum; but the absence of examination of the placental portion of the cord makes it impossible to be certain on this point.

The case was not one in which immediate surgical interference was to be entertained, but had the child survived, as it probably would have done save for the renal complication, it might have been a matter for consideration whether a colotomy should be performed as a preliminary to an operation for closure of the umbilical fistula. In the light of the autopsy it will be seen that the large intestine could only have been reached in the right inguinal or lumbar region, and that a search for the sigmoid flexure would have failed. The chief interest of the case, however, lies in its probable relation to the normal hernia of the fœtus, and in the lesson it conveys to obstetricians to leave a long stump when dividing the cord, especially in premature births. *April* 21*st*, 1891.

---

26. *Lipoma of spermatic cord with hernial sac.*

By E. W. Roughton.

The specimen now shown was taken from a dissecting-room subject. On the front of the spermatic cord is seen a circumscribed mass of fat about the size of a small walnut. Careful examination shows that this lipoma is continuous with the subperitoneal fat in the neighbourhood of the internal abdominal ring by means of a slender pedicle. Immediately behind the lipoma, but not extending so far down the cord, there is an elongated hernial sac barely large enough to admit the index finger. When traction is made upon the lipoma the hernial sac descends with it, and the peritoneum close to the neck of sac becomes wrinkled.

At the time of dissection the hernial sac was empty, and no portion of the abdominal contents looked as if it had escaped

Digitized by Google

through any opening. There was no elongation of the mesentery at any part.

In this case I think it probable that the lipoma of the cord originated in the subperitoneal fat at or near the internal abdominal ring, and travelled down the cord, drawing with it a hernial sac. This view is also strengthened, in my mind, by several other dissecting-room subjects I have noticed, presenting small masses of subperitoneal fat at the femoral and inguinal rings in association with depressions of the peritoneum passing over those apertures. In the thirty-seventh volume of our 'Transactions' Mr. J. Hutchinson, jun., has recorded similar cases and adopted this theory. I can offer no suggestion of any value as to the reason why lipomata should arise in the subperitoneal fat and travel down the spermatic cord. *May* 19*th*, 1891.

---

27. *Duodenal pouch.* (*Card specimen.*)

By H. D. Rolleston, M.D.

The specimen shows the second part of the duodenum laid open, the pancreatic duct, the common bile-duct, cystic duct, and gall-bladder. Coming off from the left side of the duodenum is a pouch the size of a walnut; the floor of the pouch has the common bile-duct running along to open normally at the papilla. The papilla is situated just within this pouch. There is no sign of any ulceration. The common bile-duct is dilated. The gall-bladder is thickened and empty. There was a Meckel's diverticulum coming off from the ileum thirty-four inches from the cæcum.

From a woman, aged 74, who died of senile gangrene in St. George's Hospital. *October* 21*st*, 1890.

Digitized by Google

28. *Obstruction at the ileo-cæcal valve caused by a carcinomatous tumour growing from the ileo-cæcal valve; remarks. (Card specimen.)*

By Francis H. Hawkins, M.B.

This specimen was removed from the body of a man aged 75, married, a musician by occupation, who had been in fairly good health till within eight months of his death, when he noticed that he was losing flesh, and that he had some trouble with his bowels. He, however, continued at his employment till six weeks before his death, when, owing to increasing weakness, he was obliged to take to his bed. At this time the patient commenced to vomit; the vomited matter consisted of food, and no fæcal odour was noticed till within three days of his death. The bowels moved with difficulty, the fæces being small and narrow, but the stools were mostly of a liquid character.

The patient was much emaciated. The abdomen was distended, more anteriorly than laterally, and was divided into longitudinal ridges, which were continually altering their position, their motion being very apparent. The veins were not enlarged. There was on palpation no sense of resistance other than what could be accounted for by distended intestines. The percussion note was tympanitic over all regions. Physical examination did not give any signs of disease in any organ.

Post-mortem (forty-eight hours after death).—Height, 5 feet 4 inches. Circumference round shoulders, 45 inches. Emaciation general and extreme. No œdema. Rigidity not marked. Abdomen much distended; umbilicus slightly everted; superficial veins not distended; no glandular enlargements.

On opening the abdomen the intestines were observed to be much distended, and to occupy the whole of the abdominal cavity, so that neither stomach nor liver could be seen. On closer observation it was noted that the greatly distended intestines consisted of the jejunum and ileum; the colon could not be seen until the other intestines were drawn forwards, when the ascending, transverse, and descending colon was seen to lie far back in the abdominal cavity, and the lumen was observed to be small.

Digitized by Google

On examining the right iliac region a firm mass was felt, which was in the lumen of the bowel in the region of the juncture of the ileum with the cæcum, and felt about the size of a walnut. The external relations of the bowel at this part were normal.

On removal of the intestines the walls of the jejunum and ileum were seen to be much hypertrophied; and the lumen, enormously enlarged, was full of liquid fæces. The cæcum was rudimentary, with some puckering of the posterior surface. The wall of the colon was thin and the lumen narrow. The opening between the ileum and the cæcum was obstructed, admitting a No. 11 catheter. The part of the bowel in front of the catheter consisted only of intestinal wall, while there was a considerable space posteriorly between the catheter and the external surface of the gut.

On opening the bowel anteriorly a tumour was seen, which occupied the posterior part of the ileo-cæcal valve, measuring about three quarters of an inch in length. The anterior surface of this tumour was smooth; its extremities were smooth and rounded, the extremity looking towards the cæcum being narrower than the extremity looking towards the ileum. At the back of either extremity a diverticulum was formed in the ileum and cæcum respectively. The tumour is firm in consistence. Microscopical examination gives an alveolar network with epithelial cells, which are mostly spherical in shape.

There were no secondary deposits in any organ or glands. The other organs presented normal appearances.

Remarks.—Obstruction at the ileo-cæcal valve is not common, while obstruction due to a morbid growth of the ileo-cæcal valve is less common. Dr. Wickham Legge, in the 'Transactions' of the Society for 1870, describes a case in which the opening from the ileum into the cæcum was only just large enough to admit a No. 9 catheter, and he suggests that the stricture was congenital. Six other cases are referred to, somewhat similar to the one described by Dr. Legge. Of these six cases one only occurred in British literature.

Dr. Angel Money, in the 'Transactions' for 1889, describes a case of a man aged sixty who died from obstruction of the bowels, and at the autopsy malignant disease (columnar epithelioma) was found affecting the ileo-cæcal valve. In this case there were secondary deposits in the "mesocolic glands, liver, and lungs." The case was also complicated by a post-cæcal abscess. This is the only

Digitized by Google

case that I can find in the 'Transactions' of the Society of malignant disease affecting the ileo-cæcal valve.

Dr. Samuel Fenwick, in 'Obscure Disorders of the Abdomen,' mentions three cases in which a stricture was found at the ileo-cæcal valve—one case in a man aged forty, and two cases in women aged respectively twenty-seven and twenty-nine. Dr. Fenwick mentions that in looking over the *post-mortem* examinations made at the London Hospital he has only found one case (other than those above mentioned) of stricture at the ileo-cæcal valve. As this case bears some analogy to the one now exhibited I record it here.

"No history of the case can be found; the account merely states that a sailor, forty-five years of age, died in July, 1851, and the ileo-cæcal valve was obstructed by a scirrhous growth completely surrounding the intestine, and leaving an aperture through which only a crow-quill could be passed. The large intestine was contracted; the small intestines were distended with fluid and flatus. The muscular coat was much thickened."

Dr. J. S. Bristowe, in writing upon "Obstructive Disease of the Ileum" in the February number of the 'American Journal of Medical Science' (1891), records in all five cases of obstruction at the lower part of the ileum, but one case only was caused by obstruction at the ileo-cæcal valve itself. That case was of a man aged eighteen years, a painter, in which at the autopsy a hard mass was felt in the upper part of the right loin, lying under cover of the liver, and on the anterior surface of the right kidney. The hard mass was on further examination found to be due to a growth (originating in the situation of the ileo-cæcal valve, but involving "both the ileum and the cæcal walls in the immediate neighbourhood"). The tumour was annular in form, with a narrow channel of about two inches in length, and allowing the passage of the little finger in its axis. The ileum was greatly distended. It was a round-celled sarcoma.

Mr. Bland Sutton, in the 'Middlesex Hospital Reports' from 1884 to 1886, records a most interesting case of malignant disease of the ileo-cæcal valve. The case was that of a man aged sixty, married, who worked in a piano factory. Three months before admission noticed difficulty in defæcation, and that the fæces were not larger than the little finger. A few weeks later the difficulty of defæcation increased, and there was pain and swelling of the

Digitized by Google

abdomen. During the last seven weeks the symptoms have continued. The motions have generally been diarrhœic and puriform. At the autopsy there was extensive epitheliomatous infiltration of the whole of the circumference of the gut at the ileo-cæcal valve and in the adjacent parts. The gut above the seat of stricture was dilated.

The case now exhibited before the Society differs from any of those above mentioned in the growth not being annular, and it differs from that recorded by Dr. Angel Money in having no secondary deposits, while in this respect it agrees with the cases recorded by Dr. Bristowe and Mr. Bland Sutton.

This specimen is now in the museum of the Royal College of Surgeons. *April* 21*st*, 1891.

---

29. *Intestine and liver from a case of ankylo-stomiasis.* (*Card specimen.*)

By Beaven Rake, M.D.

B., aged 40, Hindu, was admitted to the Trinidad Leper Asylum on July 24th, 1890, with anæsthetic leprosy of several years' duration. She was extremely weak and anæmic, and steadily got worse. Great œdema of hands and forearms set in. Ankylo-stomiasis was diagnosed, but thymol failed to give relief. She died on September 5th, 1890.

Necropsy showed swarms of *Ankylostoma duodenale* in duodenum, fewer in jejunum, and very few in ileum. Large quantities of dark tarry blood in lumen of bowel down to ileo-cæcal valve.

Liver 27 oz., fatty and very anæmic. Spleen 4 oz., normal. Microscopic sections of the spleen and liver appear normal, except that the liver shows excess of oil globules. Potassium sulphocyanide shows a pale red coloration, especially at periphery of lobules. Ferrocyanide shows merely a darkening of colour; no blue coloration.

Mr. Carmody, Government Analyst in Trinidad, was kind

Digitized by Google

enough to estimate the iron in the liver and spleen, and found it ·26 per cent. in the former and 3·28 per cent. in the latter.

The low percentage of iron in the liver in cases of ankylostomiasis shows that this organ, like other parts of the body, becomes intensely anæmic in consequence of the loss of blood from the intestine. In another case of ankylo-stomiasis examined by Mr. Carmody and myself we found only a trace of iron in the liver.

This is in contrast to ordinary pernicious anæmia, in which considerable blood destruction appears to go on in the liver, greatly increasing the percentage of iron in that viscus.

October 21*st*, 1890.

---

30. *Papillomatous growth, containing the ova of the Bilharzia hæmatobia, removed from the rectum.*

By Anthony A. Bowlby.

This specimen was removed by Dr. Mackie from the rectum of an Arab lad, aged 17, who had for some time suffered from rectal pain and passage of blood *per anum*. A digital examination revealed the presence of a diffuse papillomatous growth, a considerable mass of which was removed entire. The growth is about as large as the end of the thumb. Its surface is papillary, its base of attachment narrow, and its substance soft and friable.

The microscope shows that it is composed of loose fibrous tissue rich in cells, and evidently of inflammatory origin, in whose meshes are large numbers of the ova of the Bilharzia.

---

31. *Three cases of imperforate rectum.*

By Stephen Paget, F.R.C.S.

Case 1.—A small, feeble male infant, thirteenth in the family, and hand-fed. There was an anal cul-de-sac; but the child was so weak and ill that I did a left inguinal colotomy, fearing that I might

Digitized by Google

have to make a prolonged dissection if I tried to reach the bowel through the cul-de-sac. Ten days later I passed a director down the bowel through the colotomy wound, and was able to push the cul-de-sac right out through the anus, director and all, and to incise it on the director. The baby did well for a time, but then began to fail, and died when five weeks old.

Case 2.—A small male infant, three days old. No trace of anus or of cul-de-sac; a faint raphe from scrotum to sacrum; just behind the scrotum a little tubercle or tag of skin, such as sometimes occurs along the course of a branchial cleft. In a case of median hare-lip, shown by Mr. Pitts at the Medical Society, there was just this sort of tag of skin at the angle of the cleft in the lip. A deep dimple over the sacrum; a very small and narrow pelvis.

I made a median incision, and dissected down, keeping well back, close to the sacrum. At the depth of three quarters of an inch I came to a strong close-knit fibrous membrane, the direction of its fibre being transverse to the wound. In the course of a minute or two this was seen to descend nearer to the surface. I opened it, dilated the opening, dragged down the gut and stitched it in the wound, and put in a tube. Four days later the baby died with signs of suppression of urine.

Post-mortem.—Only one kidney; the right kidney was only a flat scrap of soft tissue, weighing a few grains; no right ureter.

Case 3.—A male infant, thirteen days unrelieved. I failed to open the bowel in the cul-de-sac, and passed into the peritoneal cavity. I therefore made a small median incision above the pubes, and attached the dilated bowel here and opened it, but the baby never rallied, and died two days after the operation.

Post-mortem.—There was a little peritonitis round the opening into the bowel, but no extravasation of fæces. There was a Meckel's diverticulum of the small intestine.

Remarks.—It is a matter for much regret that these three cases were all unsuccessful. The first was a thirteenth child, very feeble; but the operation by way of the cul-de-sac might have saved its life. In the second case the operation was easy, and the child was vigorous, but it had only one kidney, and it died with suppression of urine. In the third case the child had been vomiting without relief for thirteen days.

I cannot add any remarks of value to Mr. Curling's classical paper

Digitized by Google

on this subject ('Med.-Chir. Trans.'). The existence of other malformations in two of my three cases is worthy of note.

February 17*th*, 1891.

---

32. *Rupture of liver; partial repair.* (*Card specimen.*)

By H. D. Rolleston, M.D.

There is an extensive rupture of the convex surface of the right lobe. The torn edges are united together by lymph, except on one place where there was recent clot. The diaphragm opposite the rupture also had adherent lymph on its under surface, so that the ruptured liver had become repaired by adhering to the diaphragm. Inside the liver in the region of the rupture is some firm decolourised clot.

From a man aged 60 years, who after a fall of thirty feet was admitted in a state of collapse to St. George's Hospital on July 8th, 1890. He had hæmaturia, but otherwise went on well till July 15th, when he suddenly felt faint, rapidly sank, and died.

At the *post-mortem* 13 oz. of recent clot and a good deal of fluid blood were found in the peritoneal cavity. There was also a rupture of the right kidney. The other viscera were uninjured.

November 18*th*, 1890.

---

33. *Pylephlebitis suppurativa consequent on perityphlitis. No symptoms pointing to the liver. Parotid swelling a fortnight before death subsiding without suppuration.*

By Samuel West, M.D.

Frederick K—, aged 24, a printer's engineer, was admitted into St. Bartholomew's Hospital for pain in the right iliac fossa. He gave the following history:—that he had been in good health until the 4th of August, when he was suddenly seized with pain in

Digitized by Google

the right iliac fossa, of a darting, stabbing character, attended with some diarrhœa. For this he stayed at home for a day, and then tried to go back to work, but found himself unfit for it. From this time he remained at home, suffering the same pain, but never severely enough to be obliged to lie up entirely. Constipation continued from the 5th until relieved by an enema on the 15th. He had never had any attack at all like the present, and there was nothing of importance in the family history.

On admission the man did not appear especially ill, was fairly well nourished, and not in much pain. The temperature was only 100°, the pulse 88. All the organs seemed healthy, and there were no physical signs except a swelling the size of a small Tangerine orange in the right iliac fossa, which was only slightly tender, smooth, but not dull on percussion. Beyond occasional sweatings there was nothing to attract attention. During the next ten days improvement took place, but the sweating continued. The temperature was moderately raised and of a hectic type.

From the 27th onwards the patient seemed to gradually lose ground, although the local swelling had almost entirely disappeared. The sweats and hectic temperature continued. On the 31st a swelling developed on the right side in the parotid region, which was very tender and hot, and looked as if it would suppurate; but it did not, and in three days began to subside, and had disappeared the 10th.

All this time the patient had been rapidly going downhill, and had lost much flesh and strength, until on September 10th he seemed to be almost dying, having become suddenly much worse. A careful examination was made to see if any new mischief could be discovered, but without success. The only suspicion that seemed justified was that there was some deep-seated suppuration, probably in connection with the old mischief round the cæcum, and the advisability of an exploration was again considered, as it had been already considered on previous occasions. The hectic was now more marked, but on the 10th operation was clearly out of the question on account of the collapse. On the 13th he had somewhat rallied, and in consultation with Mr. Langton it was decided that an operation offered the only chance of life, though but a slender one. Ether was then given, and an incision made in the right linea semilunaris. The coils of intestine were found matted together, but no pus was found round the vermiform appendix or cæcum. After breaking down

Digitized by Google

some adhesions along the ascending colon a small pocket of pus was opened. This was washed out, but the patient then became so alarmingly weak that the operation was concluded as quickly as possible and the patient removed to the ward, where he died a few hours later, having never rallied from the operation.

The *post-mortem* examination showed that the only seat of disease was in the abdomen. The intestines were all matted together, the adhesions being most complete round the cæcum, ascending colon, and sigmoid flexure. Beneath the liver all the parts were matted together, and in the lesser omentum an abscess was found, which on dissection proved to be the greatly distended portal vein. This was filled with pus, but contained no blood. The branches of the portal vein in the liver were also filled with pus, and likewise contained no blood. The splenic and the mesenteric veins were normal. No clot was found in any part of these veins or in the portal vein, while the hepatic veins and the vena cava were in all respects normal and filled with blood.

The liver was of the usual size, and did not appear diseased before it was cut into, when abscesses were seen, which proved to be the branches of the portal vein distended with pus.

The dissection destroyed the liver as a specimen for exhibition, but microscopical sections were made and are now shown.

The central vein in many of the lobules is found full of pus-cells, the coat remaining distinct and the cells of the lobule round being unaffected. In others the pus-cells have invaded the coats of the veins, so that the muscle-cells are separated from each other. In these cases the liver-cells round are compressed and flattened, granular, and evidently undergoing disintegration from pressure. In other parts the pus has extended outside the vein, so that a diffuse abscess is in the process of formation in the liver tissue. The process has, however, hardly anywhere gone so far that the origin of the suppuration cannot be traced to the portal vein. All the larger collections of pus are contained in the chief branches of the portal vein, though it is evident that in the course of time, if the patient had lived, the ordinary form of pyæmic abscess would have been met with and probably predominated.

Pylephlebitis is a remarkable disease, and this is a typical instance of it. This case developed in connection with suppuration in the region of the cæcum, as is usual, and presented no symptoms of so grave an affection other than hectic fever, repeated sweatings, and

Digitized by Google

rapid loss of flesh and strength, *i. e.* the ordinary signs of suppuration or pent-up pus. All hepatic symptoms were absent; and, what is most of all remarkable, there were, as is also the rule, no signs whatever of the portal obstruction which existed, an obstruction so complete that the pus was not even coloured with blood. In this case it is noteworthy that no disintegrating clot could be found at the time of death in any of the main radicles of the portal vein, though we are almost forced to suppose, on the evidence of other cases, that the pus owed its origin to such a source.

I suppose that the functions of the liver must have been immensely impaired, if not entirely abolished, and that for some time before death. Such a case as this, in association with those of large hydatids, tropical abscess, and even cirrhosis, shows to what an extraordinary extent disease may destroy or impair the liver, and yet the patient continue to live.

The association of parotid swelling with the abdominal lesions is of interest, and was the object of an instructive paper by Mr. Stephen Paget a year or two ago. The swelling threatened to end in suppuration, as so commonly occurs; and it is interesting to note that in this case it subsided without the formation of an abscess. What the connection can be between the parotid swelling and abdominal disease it is hard to conceive, yet the association is too frequent to be a mere coincidence.

---

34. *Extensive gummatous lesions of the liver, diaphragm, lung, and spleen.*

By Sheridan Delépine, M.B.Edin., B.Sc.Lausanne; and Richard Sisley, M.D.Lond.

Preliminary Remarks.—We are indebted to Mr. Rouse for permission to publish this case, and to Mr. Bull for the use of his excellent clinical notes.

I. *History.*

The patient had been a police constable. His age was 43. He gave no history of heritable disease.

In 1861, *i. e.* twenty-five years before death, he suffered from

Digitized by Google

gonorrhœa, from which he completely recovered. Some months afterwards he had a chancre, followed by a bubo in the left groin; this was opened. Later the man had sore throat.

In 1864 a swelling formed over his right tibia; this gradually increased in size.

The patient continued to serve in the police force till 1871, when he lost power in his left arm and leg. He was under treatment for eleven weeks, and recovered sufficiently to do his work again till 1876, when he had another attack of paralysis in his left leg and arm. He was then superannuated from the police force. From 1876 he "dragged his leg" when he walked. A month before he came to St. George's his right leg began to swell.

The patient took little alcohol.

His wife had had four miscarriages, and had borne no living child.

The man came into the hospital February 1st, 1886. He then complained of swelling in the left leg and of inability to walk.

Lung: On the right side of the chest, dulness commenced at the upper border of the fifth rib.

Liver: Hepatic dulness extended downwards about two inches below the ribs, and to the left side as far as the spleen. The hepatic surface felt quite smooth.

Spleen: In the left hypochondriac region there was a nodular mass which extended downwards to the crest of the ilium.

Leg: There was much thickening of the left tibia at its upper third. There was an ulcer on the inner side of the left leg.

Urine: No albumen; sp. gr. 1020, clear, neutral.

Whilst under observation the patient suffered much from bronchitis and epistaxis.

A rupial eruption appeared in his left leg. On March 18th erysipelas commenced at the seat of the eruption, and spread upwards.

Bedsores formed over the man's sacrum, he became delirious, and died on March 20th, 1886.

II. *Post-mortem Examination.*

The autopsy was made twenty-three hours after death.

1. *External appearances.*

The height was six feet, the body thin, the hair dark and grey.

Digitized by Google

There were bedsores over the sacrum and over the great trochanter of the femur. There were some scabs on the right leg, on the inner side of the right foot, and on the inner surface of the left leg.

2. *Thorax.*

The left pleura contained about three quarters of a pint of straw-coloured fluid. There were adhesions on the right side, at the axillary border posteriorly, and below to the diaphragm.

The *left lung* weighed 3 lbs. 4 oz. There was a deposit of inflammatory lymph on the visceral surface of the pleura. The lower lobe was deeply congested and partly consolidated; the consolidation was in patches as in catarrhal pneumonia. Some of these masses looked as if they were purulent, some fatty or caseous. The largest measured 3 mm., the smallest barely ½ mm. Each patch or nodule was surrounded by a deeply congested zone. Immediately under the pleura there was a network composed of ramified tracks, having an appearance similar to that of the smallest of the patches in the lung. The appearance suggested lymphatics distended with cells or some fatty products. The surface of the pleura itself was puckered, the depressions being filled up with lymph. Between the catarrhal patches the lung parenchyma was apparently simply congested and œdematous, and in places emphysematous. The emphysema was most marked along the anterior and lower borders of the lobes. In many places there were small hæmorrhages. The bronchi were full of muco-pus.

Microscopical examination of the left lung.—Under the microscope the lobular or patchy character of the consolidation was very distinctly seen in some places, whilst in other parts larger tracks were found to be occupied continuously by exudation. The general congestion was very evident. When the lesions were examined in detail the following points were found.

(*a*) *The pleura* was covered with recent lymph containing very few cellular elements, but on the immediate surface of the serous coat there was an almost continuous layer of epithelioid cells, evidently the result of an active proliferation of the pleural endothelium. The subserous layer of the pleura was unevenly thickened, its blood-vessels and its lymphatics considerably enlarged, especially the latter. Where the fibrous tissue was in excess it was composed of very clear bundles of white fibrous tissue of homogeneous

Digitized by Google

appearance, and with comparatively few cellular elements. This tissue was at places much infiltrated with carbon. The interlobular and interalveolar septa were similarly affected, and some of them were much thickened. The distended lymphatics corresponded to the yellow patches and ramified tracks already described. They contained chiefly cells, among which it was possible to recognise here and there lymphatic corpuscles, red blood-corpuscles, and a few large fatty cells. In most parts there was an imperfect network of degenerated fibrine, granular *débris*, and small rosettes of crystals of doubtful nature; similar patches were found all through the lung, but more specially round vessels of medium and large size—that is to say, in the perivascular portions of the interlobular septa. Notwithstanding the large size of some of these masses they did not seem to press on the vessels. The peribronchial tissue was not affected in the same way. Some of the masses came in contact with the walls of some of the bronchi, but this was owing to proximity of the latter to the vessels.

(*b*) *Blood-vessels.*—The chief points worth noticing besides the intense congestion and distension of the perivascular lymphatics already alluded to was the presence of an unusual number of leucocytes, rounded cells of granular appearance larger than leucocytes, and in some places a large number of small nucleated corpuscles, forming here and there small clumps within vessels the endothelium of which was in a state of proliferation and desquamation. In many places the blood was coagulated, and in one or two instances cells infiltrated with carbon seemed to have penetrated into the lumen of the vessel. There was a certain amount of thickening of the intima of some vessels, in others there was no thickening.

(*c*) *Bronchi.*—Some of the terminal bronchi were dilated, others contracted; they were generally filled up with catarrhal products.

(*d*) *The alveoli and alveolar passages*, like the terminal bronchi, were either dilated or reduced in size by pressure. Those which were dilated were either empty and emphysematous, or more frequently filled up with blood, granular *débris* (products similar to those found in the lymphatics), and catarrhal pigmented cells. Whether the alveoli were dilated or contracted, empty or filled with exudation, their walls were in most places congested, and lined with prominent epithelium in a state of proliferation. In addition to the products mentioned above, amyloid bodies were found in

Digitized by Google

a few of the alveoli. No lardaceous reaction was obtained in the organ.

Right lung.—The upper lobes of the right lung were very much in the same state as the upper lobe of the left (the lower parts of these two lobes were slightly invaded by the cheesy mass). The lower lobe, in addition to changes similar to those observed in the left inferior lobe, was completely adherent to the diaphragm, displaced upward and partly destroyed by an extension into its substance of a large caseous mass which occupied the upper part of the liver, and replaced the parts of the diaphragm which separated the lung from the liver in that region.

At the upper margin of the caseous mass there was much fibrous induration and exudative consolidation of the pulmonary tissue; in the cheesy mass itself the limits of the base of the lung were indicated by a large amount of carbon pigmentation.

The whole lung was in a state of intense congestion, and indurated to a greater extent than the left lung. There was a small amount of emphysema. The bronchi were thickened.

Microscopically.—The only parts which call for special description are those adjoining the caseous mass, where the lesions found may be summed up as follows:

There was considerable fibrosis, due to extension of the connective tissue forming the margin of the cheesy mass along the interlobular and interalveolar septa; but where the tissue formed large tracts it was found very vascular, and to contain patches of round-cells smaller than ordinary leucocytes. The nuclei of the cells stained very deeply. In order, however, to give a clear idea of the changes observed it will be convenient to admit the existence of three zones at the margin of the caseous mass.

1st. Zone where the lung parenchyma had retained its characteristic features.

2nd. Zone where the structure of the organ could still be recognised in some places, but was so altered that it could only be made out by tracing the continuity of its parts with those of the first zone.

3rd. Zone where no trace of lung structure could be found.

In the first zone the changes were similar to those observed in the left lung. There was, however, no marked distention of the lymphatics, and exudative changes were almost entirely absent. The chief lesions were those produced by chronic interstitial

Digitized by Google

inflammation, or in other words, fibrous induration. Catarrhal changes were present here as in the other lung; congestion was well marked; the blood contained an excess of leucocytes, and especially of small nucleated corpuscles. There was also in many parts abundant desquamation of the endothelium. It was in the *second zone* that the most interesting and typical changes were observed. There the increase of fibrous tissue was so great that the alveolar cavities and the bronchial and alveolar passages occupied less space than the interstitial tissue. This altered the appearance of the parenchyma so much that, except for the direct continuity of these cavities with those found in the upper zone, it would have been impossible to recognise the nature of the organ. The new connective tissue was very cellular, and was chiefly composed of spindle and branched cells, in the midst of which were aggregations of small lymphoid cells (similar to the small nucleated corpuscles found in the blood-vessels). Among these cells there was much carbon pigment. In some places the cellular connective tissue projected into the neighbouring alveoli in the shape of small polypoid masses. The terminal bronchi were much stenosed, owing to the new formation of connective tissue in the mucous, submucous, and peribronchial coats. Owing to this increase of interstitial tissue the muscular layer was much atrophied. There was almost complete obliteration of nearly all the alveolar passages and alveoli. The walls of a large number of these contracted passages and cavities were covered with small cubical or columnar epithelium, which was in a state of proliferation. Some alveoli contained large, pigmented and non-pigmented, catarrhal cells which entirely filled up their cavities. In addition to these cells small lymphoid corpuscles were found, and there were large multinucleated cells, which resembled giant-cells in structure and shape, but differed from them in being found free within the alveolar cavities. *The similarity between the lesions just described and those found in the pneumonia of inherited syphilis is very striking.*

In the *third zone* no trace of lung tissue could be discovered. The only evidence of the previous existence of any such structure in that region was the presence of a few patches of carbon particles, but even these were not abundant. The chief feature of the tissue found in that zone was its dense and lamellated appearance. It was composed of clear homogeneous layers of fibrous stroma, separating small flattened corpuscles which stained deeply. In

Digitized by Google

some places there were small aggregations of lymphoid cells, which also stained deeply. This was the tissue which became gradually caseous. This was well shown by the gradual disappearance of the nucleated cells and the degeneration of some of the tracks of lymphoid cells, some of which seemed to acquire a considerable size. Thus although the caseous mass covered part of the area normally occupied by the lung, yet it could not truly be said that it was formed in the lung tissue itself. It was produced in the fibrous connective tissue which had taken the place of a certain portion of the pulmonary tissue.

The larynx and trachea were congested.

Heart.—There was an excess of fat in the course of the coronary arteries. The cavities of the right side of the heart contained a light-coloured clot. The edges of the mitral and tricuspid valves were slightly thickened; so were the attached margins of the aortic and pulmonary.

The aorta contained some small patches of atheroma.

3. *Abdomen.*

The peritoneum was healthy.

The spleen was considerably enlarged, and weighed 2 lbs. 6 oz. The upper half was adherent strongly to the diaphragm, and after removal the surface part of the organ was nodulated, puckered, and covered with a thick capsule, roughened by torn dense fibrous adhesions. The lower half of the organ was less nodulated, and its capsule was thinner. On section it was found that nearly the whole of the upper third was replaced by a large caseous mass extending from the hilum to the outer surface of the organ, and presented somewhat the appearance of a large infarct due to obliteration of some of the main splenic vessels.

A more minute examination showed that whatever share a vascular obliteration might have taken in the production of the lesions, something else must have been the essential causal agent. The margin of the cheesy mass was nodulated, and some of the nodules were almost entirely separated from the rest of the mass. In the midst of the cheesy area there were patches of splenic tissue which had retained to some extent their normal appearance. The capsule was distinctly raised over the diseased mass, which was surrounded by a dense very vascular capsule, continuous with the greatly

Digitized by Google

FIG. 10.

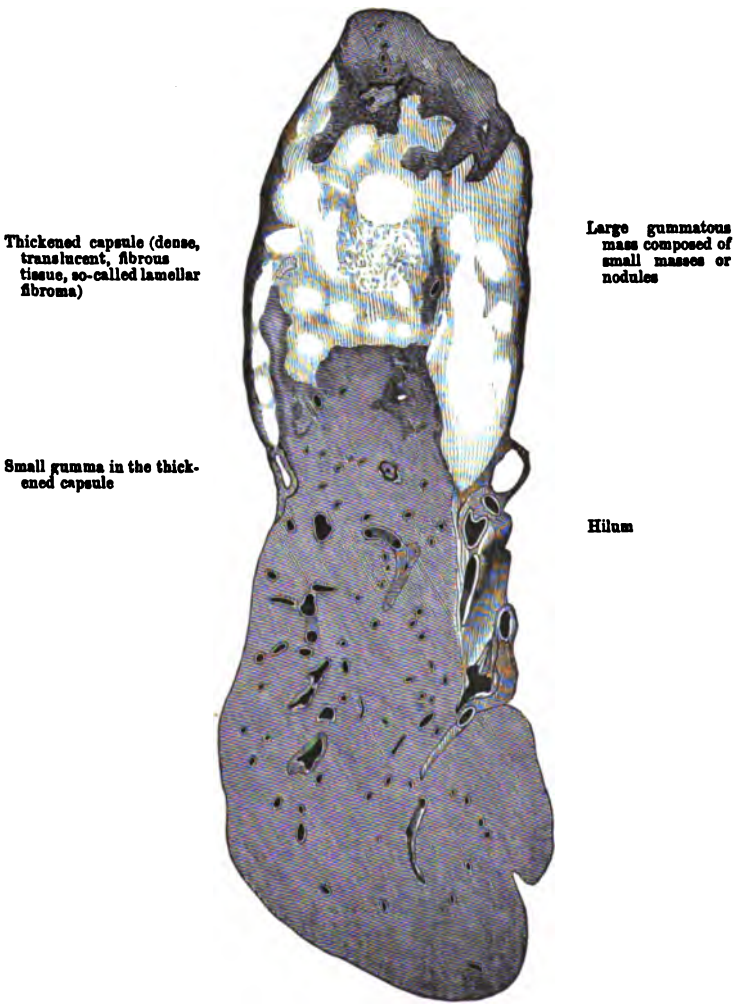

Median section of the spleen, showing a large gummatous mass in its upper part. Reduced to about two thirds natural size. From a sketch by Sheridan Delépine.

Digitized by Google

thickened and almost cartilaginous capsule of the organ. On looking into the mass itself it was evident that it was composed in great part of fibrous tissue, forming trabeculæ which separated nodules in a state of cheesy degeneration. Small gummata were found in the thickened capsule in the neighbourhood of the main mass of gummata. The whole substance of the spleen itself was indurated, so that a considerable amount of general interstitial changes was evident.

Microscopically the following lesions were found:—(1) General increase of fibrous tissue. This was most marked in the parts surrounding the large cheesy mass. (2) Distension of the vessels of the pulp. (3) Small accumulations of proliferated cells originating in the pulp-stroma, and also of small lymphoid cells similar to those found in the lungs and liver. (4) Thrombosis of many small vessels. The margin of the large tumour had the same characters as those of the tumour found in the liver. The central parts were, however, more cellular and more distinctly nodulated in the spleen than in the liver. The presence of these nodules and the imperfect subdivision of the mass by fibrous tissue bands differing in every respect from the ordinary trabeculæ of the spleen differentiate this lesion from an ordinary infarct; so that, although the determining cause of the cheesy degeneration of certain tracks of tissues may have been due to thrombosis or obliteration of vessels brought about by some secondary changes in the vessels, there is distinct evidence of a previous interstitial granulomatous inflammation similar to that found in the lung and liver. Some of the arteries showed distinct traces of endarteritis, but this was far from being a general lesion either in this organ or in any of the other organs examined. There was no lardaceous infiltration.

The diaphragm.—The lesions of the diaphragm can be readily summed up under the title of *gummatous interstitial myositis.* The interest connected with the study of the lesions found in this muscle lies chiefly in the fact that before the relations and the nature of the large gumma of the liver could be made out it was necessary to ascertain the exact position of the diaphragm. It was therefore carefully followed on the sides of the large gumma as far up as was possible; the result being that, at a short distance above the point where the diaphragm became adherent to the liver, its fibres were found separated by fibrous tissue, and so

Digitized by Google

FIG. 11.

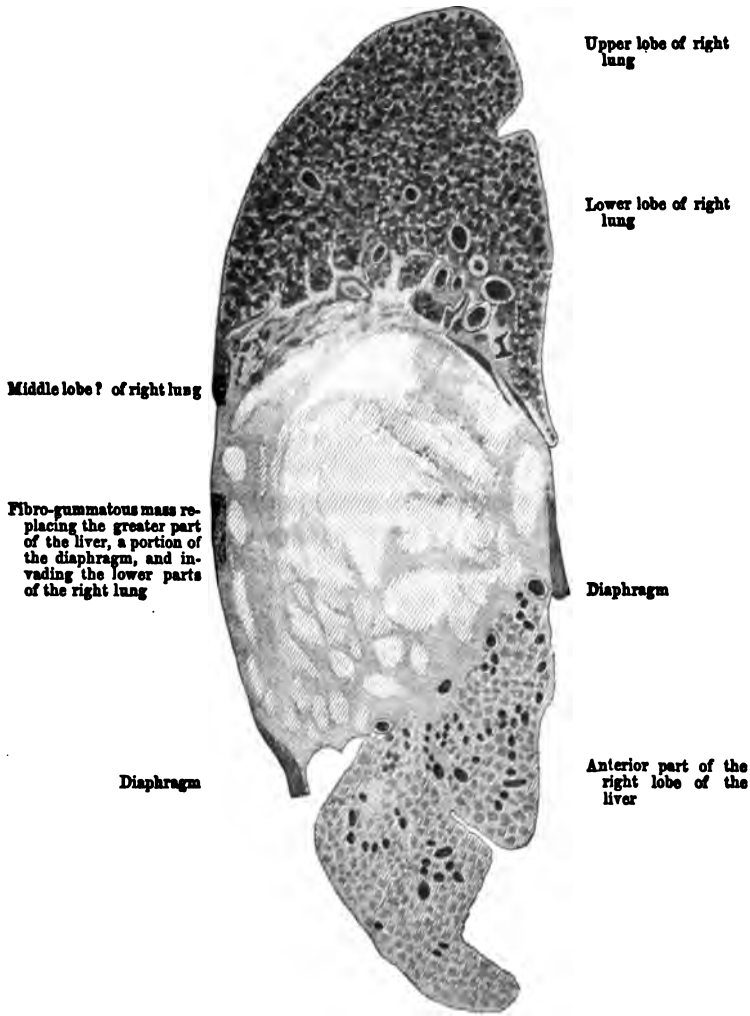

Gummatous infiltration of the liver, diaphragm, and right lung. An antero-posterior vertical section, reduced about half the natural size. From a drawing by Sheridan Delépine.

Digitized by Google

atrophied as to assume the appearance, first, of small bundles of unstriped muscular fibres; and secondly, of bundles of fibrous tissue. In the direction indicated by the course of these degenerated fibres gummata were found, and these were continuous with the mass which projected into the lung.

The liver.—The greater part of the upper surface and of the posterior border of the right lobe and part of the left lobe of the liver were firmly adherent to the diaphragm, which was itself strongly bound to the base of the right lung, so that it was impossible to remove either lung or liver by itself. What remained free of the organ was separated from the rest by a deep groove. Other and similar grooves were also found on the under surface, so that the liver had the appearance of being subdivided into small lobes. The capsule where it was not adherent was finely nodulated, and looked more dense and more opaque than normal. The gall-bladder was of moderate size and apparently healthy. On section the hepatic tissue looked pale, although it was very vascular. The fibrous tissue was distinctly increased in amount; the periphery of the lobules was pinkish grey in colour, and translucent at the margin; the centre was nearly opaque and of brownish-red colour. This description applies only to a small part of the organ.

In an antero-posterior vertical section passing in the region of the mammary line the following arrangement was seen. (For the sake of brevity, only what can be seen in that plan of section will be described, but many other sections have been examined with the same general results in every case.)

The upper two thirds of the liver were replaced by a rounded yellowish mass, measuring 14 cm. by 11 cm. (*i. e.* about 5½ inches by 4¼ inches).

This mass was composed almost entirely of cheesy matter and fibrous tissue. It had a dense, almost cartilaginous capsule, which was on the upper and posterior surfaces adherent to the diaphragm or to the lung, whilst inferiorly it formed a sharp boundary layer between the cheesy mass and what remained of the liver. It was in the region of the surface of the organ corresponding to that capsule that the deep groove mentioned in the general description was found. The capsule was continuous with trabeculæ of fibrous tissue which passed into the substance of the caseated mass. These trabeculæ enclosed rounded spaces occupied by gummatous nodules.

By coalescence of these nodules the spaces between the tra-

Digitized by Google

beculæ became large in the central parts of the mass. There was more fibrous tissue at the margin than in the centre of the tumour. The latter region was much softer than the peripheral part. In the portion of the capsule intervening between the large tumour and the less diseased part of the liver several small typical gummata were seen. In the midst of the fibrous tissue composing the trabeculæ several calcareous nodules were found; these were chiefly composed of carbonate of lime.

Microscopical examination.—That part of the organ which retained the naked-eye appearance of liver tissue was found microscopically to be more than half replaced by connective tissue. This tissue extended everywhere along the vessels, arteries, veins, and capillaries. In some places small aggregations of lymphoid cells were found. In many lobules there remained but slight traces of the liver epithelial columns. In others these columns had resumed the tubular appearance so typical of intra-lobular cirrhosis. It can be said that there were hardly any lobules where such changes were not visible, and that in most places they had reached such a degree as to render it probable that the parts so affected had become physiologically impotent. The large cheesy mass presented under the microscope all the appearances which the naked-eye characters suggested.

The *kidneys* weighed 18 ounces; the capsules were not adherent; the substances were congested.

The *bladder* was slightly congested.

4. *Cranial cavity.*

Brain.—There was an excess of fluid in the subarachnoid space and in the ventricles. The brain substance was rather soft. No other abnormality was noticed, but the organ was not examined very minutely.

5. *Skeleton.*

The tibiæ were thickened. The anterior border of the right presented an irregularly convex surface; the point of greatest prominence was about the centre of the shaft of the bone.

The compact part of the shaft was considerably thickened, and the medullary cavity was nearly obliterated by cancellous tissue. The cancelli immediately posterior to the compact bone of the anterior border were flattened and elongated. The posterior walls

Digitized by Google

were slightly thickened. The external and internal surfaces were irregularly nodulated.

III. *Discussion of the case.*

In this case it appears that the liver was affected with syphilitic deposits; the diaphragm was then involved, and the lower lobe of the right lung was compressed by the new growth which finally involved the pulmonary tissues. We have searched the 'Transactions of the Pathological Society' for a like case, but have failed to find one altogether similar. The earlier volumes of the 'Transactions' contain no reference to syphilitic visceral disease, and it may be of interest to remind members that cases of syphilitic disease of the liver, lungs, and spleen were first brought before the Society by Dr. Wilks. The first case of hepatic syphilis is recorded in vol. viii, p. 241 (1856–7); this was a case of cirrhosis; and the first cases of syphilis of the lungs and of the spleen were recorded in the years 1857–8 and 1860–1 (see 'Path. Trans.,' vol. ix, p. 55, and vol. xii, p. 216). The only case found in which it is mentioned that the diaphragm was affected is recorded in vol. xiii, p. 250.[1]

In this case the gumma apparently originated in the diaphragm; it therefore differs from the one we record.

A liver strongly resembling the one we have just described was brought before the Society on April 16th, 1889, when Mr. M. Targett showed a specimen he called "Diffuse Calcification of the Liver" ('Trans. Path. Soc.,' vol. xl, p. 123). The liver weighed 66 oz. The capsule was thickened, especially over the left border of the organ. Sections could only be made with a saw. The greater part of the liver substance was replaced by fibrous tissue, which was infiltrated with calcareous deposits. A report was made on the specimen by Dr. Sharkey and Mr. Eve. These gentlemen considered that the disease was of syphilitic origin, although there was no history of syphilis. In his report Dr. Sharkey refers to a case he had shown, and of which there is an account in the 'Transactions of the Pathological Society,' vol. xxxiv, p. 118.

[1] "About the middle of the posterior margin of the right lobe was a knotty tumour about the size of a large walnut, apparently growing from the capsule. . . . . Another similar deposit, the size of half a large orange, was embedded in the substance of the diaphragm, and projecting downwards established an inseparable connection between the left lobe of the liver and spleen."

Digitized by Google

In Dr. Sharkey's case there was no history of syphilis. The liver weighed 6 lbs. 7 oz.; the surface was nodulated; there was much fibrous material near the capsule, and nearer the centre of the organ there was a small-celled infiltration, and numerous gummata also were present. A committee consisting of Dr. S. Coupland and Dr. J. F. Payne confirmed the diagnosis of syphilis.

This case is not only of great interest owing to the unusual extent of the lesion, but also on account of its very clear syphilitic history. There is not only distinct evidence of the existence of a primary syphilis twenty-five years before the death of the patient, but the man subsequently suffered from all the more usual secondary and tertiary complications. The lymphatic glands, the throat, the skin, and the bones were all affected in the usual way, so that there can be no doubt that the case was one of syphilis. This is entirely confirmed by the nature of the lesions found *post mortem* in the liver. These lesions, although of remarkable size, had all the usual characters of syphilitic lesions.

There is often much doubt as to the syphilitic origin of lesions such as those we describe in the lungs. In this case, to doubt the nature of the pulmonary changes is practically impossible. We have not only a distinct syphilitic history, and lesions of an unusual nature, but in addition we find that there is a continuity between the typical hepatic lesions and those of the lung. One thing, however, is evident, namely, that although this is a case in which the inflammatory changes had a great tendency to the production of gummata, yet only those parts of the right lung which have come in contact with the liver through adhesions have become gummatous, and that only after having been first entirely replaced by fibrous tissue. From this it seems evident that in searching for evidences of syphilis in the lung one must be careful not to attach too much importance to the presence of gummata having characters similar to those found in solid organs, and that one should rather look for lesions such as those which in our case were present in the left lung—that is to say, lymphangitis, interstitial and catarrhal pneumonia, bronchial stenosis, and bronchitis, and the usual complications of those states. We are therefore able to confirm partly or entirely the observations of Ricord, Dittrich, Gubler, Wilks, Vidal, Virchow, Lancereaux, Coyne and Cornil, Maunoir, Malassez, Maunoury, Rindfleisch, Moxon, Payne, &c.

Digitized by Google

35. *Tumour in the portal fissure and liver leading to complete occlusion of the vena cava from the kidneys to the heart, with a similar tumour in the heart.*

By Samuel West, M.D.

Alice L—, aged 15, was admitted into St. Bartholomew's Hospital complaining of swelling and pain in the abdomen.

She had been a fairly healthy child, and had suffered from no definite illness except chorea, with which she had been attacked three times, the first at the age of twelve. At nine she had some affection of the eyes which made her blind, the mother said, but was cured in three weeks at Moorfields.

For the last two years she had been getting thinner, and nine months before admission she had had some swelling of the upper part of the thighs and vulva, the nature of which could not be ascertained after the lapse of time. About two months ago the abdomen began to swell, and the enlarged veins were noticed on its surface. Soon after, the patient suffered from attacks of pain in the stomach and chest, and occasionally in the right shoulder, with vomiting. These attacks came on usually within an hour of taking food. On one occasion there had been a little hæmatemesis. Recently the pain had been chiefly felt in the umbilical and hypogastric regions, and during the last fortnight all the symptoms had been worse.

The child was anæmic and wasted. There was one large gland beneath the right jaw, and the scar of an old abscess in the neck and in the groin. Otherwise there were no physical signs except in connection with the abdomen. This was greatly distended but resonant all over, and no signs of fluid were obtained. A lump could be felt in the left side, which moved freely with respiration, and was thought to be the spleen. The liver, though rising rather higher than normal into the thorax, did not appear to be enlarged downwards. The most striking feature in the case was the great distension of the superficial veins, both at the sides and in the middle line, especially over the upper part of the abdomen and the lower part of the thorax. The blood in them coursed upwards.

Digitized by Google

Although this seemed to point to obstruction of the portal vein no other evidence of it was forthcoming. Cirrhosis appeared to be negatived by the absence of history, and on the whole the diagnosis which seemed most probable was that of chronic tubercular peritonitis. Ten days later the abdominal distension was greater, but still no fluid was present. The liver-dulness reached the fifth rib, and the superficial veins were more dilated. What was thought to be the spleen was also larger. On February 14th, a fortnight after admission, the patient suffered great pain in the abdomen, chiefly due to intestinal colic; but the distension of the veins had still further increased, and ascites was now evident. The diagnosis was reconsidered, and settled in favour of a new growth so seated as to obstruct the portal vein.

On February 20th the upper edge of the liver had reached the nipple, the ascites was more marked, and a little œdema of the legs and feet had developed, and a mass could be distinctly felt beneath the right hypochondrium.

On the 25th the child became delirious, and so noisy that she had to be isolated. Two days later she became drowsy and stupid, but never comatose, and from this time rapidly sank till she died on March 3rd, no change occurring in her condition except that five days before her death jaundice made its appearance and rapidly increased, so that at the time of her death it was well marked.

The *post-mortem* report was as follows:—Body wasted and jaundiced, legs œdematous. The abdomen distended, and containing a good deal of bile-stained serum. The lungs congested and collapsed at the bases. The pericardium contained some blood-stained serum, and its surface was slightly roughened. There was some black vomit in the stomach. The intestines and kidneys were normal.

The liver was somewhat enlarged, and the left lobe formed a pear-shaped prominence in the epigastrium. On the anterior surface of the right lobe was a nodule, over which the capsule was puckered and the omentum adherent. On the under surface was a large mass extending from the diaphragm to the neck of the gall-bladder, and from the interlobular fissure two thirds across the right lobe. It measured 4½ inches in length by 2½ in breadth. It was firmly adherent round the root of the diaphragm, but was elsewhere free. The main trunk of the portal vein was below it,

Digitized by Google

and was not obstructed, nor was the branch to the left lobe; but that to the right, though not quite impervious, was greatly compressed. Tracing the vena cava up from below, it appeared to run directly into the mass at the back of the liver. It was pervious up to the point at which the renal veins entered, but immediately above this it became completely occluded, and could be traced no further; the growth appeared to have penetrated within and completely filled it. Just where it became continuous with the mass the coats of the vessel could be distinguished, but they were soon lost in the tumour, and from this point up to the heart no trace of the vena cava could be made out, nor of the hepatic veins either. In the heart, the place where the vena cava ought to have been was occupied by a mass which had implicated the walls and formed a prominent tumour in the interauricular septum about the size of a small Tangerine orange. The superior vena cava entered the auricle in the usual place, and was a little larger than normal, as was also the coronary vein.

On section the tumour, which was extremely hard and cut like gristle, was yellow in colour, like a chronic caseous lymphatic gland, and was divided into irregular masses by translucent fibrous bands. The appearance of the tumour in the vein and in the heart was the same, except that the latter looked a little more fleshy and was somewhat less firm.

Besides this, the main tumour, there was one other in the liver in the middle of the right lobe, nearly an inch in diameter, very firm and of the same structure, the fibrous bands being very distinct in it, and the liver surface over it a little depressed and puckered. The spleen was slightly above normal size, and contained a lump of similar structure in its upper part the size of a large walnut. These were the only two nodules found in the body besides the original tumour. The abdominal lymphatics were natural. To the naked eye the resemblance to gummata was very striking in all places, but against such a diagnosis seemed to be the size of the mass in the liver and the involvement of the vein and heart.

Microscopical sections were made from the tumour in the liver, in the vein, in the heart, and in the spleen. They presented in all cases the same appearances. The tumour was seen to be made up, as already stated, of several nodules separated by strands of connective tissue. Each of the nodules was for the most part of large size, measuring an inch or more in diameter, and were very irregular

Digitized by Google

in shape. A section through them revealed three zones: the central, caseous and structureless, which formed the chief part of the nodule; the outer, cellular; and the middle, fibrous and transitional.

The outer zone was formed of numerous cells closely aggregated together, with large nuclei, some round, others spindle-shaped, with but little matrix, and that translucent. In this region the growth presented all the appearances of a sarcoma. As the fibrous zone was approached the cells became scantier and the nuclei elongated, until they formed long spindles, arranged for the most part irregularly, but in places parallel with longitudinal strips into which the structureless matrix split up. In some parts well-formed fibrous tissue was produced, the nuclei becoming still longer and narrower, and lying between the bundles of fibres. In other parts fibrous tissue did not develop so perfectly, but the whole became caseous, the cells disappearing, and the substance of the tumour becoming structureless and yellow. The nuclei stained well in the cellular parts, as did also the matrix, but both ceased gradually to take the stain as the caseous portions were reached.

The structure of all parts of the tumour of the liver was the same. Outside the actual tumour strands of similar tissue undergoing like changes could be traced into the liver substance in the neighbourhood, the lobules being compressed as in cirrhosis and atrophy.

The masses in the spleen and heart all presented the same naked-eye and microscopical appearances.

The structure of the tumour would lead to the belief that it had been of very slow growth.

The diagnosis of the nature of the tumour lies between sarcoma and gumma. The small tumours in the right lobe of the liver and in the spleen looked exactly like gummata, and so did the large mass in the portal fissure; the difficulty lay in the apparent growth of the tumour into the vein and heart. If this were really growth into the vein I suppose it would settle the question in favour of sarcoma, but even then it would be remarkable that the tumours should have undergone so extensive caseous degeneration; for although caseous change may occur in sarcomatous tumours, still degeneration to the extent met with in the present case is, I believe, unknown. The difficulties are not less if the whole mass be regarded as gummatous, for I do not know any instance in which gummata have involved a large vein in the fashion found in this

Digitized by Google

case. There remains a third explanation, viz. that the masses in the liver and the heart are gummata, and that the apparent growth in the vein is not a growth at all, but an organised thrombus. The microscopical appearances of the mass in the vein are not opposed to this view, although even then it must be allowed that the clot has undergone similar degeneration to that of the gumma. On the whole it may be that this explanation offers the smallest number of pathological difficulties, although at the time of exhibiting the specimen I must confess that I was strongly inclined to regard the case as one of sarcoma rather than gumma.

Interesting as the tumour is in its nature and results, it is equally interesting from its clinical aspect, having regard to the fact that it had produced complete obstruction to the vena cava, and yet gave no clinical evidence of such a lesion, so that although portal obstruction was diagnosed, no suspicion of obstruction to the vena cava was entertained; and again, that in spite of the cardiac walls being so extensively involved, no cardiac symptoms occurred.

How the collateral circulation was carried on we have no evidence to show. Some of the superficial veins were enlarged, we know, but not to any great extent; and the vena azygos, which would have been, it might have been thought, one of the chief collateral branches, was not abnormally large, nor was the superior cava of unusual size. I suppose the absence of symptoms is to be accounted for by the slowness of growth, which we were led to infer from the microscopical structure of the tumour.

Report of the Morbid Growths Committee on Dr. West's specimens.—We agree with the description given by Dr. West of the naked-eye and microscopic appearances. We regard the masses in the liver, spleen, and heart as gummata.

The mass in the vein has the appearances of a thrombus, and we infer that the wall of the vessel was probably infiltrated by the syphiloma and subsequently thrombósed.

SEYMOUR J. SHARKEY.
FREDERIC S. EVE.
H. H. CLUTTON, *Chairman.*

Digitized by Google

36. *Lipoma of liver (? appendix epiploica).*

By H. D. Rolleston, M.B.

Embedded on the convex surface of the right lobe of the liver, taken from the body of a man killed by a severe fall, was a yellow, round, and fairly hard body as big as a nut. This body was half embedded in, half projecting above, the surface of the liver.

Further examination showed that it was not embedded on the substance of the liver, but that it lay in a hemispherical depression on the surface of the liver, this depression being lined by the peritoneal coat of the liver. The body was shelled out fairly easily, and a section was made into its substance. It was then seen to be an encapsuled mass of fat. Microscopically there was a thick capsule of fibrous tissue enclosing well-formed lobules of fat-cells. The fat-cells were normal, and there was no *débris* or other sign that the fat was the product of degeneration.

The most probable explanation of a small fatty tumour indented into the convex surface of the liver seems to be that one of the appendices epiploicæ has become detached, and that the loose body thus produced has subsequently wandered over the convex surface of the liver, and become fixed between the diaphragm above and liver below. The consistencies of the appendices epiploicæ and of the liver on the living body are both probably less than on the dead subject, where the fat has solidified and the circulation is absent. So that the liver might be impressed and indented by the constant pressure of a detached appendix epiploica.

The late Mr. Shaw ('Pathological Transactions,' vol. vi, p. 204) described a loose body which he removed from the sac of an inguinal hernia; this body he thought might be a detached appendix epiploica.

Dr. Wilks ('Lectures on Pathological Anatomy,' 1889, p. 394) mentions the fact that appendices epiploicæ may become detached and form loose bodies in the abdominal cavity.

The lipoma in question had a fibrous capsule, and had no vascular connection with the liver. The question arises as to the mechanism of its nutrition. When cut off from its normal vascular supply from the arteries ramifying on the colon it might have been

Digitized by Google

expected to atrophy; but this is far from being the case, as it is larger than an appendix epiploica usually is.

The peritoneal fluid may possibly have supplied it with sufficient nutriment, just as loose cartilages in the knee-joint are nourished by and grow in synovial fluid.

Dr. J. W. Ogle ('Path. Trans.,' vol. vi, p. 208) has recorded a loose body in the peritoneal cavity which had evidently been lodged in a depression on the upper surface of the right lobe of the liver. The depression, as in the present specimen, was lined by the peritoneal covering of the liver. Dr. Ogle discusses the origin of the loose body; after dismissing the theory of a detached appendix epiploica he says, "It seemed excusable to refer this body in origin to the presence of degenerated entozoa, such as the echinococci or cysticerci." *December 16th*, 1890.

---

37. *A case of primary melanotic sarcoma of the liver.*

By Sheridan Delépine, M.B.Edin.

Preliminary Remarks.—I am indebted to Dr. Burnet for the specimen on which the present paper is based. After showing it to me he exhibited the liver to the Pathological Society as a card specimen, and it may be well to quote here the remarks which were made on that occasion.[1]

"The specimen was removed from the body of a man, aged 63, who was admitted into the B— County Asylum on July 20th, 1881, and died there April 3rd, 1885. When admitted he was in feeble health and melancholic. During his stay in the asylum he was always in the Infirmary ward, and was given extra diet, tonics, &c. It was not until a fortnight before his death that attention was called to the peculiar shape of the abdomen. On being examined by Dr. Barron (to whom I am indebted for the notes and specimen), the right half of the abdominal cavity was found occupied by a solid tumour, rough to the touch and bulging out the lower ribs, but not showing much projection beyond the ordinary outline of the abdomen. He complained of no pain, but from this time he rapidly emaciated and sank. His weight on July 20th, 1881, was

[1] 'Transactions of the Pathological Society,' vol. xxxvi, p. 252, No. 48, Primary Melanotic Sarcoma of Liver" (card specimen).

Digitized by Google

9 st. 2½ lbs.; on October 16th, 1884, 9 st. 6 lbs.; on January 23rd, 1885, 9 st. 9 lbs.

"*Post-mortem.*—All organs except liver fairly healthy and free from any extraneous deposit. Liver enormously enlarged (weight 16 lbs. 11 oz.), but enlarged uniformly, so as to retain its normal shape. Surface covered with small flattened knots, like buttons. On section it looked very like a slice of brawn. Numerous small masses of deposit were scattered through whole liver, varying in colour from black to dirty white."

I. *Macroscopical appearances of the liver.*

The surface was nodulated, and presented an appearance not unlike that of a hobnail liver, with the difference that the nodules did not project much, had almost all of them a perfectly circular outline, and were separated not by narrow and deep furrows, but by more or less even areas, little or not depressed.

Some of the nodules could be seen through the capsule to have a whitish colour, contrasting in many places with the congested substance of the liver. In some regions dark brown, almost black nodules were very conspicuous. The organ felt firm, and even the nodules did not give to the touch an impression very different from that given by the ordinary substance of the liver.

The surface of section presented a large number of more or less regularly rounded pinkish-white nodules, varying in diameter from 1 mm. to 10 or 15 mm., but many of them formed by aggregation larger and more irregular masses. Several nodules, instead of being pale, were, on the contrary, of a very dark brown colour.

Some of the white nodules were partly pigmented, the pigmentation in these cases being often in the form of the peripheral network.

The intervening liver substance was evidently much altered, being in some places pale and fibrous, elsewhere granular and degenerated-looking, whilst in other places it was evidently congested and pigmented as in passive congestion. Many vessels of small size and quite patent (about 1 mm. in diameter), and evidently branches of the hepatic veins, penetrated into nodules, pigmented or not.

II. *Microscopical examination.*

The *capsule* of the organ is thickened in some places, chiefly in parts corresponding to some large interlobular veins. The serous

Digitized by Google

surface is generally smooth, but here and there a small patch of false membrane projects from the surface.

The *fibrous tissue* of Glisson's capsule can be followed along a number of interlobular veins; it is much increased in amount, and penetrates between the peripheral cells of the lobules. It is very cellular, and masses of embryonic-looking cells are found in its midst. These cells in some cases occupy the lumen of a small vessel; this is well seen in several parts of the deep layer of the capsule. This cirrhosis is far from being universal.

The *vessels* are remarkably altered; many of them, chiefly in the subserous coat of the organ, are distended with masses of rather large micrococci; these masses are either homogeneous or mixed with blood-corpuscles. Similar masses are found also in the deeper parts of the liver, but not so abundantly.

The *portal vessels* are much altered by increase of fibrous tissue around them, by the pressure of tumour nodules, causing obliteration of some and distension of others, and by proliferation of cells in their walls; but in the last respect they are little altered in comparison with the *intra-* and *sub-lobular* veins.

Some of the *intra-lobular veins* are apparently almost normal, but with these few exceptions these vessels are much altered. Generally their *endothelium* and that of the adjacent capillaries has proliferated to such an extent that in a great number of places the lumen is entirely occluded. The changes seem to take the following course.

At first there is a swelling of the endothelial cells, which very soon begin to proliferate. By this the lumen of the vessel is diminished, but blood can still flow on. The cells then go on proliferating, and many of them separating from the walls get mixed with the blood. (In places where the vessels are surrounded by an appreciable amount of fibrous tissue proliferation of the same kind is observed in the connective-tissue corpuscles outside the vessel.)

Finally, the cells accumulate within the lumen of the vessels to such an extent that they occlude them entirely; the proliferation continuing, the occluded vessels become considerably distended with cylindrical or more or less irregular masses of cells. These masses are at first entirely surrounded by hepatic cells more or less altered by pressure.

Some of the vessels which are almost occluded contain still a few small groups of red blood-corpuscles undergoing disintegration, and

Digitized by Google

golden-brown pigment granules are found either within the vessel or absorbed by the cells surrounding them.

In a number of capillaries spherical masses of a peculiar oily-looking greyish-brown or blackish substance are found; some of these masses are granular, many of them are apparently homogeneous. They are generally found in unoccluded vessels, and I have seen some of them at the opening of intra-lobular veins into sub-lobular veins. These are probably fluid pigment globules, passing into the blood to be finally excreted by the kidney; it is well known that in such cases the urine has been found to contain a very dark pigment, at any rate after standing some time or being treated by strong acids (melanuria).

The tissue proper of the organ, that is the *hepatic epithelium*, is, as may be surmised from the previous description, much altered. A few lobules seem to have escaped destruction and even distortion, but most of them are either replaced by the new tissue, to be described more fully later on, or are in a state of atrophy or necrosis, either owing to pressure or to stoppage of blood supply. In some parts also the intra-lobular vessels are considerably distended with blood, and the cells deeply pigmented, as in very advanced passive congestion. More than nine tenths of the epithelium of the organ seems to be destroyed by pressure.

This atrophy takes place in two ways: either the cells remain enclosed between the nodules of the tumours, and as the nodules increase in size the cells are at the same time compressed and separated one from the other; or else they are pushed at the periphery of groups of nodules, and being pressed one against the other they form a kind of laminated false capsule, in which the individual cells may become so flattened that they may be hardly recognisable.

Many of the liver-cells are pigmented. These infiltrated cells are found either in the neighbourhood of pigmented or non-pigmented nodules; in fact, this accumulation of blood-pigments seems to take place in the regions where the congestion is excessive and the epithelial cells atrophied—as, for instance, in those places where the vessels have just become occluded by accumulation of endothelial cells in their lumen.

The *bile-ducts* show much the same changes as those generally observed in cases of biliary cirrhosis, but this is not the case all over the organ. They are best seen where the interstitial tissue is

Digitized by Google

increased. Here and there they penetrate deeply into the substance of the lobule. Some of these ducts are dilated and more or less convoluted, evidently through accumulation of retained secretion.

As to the *neoplastic nodules* themselves, their mode of formation has been already described in relation to the vessels. The origin of small nodules is comparatively easy to trace, but the structure of the large ones is at first sight very perplexing. Some of them are pigmented, others are not; most of the pigmented ones are evidently composed of tolerably large spindle-cells, showing a very fine fasciculated arrangement. These masses have all the characters of large spindle-celled sarcomata.

But there are many nodules, and some of them among the largest where the structure is more difficult to understand. In such nodules the cells are tightly packed together, being altered by mutual pressure; they form small masses, filling up alveoli separated by network of apparently fibrous trabeculæ. The cells are of a moderate size with large nuclei, and it is difficult to see any intercellular substance between them. Here and there a small duct lined with cubical epithelium can be seen penetrating between these small masses.

Blood-vessels are very scarce in almost all the nodules, but, in a few, small groups of red blood-corpuscles can be seen between the cells. At the periphery of the tumours, where the liver-cells are not too much altered by pressure, the nature of these nodules becomes again clear.

In the trabeculæ separating the small nests of cells, atrophied hepatic cells can be easily discovered, whilst many of the small alveoli are directly continuous with some distended vessels; it is therefore evident that the large compound nodules have exactly the same origin as the small ones.

III. *Summing up of the description.*

We are therefore led by a careful examination to say that, notwithstanding their alveolated structure, all these tumours are sarcomatous. The walls of the alveoli are the more or less altered remains of the vascular walls and liver-cells, whilst the contents of the alveoli are chiefly composed of the products of the proliferation of the endothelium of these vessels. Some of the sarcomatous cells seem, however, to have sprung from the interstitial connective tissue of the organ, which in some places is seen to penetrate deeply

Digitized by Google

into the lobules, separating columns of hepatic cells. It is these liver-cells which, proliferating within a space gradually diminishing, become more numerous and smaller, and assume the characters of bile-ducts.

[The appearance of the tumour suggested to me that in some places the irritation of the epithelium might have led to the formation of adenomatous nodules, but all the masses which I examined carefully were undoubtedly of sarcomatous nature.]

The tumour is therefore essentially a sarcoma of vascular origin, distinctly alveolated; it is pigmented in various parts; it might, therefore, be called a *melanotic, alveolated, spindle-celled angio-sarcoma*; it might also be called an *endothelioma*.

IV. *Discussion of the case.*

Anatomical and physiological remarks.—A. We have, therefore, to deal with a primary sarcoma of the liver, originating in and growing along a certain set of vessels. Owing to this the sarcoma has acquired a peculiar alveolated structure; the vessels have become gradually obstructed, the obstruction leading to changes in the liver analogous to those produced by extensive *endophlebitis*.

B. The most remarkable anatomical feature of the case is undoubtedly the gradual *replacement of the contents of the vessels* by an embryonic tissue similar to that from which both blood and blood-vessels originated. The accumulation of these new products has led to the same changes as those resulting from accumulation of blood in the vessels, as can easily be seen by comparing the changes observed in this case and in cases of *cavernous angioma*.

C. Another anatomical feature worth noticing is the *rapid destruction of the liver-cells* surrounded by the sarcomatous cells, for in places where this destruction is going on it cannot be said that the products of the degeneration of the atrophied cells are removed by blood-vessels, since these are often entirely obstructed; it is therefore probable that the newly formed cells absorb the old cells they have surrounded.

D. The *excessive proliferation of endothelial cells* is of great interest, for it demonstrates on a large scale what takes place in various degrees, either in health or disease, within the vessels. I have often demonstrated that in clots formed within vessels of internal organs during life, or even in clots formed in the vessels

Digitized by Google

after death, endothelial cells can be found at a distance from the walls of the vessels, and that in order to occupy such a place it is necessary that they should have been separated from the walls whilst the blood was circulating. These cells, as their reactions show, were not dead when they separated from the walls, and a study of the formation of blood-vessels and of blood itself would lead one to expect that endothelial cells so separated might have some further use, and be transformed into some form of blood-corpuscles. These considerations, which I reserve for some further communication, are confirmed by some very interesting observations made by the late Dr. Handfield Jones on "Morbid changes taking place in the cerebral arterioles in inflammatory and other states."[1]

In this case the activity of the growth of the embryonic tissue within the vessels can be easily estimated, for we find that during the four years the patient was under observation his weight increased steadily by about 6½ lbs. Now that increase was taking place notwithstanding general emaciation, and was entirely due to the increase in weight of the liver, more than counterbalancing not only the loss of weight of its own atrophied substance, but that of all the other organs together. Admitting that only half of the liver tissue had been destroyed, we find that more than 15 lbs. of new tissue had been added to the organ.

Pathogenetic remarks.—E. Another very interesting feature of the case is the evident *relation of the tumour to the vessels.* This indicates evidently a source of irritation connected with the blood, and therefore we have here an instance of a tumour originating very much in the same way as specific inflammation. The problem which this case places before us is, however, more complicated than it seems at first. It would be difficult to support the view that the irritant was brought to the liver by the hepatic artery only, for even admitting that, owing to its slow circulation, the liver might have been at first singled out of all the other organs as the seat of disease, it would be almost impossible to conceive that it should have remained the only organ involved.

That great constitutional changes had taken place can be well shown by the fact that for four years before his death the patient was melancholic, so ill that he had to be kept all that time in the ward of an infirmary, and that he became at last very weak and

[1] 'Trans. Path. Soc. Lond.,' 1885, p. 158.

Digitized by Google

emaciated, notwithstanding good diet, tonics, &c. The slight gain in weight also, as I will point out, rather supports than invalidates this statement.

The fact that, notwithstanding the general distribution of the disease all over the organ, a great number of portal vessels have escaped, and that the morbid changes in most instances begin in the lobular capillaries or intra-lobular veins, is against the view that the irritant was brought to the organ through the portal vessels; whilst it would be almost preposterous to hold the view that mere passive congestion might be sufficient to lead to such changes as those above described. We are therefore driven to the conclusion that the irritant must have been elaborated by the liver itself.

The proofs of this are not wanting, but the most striking is found in the fact that the most altered of the three vessels is evidently the hepatic vein at its origin. Now the hepatic vein (as well as most other veins) must be considered to be not only a vessel carrying blood away from the organ, but also a channel collecting products which have been added to the blood during its circulation through the capillaries of the organ. It therefore seems probable that if any abnormal product happened to be manufactured by the hepatic cells, the first vessels to suffer would be the intra-lobular capillaries, and that the disease would have a tendency to extend more rapidly in the direction of the blood-flow than in any other direction. But as the blood-current is soon retarded or stopped, the extension backwards of the process would, of course, be possible also very early (this explains how a number of branches of the portal vein and hepatic artery have become affected).

Against this view one can set the fact that all the lobules of the organ are not affected; but, on the other hand, it can be said that the same difficulty would arise in a number of cases where inflammatory changes take place, whilst the remarkably even distribution of the disease all through the organ is very much more striking than the escape of a few parts. It must be remembered that although the organ had reached the enormous weight of 16 lbs. 11 oz. (*i. e.* nearly five times its normal weight), yet it had not lost its original shape.

F. It will be noticed that I have attached little importance to the *Staphylococcus* found so abundantly in the vessels. My reasons for doing so are the following:

1st. The micro-organisms are found in the most superficial parts

Digitized by Google

of the organ in very much greater numbers than in the deep parts, and their distribution does not correspond to the distribution of the disease, nor are they found in regions presenting any definite relations to the centres of invasion.

2nd. If they had been brought to the liver by the hepatic artery, and *had been the real cause* of the disease in the liver, other organs should have been affected too.

3rd. If they had been brought by the portal vein, and been the *actual irritant*, the branches of that vessel would have been more affected than the others, or at any rate as much.

4th. They are (the micrococci) found in vessels showing very little trace of proliferation in their elements, and although distending them in some places their appearance suggests the probability of their having grown there after the death of the patient, or perhaps after the partial death of the part, local death, which may have taken place a long time before the actual somatic death. In this last case the germs might have found their way into the blood, and owing to the debilitated state of the organism reached further than they would have done under less favorable circumstances, and finding a suitable "nidus" in the half-dead tissues of the liver, formed there a number of colonies. These of course would have to be considered in the light of complicating elements and nothing more.

5th. To all these arguments we may add the negative results obtained by C. A. Ballance and S. G. Shattock,[1] who in their numerous cultivation experiments have been unable to discover any form of micro-organism connected with any of the new growths which they have investigated.

G. The cause of the pigmentation of certain sarcomata is very obscure. *Melanotic sarcomata* do not always originate in parts previously pigmented, and when they begin in such parts the production of pigment is generally quite out of proportion with that of the part from which the sarcomatous cells have originated. It would therefore appear that in such cases the sarcomatous cells have the power to make melanin, or else to abstract that pigment from surrounding tissues or fluids. Many observers have tried to prove that all the pigments of the body were derived from hæmoglobin, but they have not succeeded in proving their point satisfactorily. On the other hand, there is strong evidence of the

[1] 'Trans. Path. Soc.,' 1887, p. 413.

Digitized by Google

formation of melanin independently of the presence of hæmoglobin. I have shown elsewhere that melanin is constantly manufactured in the epithelia exposed to light and other stimuli, and that some colourless or pale soluble compound allied to it must pass from the skin into the deeper parts of the body, and by elaboration in hæmopoietic organs be one of the elements in the production of hæmoglobin ('Proceedings Physiological Society,' December, 1890; 'Journal of Phys.,' vol. xii). I have also elsewhere shown that iron is normally stored in the liver, and leaves that organ in some soluble form by the hepatic veins; and I have surmised that the iron thus saved from the products of degeneration of decayed red blood-corpuscles was used again in the production of fresh hæmoglobin ('Practitioner,' August, 1890). It is easy to understand how a disturbance or want of equilibrium between these two functions would lead on the one hand to anæmia, and on the other to melanosis.

Clinical remarks.—From a clinical point of view the case is of interest in showing the almost absolute *balance* existing between the loss of weight by the body generally and the increase of a single organ.

The weight of the body generally increased only by 6½ lbs. during four years, and therefore can be said to have remained nearly stationary. The weight of the liver increased by at least 13 lbs. It is important to keep in mind that the increase of weight during the first three and a quarter years was only 3½ lbs., *i. e.* about 1 lb. per annum. During three months of his last year of life the increase was 3 lbs., *i. e.* at the rate of nearly 12 lbs. in the year. Such a rapid increase of weight at a time when the patient was getting worse is extremely remarkable. It is all the more significant that it is soon after this rapid increase had been noticed that the large size of the liver began to attract attention, and that was only a fortnight before death. So that whilst the body (the liver being excluded) was losing 6½ lbs., the liver was gaining the same number of pounds and 6½ more.

There is, however, one fact which is of interest in relation to that part of the question, and it is this: the liver, being on the road taken by a large portion of the food absorbed by the intestine, might have *diverted part of the food* which usually is only stored up in its substance, or simply passes through it. This is rendered probable by the general increase of weight, increase which is evidently due to the growth of the parasitic tissue. This points

Digitized by Google

to the fallacy of some of the results obtained by simply weighing a patient in order to judge of the state of his metabolism.

I may indicate as points of special interest the following conclusions.

V. *Conclusions.*

1. A considerable overgrowth of the endothelial cells of the hepatic vessels may give rise to the rapid[1] production of tumours having all the characters of sarcomata distributed all over the organ, but entirely confined to the liver.

2. The proliferation seems to be due to the elaboration of some substance by the hepatic cells in a state of disordered activity.

3. A large amount of melanin may accumulate in some of the nodules thus produced. This melanin does not seem to be produced out of any of the ordinary blood-pigments, and seems to be elaborated by the sarcomatous cells themselves.

I venture to suggest that some pale or colourless material was brought to the organ by the vessels, and that it was out of this material that melanin was precipitated in the cells.

4. Some of the hepatic veins contained globules of a brownish substance, not so dark as melanin, and evidently fluid; and these globules, I think, indicate the circulation of some such substance as the one just alluded to. This would explain how the urine of patients suffering from melanotic tumours and certain other disorders may become loaded with some product which, when exposed to the air, becomes very dark in colour (melanuria).

Note.—This paper was originally prepared for the Pathological Section at the Annual Meeting of the B. M. A. held in Glasgow (1888); I was, however, unable to attend, and the paper was not published.

Dr. Rolleston has attracted my attention to a paper by Dr. Hale White, published in the 'Guy's Hospital Reports' for 1890, p. 59. Those who wish to study the subject from a clinical point of view will do well to read the paper, which contains much information and a good digest of a number of cases. It may be interesting to notice that Dr. Hale White does not attempt to settle the pathological side of the question, owing to the discrepancies of opinion

[1] Primary melanotic sarcomata of the liver have been remarked by several observers to have run equally rapidly to a fatal issue.

Digitized by Google

among pathologists. With reference to this point I may mention that the case here recorded was first shown to me as a case of melanotic cancer, and lately another case of the same nature was also at first supposed to be cancerous; I had, however, no difficulty in proving that in both cases the disease was essentially a connective-tissue growth, and therefore a sarcoma.

---

38. *Pigmented growth of liver (apparently primary sarcoma). (Card specimen.)*

By F. G. Penrose, M.D.

The specimen is a small piece of an enormous liver (13¾ lbs. weight), which was removed from the body of a woman, aged 44, who died in St. George's Hospital on April 26th, 1888.

History.—She had been losing flesh for eighteen months before her death, and the liver was found to be much enlarged when she was first admitted into the hospital on January 2nd, 1888.

Specimen.—The piece of liver here shown is typical of the appearance of the whole organ. There are apparently no true liver-cells to be seen. The cells of the growth are of a sarcomatous rather than carcinomatous type.

The gall-bladder and bile-ducts were quite healthy. The only other traces of pigment were some fine spots on the endocardium covering both surfaces of the ventricular septum.

The brain and eyes were not allowed to be examined at the *post-mortem* examination, but there had been no evidence during life of any disease of these organs. *January 20th*, 1891.

---

39. *New growth in liver secondary to carcinoma of descending colon.*

By Norman Moore, M.D.

The liver and descending colon of a man aged 39, with microscopic sections.

The patient was a farrier who had had about twenty-five attacks

Digitized by Google

TABLE SHOWING DISTRIBUTION OF NEW GROWTHS PRIMARY IN THE COLON IN CASES EXAMINED BY DR. NORMAN MOORE.

Descending colon.

No.	Sex.	Age.	Primary organ.	Duration.	Microscopical appearances.	Growth in continuity.	Secondary growths. Lymphatics.	Heart.	Lungs.	Thyroid.	Liver.	Pancreas.	Spleen.	Kidney.	Suprarenal.	Uterus.	Ovary.	Brain.
1	M.	25	*Descending colon.*—Highest part; ragged growth on mucous surface all round. Rest of colon distended and thickened	—	*Carcinoma.*—Columnar cells; much hæmorrhage into it; many inflammatory cells	—	0	0	0	0	0	0	0	0	0	0	0	0
2	M.	40	*Descending colon.*—18 in. from anus; a pink and white mass. 3 in. of ulceration above this. Adherent to ileum	—	*Carcinoma.*—Columnar cells; some in alveoli; abundant stroma	Abdominal wall and sinus to extensor; ileum 4 ft. 6 in. from pylorus	0	0	0	0	0	0	0	0	0	0	0	0
3	F.	46	*Descending colon*	—	*Carcinoma.*—Spheroidal cells; abundant stroma, some columnar; many inflammatory cells	Stomach, a direct passage up	0	0	0	0	0	0	0	0	0	0	0	0

Transverse colon.

No.	Sex.	Age.	Primary organ.	Duration.	Microscopical appearances.	Growth in continuity.	Secondary growths. Lymphatics.	Heart.	Lungs.	Thyroid.	Liver.	Pancreas.	Spleen.	Kidney.	Suprarenal.	Uterus.	Ovary.	Brain.
4	M.	35	*Transverse colon.*—Near splenic flexure, whole circle; fungating mass inside; serous fluid on right side	—	*Carcinoma.*—Abundant stroma cells, spheroidal and flattened	Abdominal wall above it; ileum near mass; communication	0	0	0	0	0	0	0	0	0	0	0	0
5	F.	49	*Transverse colon.*—At splenic end new growth almost occluding passage; valve to transverse colon, stricture ulcerated, but no new growth	—	*Carcinoma.* — Stroma abundant, cylindrical cells chiefly	—	0	0	0	0	0	0	0	0	0	0	0	0

Digitized by Google

of gout, the first when he was thirty-one. He had a tophus in his right ear. Eight months before his death he was in good health, but fell downstairs and broke ribs on both sides, and was therefore obliged to take to his bed. In seven months he lost 4 st. in weight (14 st. to 10 st.). He suffered now and then from constipation, and after several attacks passed blood.

At the end of August his abdomen was observed to be swollen, and when I saw him in September there was a large solid tumour in the hepatic region, and the lower edge of the liver was to be felt from the umbilicus to the right anterior superior spine of the ilium. Its surface felt irregular. The spleen was not to be felt. Nothing abnormal was felt by the rectum. He had no piles. He was slightly jaundiced. He grew thinner and weaker, and on September 30th he passed a good deal of blood from the bowel, and he died on October 8th. In the last month of his life the hepatic tumour increased obviously in size.

His temperature was normal throughout.

His liver weighed 115 oz., and contained many masses of a dense white new growth. The descending colon six inches above the rectum was partially constricted by a dense growth of adenoid carcinoma The mucous surface was partly ulcerated, and there was much external puckering. There were only one or two infiltrated glands in the neighbourhood, and no other growths in the abdomen. A few very minute nodules of new growth were found in the right lung.

The rapidity of the hepatic growth—for its longest probable duration was two months—and the limited distribution of the growth were the chief points of interest, and illustrate the rule of distribution in such cases, which is further illustrated in the accompanying table of five similar cases. *October 21st*, 1890.

Digitized by Google

40. *Liver containing two hydatids, the sacs communicating but not the cysts; paracentesis three times,* 90 *oz.; free incision; death from exhaustion.*

By Samuel West, M.D.

Maria B—, aged 16, was admitted into St. Bartholomew's Hospital on April 28th, 1890, complaining of pain in the right side and swelling in the abdomen. She said that she had been in good health until two years ago, when she found her abdomen getting big, and had a good deal of pain in the right side. She was admitted into Lawrence Ward, and there was tapped with the removal of 27½ oz. of clear hydatid fluid. This was about seven months ago. She was three weeks in the hospital, and left well, but soon after the swelling and pain returned, until she was compelled to seek admission again.

She had always lived in London, and except for this had been in good health. The girl looked healthy, and there were no physical signs except those connected with the abdomen. The abdomen was prominent and distended, and occupied by a mass which descended almost to the pubes. The lower edge of this was felt about two inches above the pubes, and about half an inch above the right iliac spine. On the left side it did not reach quite so low. The organs were pushed up into the chest, so that on the right side dulness commenced at the third rib, and on the left side the cardiac dulness commenced at the upper border of the third rib. Between these two lines the whole mass was dull. The surface was smooth, but the epigastrium was prominent, and in this region a doughy, semi-fluctuating sensation was experienced.

On May 1st paracentesis was performed in the seventh space in the mid-axilla, where the tension seemed highest to the touch. A cyst was reached at once, and 90 oz. of clear fluid removed without more pressure than was just sufficient to make it flow, and this was but little. Just at the end of the operation something seemed to give way, and the fluid changed its character; having at first been quite clear, it then became orange-coloured. Examination showed that the two fluids differed only in colour, and that the

Digitized by Google

colour was not due to bile-pigment, *i. e.* the ordinary bile reactions could not be obtained. The specific gravity was 1004. The fluid contained abundant chlorides and a slight trace of albumen.

As the fluid was removed the epigastrium lost its prominence, and at last became depressed. The dulness above descended to the fifth rib in the right nipple line. The swelling in the right lumbar region altered somewhat. It seemed to rise and contract, but did not change as much as was anticipated, so that it was thought to be due not to the cyst itself, but probably to some coils of intestine matted together. No evil results followed the operation; the temperature remained normal, and the patient was greatly relieved.

A few days later it was evident that the cyst was filling again, and on May 15th paracentesis was again necessary, for the swelling had reached its former dimensions. The puncture was this time made in the middle of the epigastric prominence, and 84 oz. were removed. The fluid was green, slightly turbid, contained a little pus, and gave the bile reaction faintly.

On June 13th paracentesis for the third time was performed, the puncture being again made in the right axilla; 90 oz. were removed, the fluid having the same characters as on the last operation.

A few days later the cyst was almost as full as ever, and it was decided to have it laid freely open. This decision was arrived at with some hesitation because the cyst was of such great size, and because I thought it evident from the results of paracentesis that it had developed upwards, and lay perhaps outside the liver in part, and between it and the diaphragm. If this were so, the drainage would be very difficult, and it would not be easy to get contraction to take place.

On June 28th Mr. Cripps operated. The patient being put under the influence of chloroform, a vertical incision was made over the tumour near the semilunar line on the right side about 3 inches in length. The liver was reached, and found not to be adherent to the parietes. Sutures were then passed so as to fix the exposed part of the liver to the abdominal walls, and after the cyst had been partially emptied by the aspirator an incision was made into the cyst, which appeared to be covered by about an inch of liver tissue. The edges of the incision were then firmly stitched to the skin incision, and the cavity washed out, first with carbolic acid solution and then with pure water. The fluid evacuated was

Digitized by Google

deeply stained with bile. A glass drainage-tube was inserted and Keith's dressings applied. A great deal of difficulty was experienced during the operation by the accumulation of mucus in the throat, which caused considerable dyspnœa, and gave some anxiety for a time.

The patient slept well with a little opium, and seemed to have borne the operation well. The subsequent history of the case is short. The discharge of fluid was considerable, so that the wound had to be dressed four times a day for the first three days, and after that three times, but by the third two dressings a day were sufficient. Drainage was evidently difficult. The temperature never rose above normal, but the child gradually grew weaker and weaker, lost her appetite completely, and occasionally vomited. She died at last of exhaustion on the 10th of July, a fortnight after the operation.

On *post-mortem* examination the diaphragm was found pushed up into the thorax so as to reach the second rib on the right side, the heart being displaced upwards also to the same level. All the organs were healthy except the liver. This was strangely deformed owing to the presence in it of two large cysts, one beneath the diaphragm and the other in the centre of the liver. The left lobe was quite small, and looked like an appendage to the liver. The right lobe extended from the diaphragm above to the crest of the ilium on the right side. The mass which was felt in the lower part of the abdomen during life turned out to be the greatly displaced right lobe of the liver; above the level of the umbilicus it was crossed by dense cicatricial tissue, which corresponded with a collapsed cyst with which the operation wound freely communicated. This formed a flattened cavity extending transversely across the lobe, and containing much decomposing hydatid membrane. The upper cyst was of considerable size, and contained an unruptured cyst measuring six or eight inches across. On removing the hydatid membrane the two sacs were found to communicate by a perforation below, through which a finger could be easily passed.

The pathological appearances explained the conditions observed during life. There were two cysts, as had been inferred from the feeling of something giving way during the first paracentesis, and the immediate change in the character of the fluid. Both cysts were clearly emptied by the paracentesis, and the conclusion seemed a fair one to draw that an incision into the lower one would empty

Digitized by Google

both. It is very strange that this did not happen, for although the upper cyst was twice punctured, and on the first occasion, at any rate, had the contents of the second cyst drawn off through it, still it was not killed, but continued to live, and the communication with the lower one closed, so that at the time of operation the upper could not be emptied from the lower cyst.

A counter incision in the upper part was discussed, and would no doubt have been made had the patient's condition admitted of it. Whether this would have saved the girl's life is more than doubtful, even under the most favorable circumstances, for, as the *post-mortem* showed, the pleural cavity would have been opened by any operation above the costal arch. It is difficult to say whether the upper cyst was free of the liver or not, as the cyst-wall seemed to be continuous with the fibrous capsule of the liver. It seems to me possible that the first cyst to develop was the lower one, and that the upper one had grown, as it were, by budding from the lower, and subsequently become independent. This appears probable from the communication that existed between the cyst-sacs, though the cysts themselves were not in connection.

The amount of fluid is noticeable considering the small size of the patient, for she could not have weighed more than six stone, and more than one third of the space in her trunk was occupied by the cyst and the remains of the liver. *March 17th*, 1891.

---

41. *Gall-bladder with internal ulceration.*

By Norman Moore, M.D.

The gall-bladder was distended with bile containing much fine biliary gravel, but no distinct calculi. It was much elongated and thickened, but microscopic sections showed that no new growth was present. On washing away the gravel the inner surface was found to be universally injected, and all over it were numerous minute ulcers, most abundant at the fundus. These were shallow, and contained pus and mucus. The papilla of the bile-duct was unusually large and prominent, but there was no obstruction of the common duct. At the fundus of the gall-bladder one of the ulcers

Digitized by Google

had perforated, causing general peritonitis. The patient was a man, aged 67, who was suddenly attacked, while in bed for an attack of bronchitis with symptoms of general peritonitis. These had been preceded by prolonged constipation, and in hopes of finding some obstruction his abdomen was opened by Mr. Walsham, at my request, by an incision above the umbilicus. A large quantity of pus escaped from under the right lobe of the liver, where it was partially enclosed by recent lymph, there being, however, no old abscess cavity. General peritonitis was obviously present. The pus was bile-stained, and a large quantity was washed out. The patient had no gout or other morbid conditions except some emphysema of the lungs.

In the museum of St. Bartholomew's there is a specimen prepared by the late Dr. J. R. Farre in which a gall-stone has ulcerated through the wall of the gall-bladder into the peritoneum. But such cases are much rarer than those of ulceration through the common duct. Only two other examples of perforation of the gall-bladder itself (without the presence of new growth) have occurred to Dr. Norman Moore. In both the gall-bladder had become adherent to the abdominal wall, abscess followed and was opened, gall-stones were discharged, and recovery took place. The specimen is of a still more uncommon variety, for it shows perforation without the presence of any mass which could be called a calculus. *December* 16*th*, 1890.

---

42. *Ulceration of gall-bladder.*

By Sydney Jones, M.B.

This specimen was taken from a lady under the care of Dr. Wyman, of Putney. She was fifty-three, had a phthisical history, had always been delicate, and suffered at different times from what she called spasms. About twelve months previous to her fatal illness she had an attack; then she was slightly jaundiced; since, she had been in as good health as usual.

Dr. Wyman was sent for on February 16th, and found her suffering from severe abdominal pain and vomiting with symptoms

Digitized by Google

of obstruction. She was seen by Dr. Bristowe on February 18th; had then acute general peritonitis, the abdomen very tender and much distended. Pain was referred to the right hypochondriac region principally, but also to the left iliac fossa.

Dr. Bristowe saw her again on March 2nd (twelve days after the commencement of the attack). The abdomen was still much distended, not quite so tender; there was obscure fluctuation on the right side of the abdomen (? hydronephrosis or hydatid). I saw her on March 6th. Fluctuation was very distinct on the right half of the abdomen; there was resonance over to the inner side of the cæcum.

An incision was made transversely above the crest of the ilium, and about three pints of yellowish fluid evacuated, with flakes of bile-coloured lymph.

The cavity extended to about middle line, as high as the cartilages of the ribs and down nearly to Poupart's ligament. It was well syringed out with weak carbolic lotion, two large drainage-tubes were inserted, and antiseptic dressings used.

At the time of this incision there was in connection with the left parotid much redness and diffused infiltration; this was incised, with the escape of sero-purulent fluid.

There was a friction rub over the lower part of the left lung. A day or two afterwards there was inflammation in connection with the right parotid gland, which in a few days subsided. On the 21st and 22nd of March I saw her with Dr. Wyman with a view of making a higher opening as a counter opening, and in order to explore the liver and gall-bladder; but she was very weak, and had indications of chest mischief. There was no proof of a cavity in lung, but her nummular sputum suggested this. She died on the 18th or 19th, thirty or thirty-one days after the commencement of her ailment.

Only a limited *post-mortem* could be obtained. This was made by Drs. Wyman and White.

The gall-bladder was full of stones, fifty-three in number, varying in size from a mustard seed to twice the size of a large pea; at the bottom of the gall-bladder was a small ulcerated opening, now made much larger than it was originally by the evacuation through it, at the *post-mortem*, of the gall-stones. No gall-stone had escaped into the peritoneal cavity. There was no cyst. The effused fluid had been limited to the right side of the abdomen by

Digitized by Google

coagulated lymph. No examination further than that of the abdomen was made. The fluid removed by operation on March 6th was examined by Dr. Bernays, and the following was his report of analysis:

Greenish-brown glairy fluid, sp. gr. 1024. Slightly alkaline; with Pettenkofer's test, strong purple-red, with nitric acid, a coagulum with play of colours, green, &c.

Albumin	4·690
Fat	0·050
Urea	0·028
Alcoholic extract	0·642
Aqueous extract	0·560
Sodium chloride	0·170
Phosphates, &c.	0·220
Water	93·640
	100·000
Ash	0·39

The gall-bladder and gall-stones are now shown. The aperture in the gall-bladder is much bigger than it was when the abdomen was first examined. The walls seem thickened; but the lining membrane seems free from ulceration. *April* 21*st*, 1891.

---

43. *Distension and commencing suppuration of the gall-bladder in association with typhoid fever.* (*Card specimen.*)

By W. Hale White, M.D.

The patient, a youth aged about 17, was admitted for a severe attack of typhoid fever. He was thin and poorly nourished. The fever ran the usual course, but was severe; the patient was frequently comatose or delirious. He appeared to be doing well for a time, but he began to refuse his food, and gradually sank.

Characteristic typhoid ulcers were found in the lower part of the ileum; some had healed, none had perforated, and there was not any peritonitis around them; but there was recent peritonitis around the gall-bladder, matting that organ and the lower edge of the liver to the intestines. The lymph effused was very soft,

Digitized by Google

almost purulent. The gall-bladder was distended, so that it measured 6½ inches in length, and 3 across. Its walls were very thin, and in some places almost perforated. The bile which distended the gall-bladder appeared normal, and there was no obstruction to its flow. It appeared that the distension was paralytic. The matted intestines and liver so hid the gall-bladder that it was probably impossible to have felt it during life. The patient complained of no pain. *December* 16*th*, 1890.

---

44. *Large gall-stone in ductus communis choledochus.* (*Card specimen.*)

By W. Joseph Tyson, M.D.

Marian D—, aged 50, single. For the last eight years has suffered great pain, the attacks coming on about three times a year, each attack lasting twelve to twenty hours; small gall-stones found after many of them.

In June of this year the patient was admitted into University College Hospital, the symptoms being jaundice of skin and conjunctiva distended abdomen, and localised pain in the right hypochondrium. A few days later a tumour appeared, with signs of fluctuation. This was operated upon by Mr. Marcus Beck. The abscess found contained a mixture of pus and bile; it was entirely cut off from the peritoneal cavity. The wound healed in seven weeks, and the patient left the hospital on July 18th.

Re-admitted into University College Hospital on August 5th, on account of a return of the old attacks of the pain.

Left hospital on August 20th, jaundice and pain having gone.

Admitted into Folkestone Hospital on August 29th, with deep jaundice, great swelling of the abdomen, general symptoms of collapse, and a temperature of 103°.

Anticipating purulent peritonitis, abdominal section was performed, and the peritoneal cavity washed out with warm water.

Post-mortem.—Liver thoroughly jaundiced and very soft in consistence. There were in it three or four abscesses varying in size from a pea to a hazel nut. Gall-bladder small, containing five gall-

Digitized by Google

stones; the hepatic ducts immensely dilated. In the common duct is a large gall-stone just at the opening of the duct into the duodenum. *December 16th*, 1890.

---

45. *Duodenal pouching at the opening of the bile-duct, due to ulceration.* (*Card specimen.*)

By H. D. Rolleston, M.B.

In the second part of the duodenum there was a pouch as large as a walnut, which projected into the substance of the pancreas. The floor of the pouch was smooth, and rather below its centre was the opening of the biliary and pancreatic ducts. The wall of the pouch was thin, and when examined microscopically showed irregular cicatricial tissue, the normal constituents of the wall of the duodenum being absent.

The pancreatic duct was followed into the pancreas; it admitted a bristle, was not dilated, and contained no calculi.

The bile-duct was thickened and greatly dilated; it contained no calculi; the cystic duct appeared to be obliterated, but did not contain any gall-stone. The gall-bladder was thickened as regards its wall, collapsed and empty.

From a woman, aged 74, who died of senile gangrene. There was a Meckel's diverticulum thirty-four inches from the cæcum. It is not known whether she had ever suffered from symptoms of biliary colic. *October 21st*, 1890.

---

46. *Rupture of spleen.*

By Edgar Willett, M.B.

The spleen of a woman, aged 39, who was admitted into St. Bartholomew's Hospital, under the care of Mr. Morrant Baker in November last, and who died on the third day from injuries

Digitized by Google

received by being knocked down and probably run over by an omnibus. At the *post-mortem* examination there was a considerable amount of dark blood in the peritoneal cavity, and the spleen was found to be ruptured; there was also a contusion and a slight tear of the right lobe of the liver, but most of the blood doubtless came from the spleen. The rupture is over two inches in length, and is situated on the outer surface and near the upper margin. The main interest in the specimen lies in the excellent attempt at repair, for the wound is seen to be closed by a firmly adherent clot. Unfortunately the patient received other severe injuries besides those already mentioned, viz. fracture of the third to the eighth ribs on the right side, with laceration of the apex of the right lung, air and blood being found in the right pleural cavity. It is interesting to state that neither before nor after death was there any bruising or discoloration of the skin of the trunk. *January 7th*, 1891.

---

47. *Cirrhosis of pancreas in diabetes* (*microscopical*). (*Card specimen.*)

By W. B. Hadden, M.D.

The fibrous overgrowth occurs in patches, which in some parts is around the ducts, in other parts replaces the gland tissue. Some of the acini in the neighbourhood of the connective-tissue change show epithelial proliferation.

At the *post-mortem* examination the pancreas was found of normal size, but very firm. There were cavities in both lungs. The patient was a woman, aged 65, affected with diabetes; for two years she had been much wasted. During the time she was in the hospital the urine was scanty (ranging from 14 to 26 oz.) and contained much sugar.

In vol. xxxviii of the 'Transactions,' p. 163, I described a case of cirrhosis of the pancreas in diabetes; but the change was more diffuse than in the present case. The patient, too, was much younger (aged 38). *March 3rd*, 1891.

Digitized by Google

V. DISEASES, ETC., OF THE GENITO-URINARY ORGANS.

1. *Hydronephrosis of right kidney, removed by nephrectomy; aberrant renal artery.* (*Card specimen.*)

By Alban Doran.

On April 18th, 1891, I removed this kidney from a woman aged 43. For three years she had noticed a swelling in the right loin, which grew very much larger after December, 1890, filling the right side of the abdomen. The secretion of urine was normal. I opened the abdomen by an incision along the outer border of the right rectus muscle. The left kidney felt healthy. The peritoneum to the outer side of the ascending mesocolon was divided. Three pints of a clear, pale yellow fluid, of a urinous odour (sp. gr. 1008, no albumen), were removed from the tumour by aspiration. The cyst was then enucleated; all the vessels were secured separately. The ureter was much displaced, springing from the upper and anterior part of the cyst, and running inwards over the cyst, and then downwards and backwards behind the vessels. It was tied and returned, with the capsule of the kidney, into the abdominal cavity. No drainage was necessary. The patient recovered. The kidney is tough, its surface puckered, its capsule adherent. It contains no calculi. There are two renal arteries. The ureter starts abruptly from the cyst, near the lower artery. When the cyst was full, the ureter lay much higher. When the cyst is filled with water, the ureter does not allow any escape of fluid till held so as to run upwards from the cyst. The ureter possibly became obstructed by adhesion to the aberrant artery. (Compare "Hydronephrosis apparently due to a malplaced vessel," 'Pathol. Collection, Mus. Guy's Hospital,' No. 2071[51].) *May 5th*, 1891.

Digitized by Google

2. *Perinephritic abscess opening into the duodenum.* (*Card specimen.*)

By H. D. Rolleston, M.B.

The specimen shows the right kidney, which is in an advanced state of tubercular disease, and the second and third parts of the duodenum. At the lower part of the second portion of the duodenum, and at the commencement of the third portion, there are ulcerated openings into an abscess cavity, bounded on the outer side by the ascending colon, on the inner side by the duodenum, and behind by the right kidney. The openings are formed at the expense of the outer wall of the duodenum; they are entirely behind the peritoneum. The abscess cavity contained a dirty-brown fluid. This cavity also communicates with the pelvis of the kidney.

The tubercular kidney had a second perinephritic abscess eroding the under surface of the right lobe of the liver. This abscess did not communicate with the pelvis of the kidney.

From a patient, aged 18, who died under Mr. Turner's care in St. George's Hospital. He had had severe hæmaturia. He died with advanced tubercular disease of the lungs.

October 21*st*, 1890.

---

3. *Tumour of right kidney, weighing* 4½ *lbs.; hæmaturia; death.*

By John R. Lunn.

William S—, aged 57, a labourer, was admitted into St. Marylebone Infirmary, September 18th, 1890. He stated that he had enteric fever thirty-six years ago. Had never had syphilis, gout, or a blow in the region of his kidneys, and had always enjoyed good health until six years ago, when he had an attack of hæmaturia, the blood passing in clots, which at first was followed by clear urine. This lasted a few days and then ceased for four

Digitized by Google

or five months, when a recurrence took place. Whilst passing the clots he suffered from sharp shooting pains in his right side, down to his penis. No calculus was ever passed. Some months before admission his hæmaturia got more frequent, and his feet began to swell three weeks before admission. He had an attack of retention, and was obliged to have his urine drawn off at a hospital. On admission the patient was a strong and well-built man, though pallid from the loss of blood. He had incontinence following retention. The urine was drawn off with a No. 10 silver catheter; it was acid and contained blood, as shown by microscopical examination. His tongue was moist and furred. Bowels open. Pulse quick and small; arteries very rigid. Temp. 101·4° F. On examination of the abdomen a large tumour was found occupying the right renal region. It appeared fixed, and on deep pressure doubtful fluctuation was to be felt. An exploring needle was inserted into the swelling, but nothing was withdrawn. Two days after admission the patient passed some very large clots of blood by the urethra, which did not cause him much pain. The urine was obliged to be drawn off twice a day. Four days after admission the patient became very collapsed from loss of blood; he had several rigors, temp. 103·4°, after which he gradually sank, and died on the sixth day following admission.

At the *post-mortem* it was noted, after opening the abdomen, that the liver appeared enlarged and pushed forwards by some tumour behind, which was slightly adherent. The liver was easily removed, and a large tumour was seen involving the right kidney, which was removed. Mr. Targett has kindly examined the tumour, and gives the following account:

The tumour has replaced the right kidney, and in shape resembles it. The mass weighs 4½ lbs., and measures 7½ inches in length, 5 inches from side to side, and 3½ inches in thickness. It had a definite fibrous capsule, like that of a normal kidney. On longitudinal section it was found that the whole of the kidney structure had not disappeared, for at the upper extremity a small triangular area of normal renal tissue could be recognised. For the rest the surface of the section was spongy and very soft, yielding an abundance of juice on scraping. The pelvis of the kidney had for the most part disappeared, except at the upper end in the neighbourhood of the normal kidney structure, where one or two calyces remained and were much dilated. Their outlet, how-

Digitized by Google

ever, was blocked below. Examination of the hilum showed that the renal vein was completely filled with a plug of new growth, which had extended inwards to its opening into the vena cava. The funnel-shaped portion of the pelvis was similarly blocked with growth and blood-clot. The growth does not appear to have perforated the capsule anywhere except at the hilum, and there were the bossy projections which seemed to have commenced as intravenous extensions. The opposite kidney (left) weighed 8 oz., and contained one secondary deposit about the size of a walnut. Neither kidney showed amyloid changes. The urinary bladder was rather thickened, but otherwise normal. The prostate enlarged. The liver weighed 4½ lbs., soft and friable, no secondary growths. The other viscera normal. Heart was much dilated and left ventricle thickened; weighed 26 oz. 4 drachms. Valves healthy.

Remarks.—The interest of the case seems to be in its long duration and the absence of pain to the patient during life, except that due to the passing of the blood-clots.

Dr. Bristowe says, "When carcinoma of the kidney is secondary it rarely attains large dimensions, but when primary (and this form is generally limited to one kidney) it may attain an enormous size, and is generally of encephaloid variety," as it appears to be in my case. The reason why no operative interference was suggested was on account of the man's general condition and age.

February 17th, 1891.

Report on Mr. Lunn's specimen of tumour of the kidney.—We have examined the microscopic section of the growth submitted to us, and agree with Mr. Targett's statement, as reported by the author of the paper, viz. that the tumour is a carcinoma. Its structure corresponds closely with a specimen of primary carcinoma of the kidney described and figured by Dr. Sharkey in the thirty-fifth volume of the Society's 'Transactions,' p. 235.

R. W. Parker.
Samuel G. Shattock.
H. H. Clutton, *Chairman.*

Digitized by Google

4. *A case of tubercular ulceration of the bladder, which was treated by means of a weak solution of tuberculin.*

By E. Hurry Fenwick.

I wish to lay this case before the members of this Society because it presents certain unusual features, and also because Koch's injection was used as a diagnostic agent with untoward results.

C. M—, aged 32, was sent to me by Dr. Rayner Batten, of Gloucester, with a diagnosis of probable tuberculosis of the urinary tract. The patient had, in the first instance, been placed under Dr. Batten's care with the diagnosis of stone in the left kidney. The history did not support this diagnosis, and another, that of urinary tuberculosis, was made; but, as he was found on examination to present certain symptoms which could not be accounted for on the supposition that the trouble was purely tubercular, I was asked to investigate the bladder with the cystoscope, and carry out any line of treatment which should be adopted. My notes were as follows:

"The patient is a florid-looking healthy man, who says that he has been ill for two years. He is deaf, and has a discharge from the left ear, the sequela of scarlet fever in childhood. There is no history of consumption in the family. He ascribes the cause of his trouble to being forced to retain his urine for some time after he was 'full.' When he was at last able to relieve himself he found that he had to strain greatly to evacuate the bladder. Almost immediately a frequency of micturition set in, the calls being every two hours in the day and twice at night. The urine became thick and muddy. The difficulty in micturition continued, but it was not until a year after the onset that pain commenced, and this only occasionally, though finally it became constant. Blood appeared fourteen months after the onset (*i. e.* ten months ago); it was bright red and profuse, and lasted three days; it was induced by coition.

"*Symptoms.*—The pain was at first of a sharp, scalding character during and throughout the act of micturition, being easier after the completion of the same. It was referred to the entire urethra from the bladder to the glans. Latterly he has had a dull, heavy, aching pain in the left side, being somewhat relieved by the hæmaturia.

Digitized by Google

He has had two sharp attacks of bleeding. Latterly there has been less difficulty in micturition.

"*Status presens.*—December 6th, 1890, the patient passes water every half-hour in the day and every three quarters of an hour at night. He suffers pain during micturition. It starts from the left kidney, passes along the ureter to the bladder, and thence along the urethra to the glans penis. He passes 2 oz. of urine at a time, and 2 oz. of thick puriform secretion remain in the bladder as residual urine; 88 oz. of urine are made in the twenty-four hours. The secretion is murky, light-coloured, sp. gr. 1010, acid; it contains one quarter pus, and one eighth albumen is present. *Bacillus tuberculosis* is easily found; many septic bacteria. The temperature is 101°. The testes and prostatic lobes are healthy. The left kidney is tender on deep pressure, but no enlargement can be made out."

As the urine contained one fourth pus of a pyelitic character, and as his temperature pointed to suppurative disease in the upper parts of the urinary tract, and as, moreover, the tubercle bacillus could be found so easily and in such large numbers, I judged the patient to be passing through* a very acute attack of tuberculosis, and ordered that no instrument should be passed for fear of aggravating the existing symptoms. After a few days' rest in bed the fever subsided and the patient felt better.

On December 15th, as tuberculin was being freely used in the wards, I determined to inject a minute dose, partly for confirmatory diagnosis and partly to accelerate, if possible, the shelling out of the tubercular deposits. I did not apprehend any danger, because there was no tubercular deposit in the lower part of the bladder or prostate, and, as far as symptoms went, there was nothing to indicate any disease of the right kidney. I judged all the trouble to be in the left ureter and upper part of the bladder, on the left side, adjacent to that opening. One milligramme of Koch's fluid was injected at 3.25 p.m. The temperature, which had for some days been normal, rose in the course of half an hour to 100°. Ten and a half hours after it was at its acme, 102°, falling after this by easy stages to normal. The entire duration of the reaction was twenty-four hours. Two and a half hours after the injection the patient had increased pain in micturition. In four and a half hours

[1] Usually the symptoms of urinary tuberculosis are intermittent in their severity.

Digitized by Google

he became very flushed, and the pain in the urethra diminished. Six and a half hours after the injection he had another bad attack of pain on urinating, and strained greatly. He now shivered after each act, but this subsided in two hours. He passed water twenty-one times in the night, and it is noted that the pus in it was three times the usual quantity (the amount of albumen being one twentieth instead of one eighth). On the morning of December 16th he complained of pain in the back, and towards the afternoon the temperature underwent a second rise; at the same time the urine became tinged with blood, and the patient vomited. From this date the vomiting, hæmaturia, and high temperature continued until his death, which took place fourteen days later. The bleeding became constant and profuse, and remained quite uncontrolled, although every drug at our command was tried. The amount of urine, which began to diminish the day after the injection, continued to get less and less, and the albumen in it to increase. Drowsiness, incontinence, and diarrhœa set in; finally coma and death two weeks and a half after the use of the tuberculin. When I found that the hæmaturia was unrestrained by drugs I thought of draining the bladder, but the patient had then become drowsy, and I felt that the operation would not affect the inevitable end. Tubercle bacilli were found in the urine after the injection.

Autopsy.—Body well nourished, pleuritic adhesions on the left side, bases of lungs somewhat œdematous; with these exceptions the thoracic viscera were healthy. On opening the abdomen the bladder was seen distended above the pubes. It contained a large quantity of liquid and clotted blood as well as urine. I was at first surprised to find the capacity of the bladder so great, for in a large proportion of my cases of tubercular ulceration the bladder had usually been contracted. Moreover, the small amount of urine passed each time, added to the residual found in the bladder after the act of urination, was only about 5 oz. The probable explanation of this fact is that the call for micturition was not that of distension, but of reflex irritation from the ulceration of the bladder or prostatic canal; and as the patient became more and more exhausted, the bladder lost its irritability, and gradually became distended, incontinence resulting.

The muscle wall of the bladder was not especially thick, nor was it apparently infiltrated, as proved by microscopical examination. The mucous membrane in the lower two thirds was thrombotic in

Digitized by Google

patches, this condition being more marked in the neighbourhood of the left ureter, and seemed to have some relation to a large ulcer which lay on the left side of the outer limb of the trigone at the junction of the middle with the posterior third. It was about the size of a threepenny piece; its base was smooth and not sloughy, its edge was sharp and blood-stained. At the neck of the bladder, overhanging the orifice, was a pea-sized collection of crude tubercle, which projected from the surface in a manner similar to what I have observed in other cases by electric cystoscopy.

I was quite unable to find any orifice to the left ureter. The right ureteral orifice was patulous and much inflamed; left ureteral opening *could not be found*, only a faint dimple at the left extremity of the interureteral bar served to indicate where it should have been.

No other deposit could be discovered in any other part of the lower two thirds of the bladder, but in the upper third there was a condition which I am not acquainted with. The upper third appeared *shining and uncongested*, and I was showing it to others who were assisting me as being unusually free from disease, when my attention was directed by my dresser to a shallow abrasion. By throwing the light obliquely upon it, it was clear that there was no doubt of the loss of substance, but its edge was without any signs of congestion or sloughing. Other and similar abrasions were detected in the neighbourhood. I selected the largest and cut it across. The section showed that a distinct layer of laudable pus lay between the abrasion and the subjacent muscle layer. It seemed, at first sight, as if a focus in the submucous tissue had become inflamed and had suppurated, and that the superficial mucous membrane had caved in, leaving a shallow depression on the surface. This ulcer was subsequently embedded in celluloidin and sections made; it was then evident that an ulceration was present, having a small collection of pus beneath its base.

Prostate.—No deposit could be found in the prostate, but on slitting up the prostatic canal an empty abscess cavity was detected by the side of the verumontanum. It was the size of a small monkey nut; there was also a small fistulous tract (a false passage) leading to the right and starting from the uvula vesicæ. Testes and vesiculæ seminales were healthy.

Kidneys.—The left kidney was a very thin-walled multilocular sac; microscopically it shows the atrophic remains of a few

Digitized by Google

glomeruli and tubes. The sac contained a clear fluid in which was floating a fine lace-like mass of coagulated lymph. The ureter was patent, and neither thickened nor enlarged until within one inch of its vesical opening. At this point there was an oval hard swelling, in shape like a date-stone, on incising which an elongated collection of phosphatic material was found to be obstructing the canal. The right kidney was very large; it weighed 1 lb., and had evidently been doing the work of the other. In its substance were many small collections of pus, and microscopically it was found to be in a state of acute suppurative nephritis. The hilum was filled with large lymphatic glands, which to the naked eye appeared scrofulous. The ureter was enormously and apparently causelessly dilated, its walls being thin, its mucous surface intensely inflamed; and it contained, including the drainage from the pelvis, three ounces of pus. As I was at a loss to understand where the tuberculosis had originated, I had sections cut from all parts of the urinary tract and carefully examined for bacillus. Mr. Targett, to whom they were sent, reported upon them as follows:—"There is little to be added to the evidence derived from naked-eye appearances.

"(*a*) In the right kidney the changes are entirely those of ascending pyelo-nephritis; there are no tubercle bacilli in it.

"(*b*) The left kidney is simply dilated, and shows consecutive fibrosis.

"(*c*) The lymphatic glands near the right kidney contain multiple caseous nodules, which are certainly tuberculous, though the bacilli are not demonstrable.

"(*d*) In the prostate and in the globus major of the epididymis there is nothing worthy of note.

"(*e*) The interior of the bladder shows a superficial ulceration, which gives the mucous surface a reticulated appearance; sections taken from near the neck of the bladder contain caseous tuberculous nodules, composed of giant-cells and small round cells.

"Sections from the fundus of the bladder show inflammatory changes in the submucous tissue and ulceration of the mucous membrane in places, but there is no distinct evidence of tubercle."

Remarks.—The interesting points in this case are—

1. The complete absence of a left ureteral orifice, and the question whether this condition was congenital or acquired. Looking to the fact that the left kidney was very small, that its secreting

Digitized by Google

tissue was a thin microscopical layer of atrophic tubes and glomeruli, and that the ureter was of normal size though its calibre was reduced, I am inclined to believe that the condition is congenital (compare vol. xxxvii, p. 300); and this view is sustained by the large size of the right kidney and ureter, and by the entire absence of left renal pain until a few months before death. It also appears to me probable that the loose phosphatic material found at the vesical end of the left ureter was the result of the occluded outlet rather than the cause of the atresia.

2. The evidence of primary vesical tuberculosis being most marked in the neighbourhood of the left ureter—an unused canal.

3. The upper third of the bladder showing ulcerations of an inflammatory non-tubercular type, perhaps due to over-distension.

The important feature in the case is, of course, the danger of using tuberculin, even in the smallest dose, in urinary tuberculosis where septic processes are co-existent. *April* 21*st*, 1891.

---

5. *Specimens of the* Distoma hæmatobium (Bilharzia hæmatobia), *with the urinary organs and lung containing ova.*

By Anthony A. Bowlby.

I am indebted to my friend Dr. Mackie, of Alexandria, for the specimens exhibited to-night.

The first patient was a country Arab, who was admitted into the hospital under Dr. Mackie, passing foul and blood-stained urine, and was in a very emaciated condition. Micturition caused great pain, and was very frequent. By examination above the pubes and *per rectum* the bladder was found very greatly thickened, so that it felt as though it contained a malignant tumour. The urine contained innumerable ova of the *Bilharzia hæmatobia*.

In order to relieve the patient's sufferings an incision was made in the perinæum, and the bladder was drained; but although the operation was successful in relieving the pain, the patient sank, and died fourteen days later.

A *post-mortem* examination discovered in the portal vein numerous specimens of the Bilharzia parasite; and these, to the number

Digitized by Google

of thirty-seven, were sent me by Dr. Mackie, together with the urinary organs and portions of the lungs and spleen. All the worms were of the female sex.

The bladder is very contracted and greatly thickened; its mucous coat also is much diseased, being thickly covered with a shreddy mass of growth, which, when submitted to a stream of water, is seen to be finely fibrillated and villous.

The ureters are greatly dilated, their walls are thickened, and their mucous membrane is covered with a thick, rough, whitish deposit, chiefly phosphatic in its nature. The mucous coat is not villous like that of the bladder.

The kidneys are much diseased. Their pelves and calyces are dilated, their pyramids are atrophied, and the remaining renal tissue is softened by inflammation and streaked with pus.

Microscopical examination shows that the thickening of the bladder wall is due to an interstitial growth of fibrous tissue, and perhaps, to a slight extent, to increase of the muscular coats. The mucous membrane has been destroyed, and in its place there is a growth from the submucous tissue of young fibrous tissue, rich in cells, and evidently disintegrated and broken up by soaking in purulent urine. It is of this tissue that the villous processes are formed, and embedded in it, and in the rest of the bladder wall, are innumerable ova of the Bilharzia.

Sections of the ureters show infiltration of their walls by inflammatory new formation, and enormous numbers of ova in the submucous tissue. Unlike the bladder, the ureters retain in almost all their extent their mucous lining, and through this in places the ova can be seen making their way, causing a catarrhal inflammation and shedding of the superjacent epithelium.

The kidneys show much catarrh of the tubes and general infiltration of leucocytes in all parts. They also contain many ova, which are most numerous in the walls of the pelves and calyces.

The lungs also contain ova, though they are not nearly so numerous in these viscera as in the bladder and kidneys. The lungs are almost solid throughout.

Digitized by Google

6. *Bladder affected with* Bilharzia hæmatobia. (*Card specimen.*)

By Samuel G. Shattock.

The left half of a urinary bladder. About its neck the mucous and submucous coats are thickened and indurated from chronic inflammation; and in this situation the mucous membrane on the posterior wall presents five or more small but deep ulcers, two of them considerably undermined; around some the membrane is lowly papillary. The inflammatory process involves the tissues contiguous with the base of the bladder for a wide extent, the vesicula seminalis and lower end of the ureter being firmly incorporated with the parts in front by intervening indurated fat and connective tissue. The ureter is thickened, and so dilated as to measure in the collapsed condition 1·5 cm.; but its mucous membrane is intact. The other ureter, and the pelvis and calyces of both kidneys, were similarly dilated.

The specimen was from the body of an Egyptian, aged 25, who was admitted February 17th, 1888, into the Government Hospital, Alexandria, under Dr. Schiess; and it was presented to the museum of St. Thomas's Hospital by Dr. Sandwith. The patient had suffered for many years from hæmaturia and symptoms of vesical disease, and for two years with symptoms of stone in the bladder. Death took place a few days after admission, from uræmia.

Post-mortem.—Twelve hours after death. Lungs normal. Heart hypertrophied. No parasites in the cardiac blood. Mitral valve thick; the aortic valve presented three thickenings the size of lentils. Liver small, congested. The vena portæ contained thick, dark red blood, with thirty of the parasites in a single teaspoonful. Spleen normal. Stomach and intestines enlarged. Mesenteric glands large.

The bladder contained a calculus, and two small calculi were found buried in the thickened wall.

Microscopic sections made through one of the papillary areas show numerous collections of the Bilharzia ova in the mucous and submucous tissue, and in the connective tissue of the papillary processes themselves. In all of the ova in which it is discernible

Digitized by Google

the spine is placed terminally, and not on the side. The microscope disclosed no ova in the mucous membrane of the kidney.

In the thirty-third volume (p. 140) of the Society's 'Transactions' is a brief but very complete account of the condition by Dr. Zancarol, of Alexandria.

He reported two cases, one in which the colon was the seat of the disease, the other the bladder; and he notices that the ova in the first situation presented a lateral spine, whilst the spine of those in the bladder was terminal. The present specimen coincides with Dr. Zancarol's, in that all the ova present the terminal spine.

Since the date referred to, five specimens of the disease have been exhibited at the Society, but in none is the position of the spine recorded.

Vol. xxxviii.—Urinary organs from a case of *Bilharzia hæmatobia*. By Reginald Harrison.

Vol. xxxix.—*Bilharzia hæmatobia* of the bladder associated with carcinoma. By E. Hurry Fenwick and Dr. Thomas Harris.

Urinary bladder and kidney from a case of *Bilharzia hæmatobia*. By F. S. Eve. In this case, in addition to the disease of the bladder, ova were found in the capillaries of the lungs, kidneys, and skin.

Vol. xlii.—*Bilharzia hæmatobia* affecting the bladder, ureters, kidneys, and lungs. By Anthony A. Bowlby.

Bilharzia hæmatobia affecting the rectum, and leading to the production of a papillomatous outgrowth of inflammatory tissue. By Anthony A. Bowlby.

By Mr. Edgar Willett's kindness I have been able to examine portion of a specimen in the museum of St. Bartholomew's Hospital (Series 19, 50, 2065 D.), similar in kind to that shown by Mr. Bowlby; it was removed from the rectum of a young Arab who had had similar growths removed on a previous occasion. The microscopic sections display numerous ova, and in all the spines are *terminal*. In Dr. Zancarol's case of diseased colon, the spines, as before noticed, were all *lateral;* in the bladder, *terminal*.

So far as the intestine is concerned, therefore, it will appear that no particular position of the spine is associated with this location of the ova. 1891.

Digitized by Google

7. *Hydatid cyst between bladder and rectum; retention of urine; surgical kidneys; death.*

Reported by JOHN R. LUNN.

THE following case is of sufficient rarity that its record may possess some surgical interest.

Robert R—, aged 66, a newsagent, was admitted into St. Marylebone Infirmary on October 29th, 1889. He stated that he had had some difficulty in passing his water about a year before admission, but never had been troubled by any urethral stricture. Three weeks before admission he suffered from retention, and was obliged to have his urine drawn off by a catheter at a hospital. After he had had the catheter used he could sometimes pass his water very well, at other times the water would dribble away. On one occasion when the catheter was passed no urine came away, though he felt sure his bladder was distended. He suffered much pain about the groin of his bladder before admission to the infirmary, which was generally relieved by the catheter being passed. On admission the patient appeared very ill. He complained of retention, his bladder being enormously distended; at the same time his bowels were confined. A No. 10 catheter was passed under $CHCl_3$, which only drew off bloody urine. As the catheter got repeatedly blocked by blood-clots, the bladder was tapped above the pubes, and a large cannula fastened into the bladder. After the bladder had been relieved a definite swelling was to be felt under the abdominal wall above the bladder, which receded into the pelvis when the bladder was quite emptied. On examination by the rectum, nothing was detected except a painful trigone when pressure was made with the finger. The tube was removed from the bladder after four days, as the patient was able to pass urine by the urethra, the bladder being washed out night and morning, and the patient made an uninterrupted recovery. On November 23rd it was noted that the bladder could be completely emptied by passing a catheter, but there was still some dulness on

Digitized by Google

percussion above the region of the bladder, and slight prominence to the right of the median line after it had been emptied. The urine at this time was again "alkaline," and contained a trace of albumen. The patient took his discharge on April 17th, 1890, because he said he never felt better in health. He was readmitted August 6th, and appeared very ill. Temp. 101·2°. Tongue furred. Pulse 120, very quick and small. Expression of face anxious. Bladder again very distended, dulness extending up to the umbilicus. No catheter was able to be passed, so the bladder was aspirated by the pubes, and 40 oz. were drawn off, which contained pus, albumen, and blood. The aspiration of the bladder gave immediate relief, and it was again noted that some dulness remained above the bladder after the water had been drawn off. On examination by the rectum, which caused the same amount of pain as before, a large soft mass could be felt between the rectum and bladder, partly screening the latter. The prostate was not notably enlarged. The urine had to be drawn off several times in the day. His temperature became very hectic. Diarrhœa set in; he became comatose, gradually sinking. Died August 9th, 1890.

At post-mortem (30 hours after death).—Rigor mortis passed off in hands; lower limbs stiff. Right lung adherent by old bands to chest wall.

Lungs.—Substance healthy. No fluid in thorax. On opening abdomen, bladder was seen pushed out in front by large tumour behind. Bladder and tumour were removed together. To the tumour intestines were adherent behind. It came from cavity of pelvis, between the bladder and rectum, and was strongly fixed to the floor of pelvic cavity. The tumour consisted of a hydatid cyst, was triangular in shape, the base of the triangle looking upwards, and about the size of a child's head. On puncturing it a large amount of clear fluid came out, and the wall was seen to consist of an outside membrane. Inside this was a thick, opaque white membrane, about one eighth of an inch thick. In the cavity, besides the fluid, were a large number of round white bodies, about the size of a large pin's head. Most of these were lying in the fluid, and a few were attached to the wall. Under the microscope they consisted of a number of scolex heads joined together, each head showing a mouth and circle of hooklets. The fluid was faintly albuminous, sp. gr. 1012.

Digitized by Google

NaC, 2½ gr. to ounce.
No sulphates or nitrates.
No sugar.

The anterior wall of the cyst was adherent to the bladder. The posterior wall had the intestines attached behind.

Bladder.—The wall was very much thickened. The cavity was small. One small loculus big enough to receive the end of the little finger was seen leading from inside. The lining membrane was red and congested, marked in parts with streaks of blood. The posterior surface was attached to cyst. On each side the ureters were seen leading into bladder. These were enlarged, being about the size of a lead pencil, and had thickened walls.

There was no communication between cyst and bladder.

Kidneys.—Left kidney was enlarged. The ureter leading from it was about the size of a man's thumb, distended and with thickened walls, showing signs of chronic inflammation and hypertrophy. The pelvis of kidney was dilated and contained pus. On section there were several small cavities in the kidney substance which contained earthy material, soft and crumbly, apparently phosphates. The cortical substance showed signs of acute inflammation with small abscess cavities (surgical kidney). Right kidney and ureter showed similar conditions as left, but were not so marked.

Remarks.—The question arises how these cysts are developed in the pelvic cavity. The right explanation appears to be that the embryo getting into the peritoneal cavity, and gradually gravitating downwards, eventually settles in the pelvic cavity.

The cases are on record in which the hydatid cysts have been found between the bladder and rectum near the neck of the bladder, but I cannot find any cases where they have been quite between the bladder and rectum.

It was not until the case had been cleared up by an autopsy that the real nature was discovered.

Mr. Targett's account of the tumour.

The cyst is situated behind the bladder and in front of the rectum. Its upper end is covered by peritoneum, continuous with that on the fundus of the bladder, and its lower end is wedged in between the base of the bladder on one side, and the vesiculæ seminales and vasa deferentia on the other. Thus it lies between

Digitized by Google

the muscular coat and the recto-vesical sheath, at least in the lower part. The vesiculæ seminales are much enlarged and flattened out; one vas could be traced upwards in the wall of the cyst, not on the bladder at all. The ureters were likewise lying against the sides of the cyst. *November 18th*, 1890.

---

8. *Large hydatid cyst in the pelvis pressing upon the bladder and causing obstructive suppression of urine.*

By E. Hurry Fenwick.

In 1886 I brought before this Society a case of a large bilocular hydatid cyst which was attached to the back of the urinary bladder ('Transactions,' vol. xxxvii, p. 317).

In recording a second instance of the same disease I have thought that a brief review of the literature of the subject would prove of interest.

The details of my second case are as follows:—On September 14th, 1890, I was sent for to see a case of suppression of urine by Mr. Robert Debenham. The patient, a young man of twenty, was greatly emaciated and in a grave state of exhaustion; sordes were on his lips, tongue, and teeth, and he spoke with difficulty and in a whisper. There was no supra-pubic distension and no distress to urinate. On the right of the pubes a firm fleshy mass could be felt. This I took to be the contracted bladder shoved up by rectal distension, for it was similar to the contour of the empty bladder when it is thrust up by the Braune-Garson method. On passing a catheter there was a hitch at the prostate, but it entered easily, no urine was evacuated, and it was withdrawn without even a drop of water in the eye. The finger was therefore inserted into the rectum to ascertain the cause of the obstructive suppression. It encountered an elastic semi-fluctuant mass, which did not spring from the prostate, but was obviously in the recto-vesical pouch. Bimanually this mass was found to be in intimate connection with the fleshy, contracted, dislocated bladder above the pubes. Many small, shotty, perirectal glands could be felt between the mass and the rectal wall.

Digitized by Google

I did not know whether I was dealing with a soft sarcoma or with a hydatid, and the history did not throw much light upon this question. For some years the patient had had frequency of micturition in the daytime, and had had to get up twice at night to empty his bladder; but he had never seen any blood, and his water had always appeared healthy. He had been suffering from headache and sickness since Christmas, 1889, the headache ceasing two months ago, but the sickness continuing up to the present time, and generally coming on the first thing on rising. These symptoms suggested that an insidious interstitial nephritis, due to compression of the ureters, had been progressing for some months. A month ago he felt so weak that he could not work, and was obliged to remain in bed. Last Monday night, September 9th, he was awaked by a severe cramp beginning in the thighs and extending up to the lower part of the belly. This was continuous for twelve hours. On Thursday, September 12th, these cramps began again, and since that time he had passed no urine.

The ordinary remedies were exhibited, but without effect, and next day, September 15th, I determined to aspirate this tumour through the rectum. Before doing so, however, I inserted a catheter, but failed to draw off any urine, though the instrument was introduced to the hilt. I therefore thrust the aspirator into the tumour through the rectum, and drew off some few ounces (3—4) of clear fluid, evidently from a hydatid cyst. I immediately passed a catheter, and evacuated two ounces of blood-stained urine. Obviously, by reducing the bulk of the pelvic hydatid, I had enabled the ureters to empty their dammed-up contents into the bladder.

The patient felt much relieved, and the next day, Monday, he passed voluntarily 30 oz. of urine. I thereupon proposed to perform a supra-pubic cystotomy, lift up the peritoneum from off the upper surface of the cyst, open it and evacuate its contents. I hoped thus permanently to relieve the pressure upon the ureters, for I was certain, from the small amount of fluid that I had withdrawn from the cyst by aspiration, that it was mostly filled with secondary cysts. On Wednesday morning early, the day fixed for the operation, the urine suddenly stopped, and at 8 a.m., whilst he was being supported on the night-stool, he dropped back dead.

Post-mortem (the same day).—Body much emaciated, no distension of abdomen. Above the pubes, and somewhat to the right, was a

Digitized by Google

slight projection formed by the bladder pushed upwards by the pelvic tumour. On opening the abdomen the intestines were found empty; the liver was healthy, and contained no hydatid cyst; the other solid viscera were healthy. Head unopened by request. On removing the intestines the kidneys were seen to be very large, but on cutting into them they were found to be mere sacs with thinned cortices and enormously dilated pelves; each ureter was dilated to the size of a child's small intestine, and both these conducting tubes were full of urine.

As the ureters turned over the pelvic brim they were compressed by the hydatid sac, and from this point to the bladder these canals were of normal size and contained no urine. Rising out of the true pelvis was a large, tense, milk-white hydatid cyst which completely filled that cavity, and, fully engaging its brim, nipped both ureters and the rectum at that level. The bladder was also dislocated upwards and to the right. Its upper half contained a couple of ounces of urine, for it was rather compressed into an hour-glass shape against the edge of the pubes, the lower and empty compartment being flattened against the posterior surface of the pubes. The specimen was sent to the College of Surgeons Museum, and Mr. Targett kindly examined it and reported as follows:—"Dissection shows that the cyst is entirely outside the peritoneum, between the muscular coat of the bladder and the recto-vesical sheath. Its upper surface, P (Fig. 12), is covered with peritoneum, which has been stripped off the back of the bladder; and behind it there is a narrow pouch of peritoneum, extending along the front of the rectum, which is the compressed, though otherwise normal, recto-vesical pouch, R. Crossing the lateral surfaces of the cyst are the ureters and vasa deferentia, and on its under surface may be seen the vesiculæ seminales, which are much displaced by the intrusion of the cyst between them and the base of the bladder. The anatomical arrangement of the parts in the neighbourhood of the cyst corresponds closely with what I have previously observed in four or five other specimens of a similar nature. These cysts are situated, not in Douglas's pouch, but *outside* the peritoneum—in fact, between the muscular coat of the bladder and its recto-vesical sheath. From this it follows that, owing to the close union of the vesiculæ seminales and vasa deferentia to the recto-vesical fascia, the progressive enlargement of a subjacent cyst will lead to their separation from the wall of the bladder, as illustrated in the

Digitized by Google

present preparation, and one more recently shown by Mr. J. R. Lunn at this Society. The negative conclusion that may be drawn regarding the origin of some, at least, of these cysts, is that they

FIG. 12.

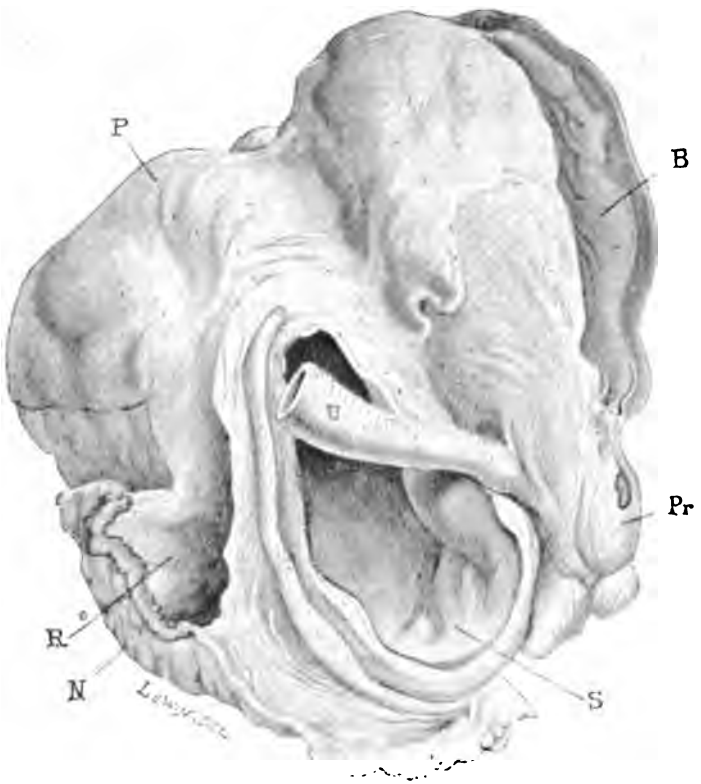

R. Peritoneum lining the recto-vesical pouch, which is narrowed by the projection backward of the hydatid cyst. S. Cavity of the hydatid cyst crossed by the ureter, U. B. Anterior wall of the bladder cut vertically. Pr. Prostate below the prostatic urethra. N. Anterior wall of rectum.

are not due to the gravitation of embryos into the recto-vesical pouch from any of the abdominal viscera, a view which is commonly maintained in text-books."

Literature.—I have found ninety cases of this disease in the literature of the last 200 years, the first being recorded by

Digitized by Google

Dr. Tyson in 1687; and though the search has been as thorough as possible there is no doubt some cases have been overlooked. It is sufficiently obvious, however, that hydatid cysts in the pelvis are not common, Davaine placing them in the lists as occurring in 7·9 per cent. of all cases. A consideration of these recorded cases permits of the following conclusions:

Size of the hydatid cyst.—The size and shape of the hydatid cyst in the pelvis varies considerably; dependent, it would appear, upon the amount of its *fluid* contents. The similes used to give an idea of the size are—"the sac was the size of an ostrich egg"—"of a neckless quart bottle"—"of a twelve-pound shot"—"of a child's head"—"of a fœtal head"—"of a fist." They are recorded also as containing 3 pints, 80 ounces, 20 litres, 3 quarts. Naturally the appearance of the belly in these cases has been sufficiently remarkable to attract attention and merit description; one man, aged 59, is mentioned as if "far advanced in pregnancy," another as appearing as if he were "three months pregnant." Such expressions as "treated for ascites," "simulating ascites or ovarian disease," "distended to two inches above the navel," are met with, and give the reader some idea of the appearance of those cases in which the cyst had caused the urinary bladder to become enormously dilated by pressure upon the prostatic urethra.

Structure of the sac.—This varies greatly in thickness, "from a dense fibroid calcareous wall" ¼ inch thick to a "clear transparent gelatinous sac, through which colonies of scolices could be seen growing on the inner surface" (Allen's case). Usually the sac is single, but in a few cases it was bilocular or even multilocular.

Position and origin of the sac.—This, as ascertained by careful *post-mortem* examination, was proved most often to be between the rectum and the bladder, and a fair number of dissections show that the sac originated, as Mr. Targett has pointed out in his report upon my own cases, *outside the peritoneum*, between the muscular coat of the bladder and the recto-vesical sheath, the pouch of Douglas being practically free. Doubtless mistakes have arisen by the pathologist finding the pouch of Douglas obliterated by localised inflammation from the irritation of the parasite, which had caused the peritoneal wall of the cyst to adhere to the front of the rectum and the surrounding parts. He had thus been led to believe that the sac had dropped from above into the true pelvis and grown there. This supposition has received colour from the fact that in

Digitized by Google

a very large proportion of the cases other cysts are discovered coincidently in the omentum, the liver, the mesentery, the spleen, or the iliac fossæ.

Although the extra-peritoneal site is the general rule, yet certain very remarkable exceptions are mentioned :

(*a*) A hydatid cyst, the size of a man's head, was found after death to be filling the pelvis of a woman aged 30 ; it lay between the uterus and the rectum, and had originated in the ovary, which had fallen into the pelvis and contracted adhesions there (Barret's, also Potocki's case).

(*b*) "A cyst, the size of a twelve-pound shot, was found free and moveable between the viscera ; its pedicle, the size of a little finger, was fixed to the posterior inferior ligament of the bladder" (Lelouis).

(*c*) Female, aged 55. "Senile uterus pushed forwards and to the left by a tumour the size of a child's head ; this was adherent to the posterior wall of the uterus by repeated attacks of circumscribed peritonitis near the tumour. A band was discovered, a foot long, running from the tumour to the right lobe of the liver ; the connecting link was as thin as a thread. The deep yellow colour of the membrane points at the liver as being the original site of the cyst. It had developed in the substance of the liver, become protruded from its surface, then pediculated, and hanging down into the pelvis acquired adhesions there" (Freund and Chadwick).

(*d*) In four instances especial mention is made that the hydatid formed in the prostate gland.

Sir Henry Thompson, after quoting from the literature six cases of hydatids between the bladder and rectum ('Diseases of the Prostate,' 5th edition), says, "It is doubtful if hydatids have ever been met with in the prostate." These cases therefore deserve mention.

1. Lowdell ('Trans. Med.-Chir. Soc.,' vol. xxix, p. 253).—"Male, aged 64. In the situation of the prostate gland was a tumour larger than a fœtal head, which, when cut open, proved to be a hydatid cyst so full of hydatids compressed together that the cut surface presented a wavy appearance, the true substance of the prostate being lost in this thickened cyst. The course of the urethra was healthy throughout ; but the prostatic portion had been so pressed upon by the tumour that in attempting to pass the catheter numerous false passages had been made in every direction. With the exception of a small portion in front of the false passage

Digitized by Google

through which the catheter was passed, the whole of the substance of the prostate was lost; but whether the hydatid cyst was formed in the prostate itself, or whether the cyst originated externally to the gland, is a matter of doubt."

2. Tillaux ('Bull. Soc. de Chir.,' tome ix, 1883, p. 143, "Kyste hydatique de la prostate").—Male, aged 43. A year before admission patient had a difficulty in responding to the call of the bladder at night. There was coincident constipation. A hydatid cyst, which M. Tillaux had no doubt sprang from the substance of the prostate gland, was found on rectal examination and opened. It had been mistaken for a cold abscess, for the patient had scrofulous scars on the right side of the thorax. Cured.

3. Millet ('Bull. Soc. de Chirurg.,' vol. x, p. 551, 1884).—Male, aged 59. Retention of urine, a large tumour found occupying prostatic region, and which also filled pelvis. In the attempt to pass a silver catheter the point plunged through the wall of the hydatid cyst, and 700 grammes were evacuated. This case ultimately got well, and the author believes it was situated in the prostate.

4. Butreuille ('Bull. de la Soc. Anat.,' 1878, p. 265).—Male, aged 69. Retention of urine for many days, difficulty in catheterism, false passage ("sonde a demeure"). An enormous tumour was found in the position of the prostate, but was supposed to be an abscess; surgical kidney; death. *Post-mortem.*—A multilocular transparent cyst occupied the anterior part of the prostate, separated only from the urethra by a thin bridge of prostatic tissue. At the base of the left lung was a nut-sized hydatid cyst.

The last case appears to be quite genuine, but as a comment upon Tillaux's and Millet's cases, and, in fact, on any such not verified by autopsy, I would refer to Walther's case ('Prog. Méd. Paris,' 1887, 2 s., vi, 78). A vertical section of the pelvis was made in the antero-posterior direction, and a hydatid cyst, the size of a small apple, was found placed 1 cm. below the base of the prostate, its upper margin being in contact with the recto-vesical *cul-de-sac*, to which it was strongly adherent. It is evident how easily a subprostatic hydatid—and many extend beneath the prostate—may be diagnosed as being purely prostatic.

In 52 cases in which the *post-mortem* has plainly indicated the exact site of the hydatid cyst the following positions were noted:

Digitized by Google

Between the posterior wall of the bladder and the rectum	22 cases.
Between the neck of the bladder and the rectum	4 „
Prostatic (? 2 cases)	4 „
Pedicled to the posterior wall of the bladder	1 case.
"In the cellular tissue of the right seminal vesicle"	1 „
To the right of the bladder	1 „
Cyst on either side of the bladder	2 cases.
To the apex of the bladder	2 „
Vesical orifice of each ureter	1 case.
Between the bladder and the uterus	5 cases.
Between the uterus and the rectum	3 „
Between the vagina and the rectum	2 „
To the uterus and surroundings	1 case.
In the mesorectum	3 cases.
	52

Mallez, 1878, quoted by Nicaise, gives "hydatid tumour of prostate; puncture, suppuration, cured" ('Soc. de Chirurgie,' vol. x, p. 554, 1884, Case 26). I have not been able to get the original history of this case.

The clinical symptoms due to the pressure of the pelvic hydatid cysts.—In very few cases (four) it is expressly stated that the hydatid evoked no symptoms. In two of these the cyst was small in size, and in the others, although the hydatid sac was large, it was apparently easily accommodated; thus in Habershon's case it lay to the right of the bladder, and contained three pints of cysts, and although it reached as high as the umbilicus, yet the patient asserted that he had never experienced any difficulty in micturition, nor had he suffered any pain in the lower part of the abdomen. In Richter's case, although a large sac existed beneath the peritoneum at the apex of the bladder, yet there was no difficulty either in micturition or defæcation. Such immunity is very rare.

Usually, as may be supposed, the effects of the pressure of the cyst depend upon its position, its size, and the direction in which it is extending. From its position in the pelvis the first indication of its presence is a difficulty in the evacuation of the viscera in that cavity, the bladder, rectum, and uterus.

In the male the obstruction to the free discharge of the urine may exist either at the ureters or at the level of the prostatic urethra. The former variety is rare, and my second case recorded above is an excellent example. The symptoms are insidious, and are due to the gradual onset of obstructive suppression. In these

Digitized by Google

cases the sac or sacs are placed higher in the pelvis, and either nip the ureters as they turn over the brim of the true pelvis, or, as in Tyson's case, obstruct each ureter at its vesical orifice. In the latter variety, in which the urethra is throttled, the onset symptoms are usually those of stricture, for the sac is placed lower in the pelvis, either below the level of the prostate, in which case they discolate the entire bladder upwards; or, they are situated more posteriorly, and jam the prostatic urethra against the pubes (cf. my first case, vol. xxxvii, p. 317). Usually, therefore, in this group the culminating retention is heralded by dysuria, and repeated efforts to thoroughly empty the bladder with decreasing strength of stream consequent upon the increasing atony. In a certain number it is stated that the first indication of anything wrong was a sudden retention, which the surgeon completely failed to relieve with the catheter, and resource was had to the aspirator or suprapubic puncture, or even perineal section. In one very remarkable case recorded by Mr. Bryant in our 'Transactions' (vol. xvii, p. 278, 1866) the patient had three separate attacks of retention at intervals of seven years. It was quite unrelievable by catheter, but it subsided spontaneously. In many the rectum also suffers from the backward pressure, and obstinate constipation, almost to intestinal obstruction, results.

The following is a synopsis of the *onset* symptoms in both sexes, excluding pregnancies:

Great frequency of urination	1 case.
Incontinence (one case for 14 years)	2 cases.
Sudden and complete retention	12 „
Repeated retentions	2 „
Increasing difficulty and repeated retentions	11 „
Difficulty of defæcation and urination	5 „
Intestinal obstruction	2 „
	35

In the female, though the same symptoms of urinary and alvine obstruction are experienced with similar dangers and results, yet the main interest of these pelvic cysts centres round their tendency to obstruct parturition. The first recorded case is by Park (1811), and similar cases are mentioned by Blot, Paul, Freund, and Chadwick, and others.

I have lately found that this subject has been fully treated by Porak ('Gazette Hebd. de Méd. et de Chirurg.,' 1884, p. 206), and

Digitized by Google

as his statistics of the results are fuller than those I had prepared I take the opportunity of substituting his for my own.

Pelvic hydatid sacs in pregnant women have caused—

Premature delivery (Paul, Park)	Twice.
Difficult but spontaneous delivery (Park, Roux, Mundé)	5 times.
Delivery necessitating forceps (Doléris, Porak)	Twice.
Spontaneous delivery after puncture of the cyst (Blot, Guéniot, Spoeth)	Thrice.
Spontaneous delivery after opening the cyst (Park, Paul, Mundé)	"
Forceps needed in spite of puncture (Birnbaum)	Twice.
Cranioclast needed in spite of the use of forceps (Wilner)	Once.
Delivery impossible (Caseaux, Pintos-Pasella)	Twice.
Cæsarian section (Puchell, Sadler) both deaths	"
Difficult obstetrical intervention (Brill, Kuchenmeister)	"
Total	17 cases, comprising 24 deliveries; 6 died.

The pathological effects of the pressure of pelvic hydatids.—In the male, the chief stress of the pressure caused by the increasing bulk of the tumour falls upon the most moveable viscus in the pelvis, the bladder, and it is quite remarkable what changes of shape that organ undergoes. In most cases it is dislocated upwards and forwards, the urethra being correspondingly dragged up with it into its new position. The urethral tube is either stretched vertically upwards or bent acutely to one side or the other. This alteration in the normal course of the urethra explains why the surgeon has found it quite impossible to introduce the catheter in a very large proportion of cases of retention due to this disease. In James' case the sac had pressed the bladder so forcibly against the pubes that that viscus had assumed an hour-glass shape. The lower compartment was found empty after death, for it had been evacuated by Cock's operation, and a pint of urine had been thus removed from it. The upper compartment had not been tapped and was found to contain two pints. In Perrin's case the bladder had been pressed into a left scrotal hernia, and had assumed a bisacculated shape, the constriction being situated at the pelvic brim. The herniated part of the bladder held 150 grammes of urine. In Bryant's case, to which allusion has been made, the bladder was found dislocated into the left iliac fossa. It was completely raised out of the pelvic cavity and contained a quart of urine.

Pressure upon the rectum was produced in Obre's case by a large hydatid in the meso-rectum, which not only impeded the

Digitized by Google

passage of the fæces, thus causing fatal obstruction, but also had induced sloughing of the coats of the bowel at this spot. Usually, however, the rectal tube is merely flattened against the concavities of the sacrum and coccyx.

Pressure upon the kidneys and ureters.—It is perhaps needless to mention that, in the large majority of the accounts given in the post mortems, the urinary tract is described as being enormously dilated behind the obstacle, the ureters being greatly distended with urine, the kidneys reduced often "to mere bags." Superadded to this are the evidences of acute ascending pyelo-nephritis in those instances in which surgical interference had been rendered necessary.

Rate of growth.—It is probable I think that these pelvic cysts are very slow in growth, for often the tumour had been noticed for some years before the culminating attack terminated the life of the patient. Thus, in Viti's case, the cyst is said to have existed for forty-five years, and others are noted as having produced symptoms for twenty years (Le Sauvage), six years (Cullum), three or four years (Lowdell). The sudden onset of dangerous symptoms of obstruction to the bladder or bowel in these cases in an apparently healthy person is most likely due to the sudden increase in the fluid contents of the tumour, or congestion.

Age.—After forty, as the following table will show, the decades are equally affected. The large number of cases which occur between twenty and thirty is made up of women with obstruction to parturition.

Between the ages of—

1 year and 9	1 case.
10 „ 19	4 cases.
20 „ 29	14 „
30 „ 39	4 „
40 „ 49	8 „
50 „ 59	10 „
60 „ 69	8 „
Over 70	1 case.
	50

The methods of spontaneous cure.—The cases in which spontaneous cure took place are very few but instructive. In Sibille's case, a land steward, aged 48, was attacked with complete retention. After violent and prolonged straining he suddenly felt a tearing

Digitized by Google

sensation in the pelvis, and a tumour appeared between the right tuber ischii and the root of the scrotum. The pain immediately ceased and the urine was evacuated naturally. Gradually the surface of the perineal swelling became inflamed, the skin sloughed over it, the tumour burst, and discharged hydatid cysts. It was estimated that 1200 cysts of large size were evacuated through the opening before the cure was complete. (Compare Dolbeau's case, 'Gaz. Hôp. de Paris,' 1867, p. 276.)

The hydatid cyst has been known to burst into the rectum, vagina, the bladder, and the Fallopian tube. The order of frequency is as follows:

Into the rectum	3 cases.
Into the bladder	2 „
Into the perinæum	2 cases (in Dolbeau's case it projected upon the perinæum).
Into the vagina	1 case.
Into the right Fallopian tube	1 „

In a few cases, the bursting of the sac into the rectum has been *induced* by rectal aspiration, the cyst refilling after the tapping, and subsequently forcing open the track made by the trocar. The same remark applies to the vagina, and these cases are not included in the above list. No case is on record of the cyst bursting into the peritoneum. This is what might have been expected, for the thickness of the cyst wall is greater towards the peritoneal cavity, and the pressure of the expulsive efforts would all tend to weaken the inferior wall rather than the superior and posterior.

As regards the breaking of the cyst into the bladder there are only four cases on record,[1] and two of these are to be accepted with question:

(*a*) Tyson, 1687. The case consists in the report of a *post-*

[1] Mr. Edwin M. James, of Melbourne, Australia, has lately mentioned to me this case, which occurred in his practice. It is as yet unpublished, but he kindly permits me to quote the following facts:—A man, aged 55, having for long suffered from difficulty and pain in micturition, began to waste very rapidly. A fœtal head-sized tumour was found in the region of the bladder, and a grave prognosis was given in consultation. The case terminated in a cure, after the sudden disappearance of the tumour and the simultaneous appearance of a large quantity of hydatid fluid in the urine. With a large experience of hydatids in all parts of the body, Mr. James considered the case unique.

Digitized by Google

mortem. In the account it is stated that a hen's egg-sized cyst, presumably in the subperitoneal tissues, was found pressing upon the mouth of each ureter, and the bladder was found full of cysts, some larger than a goose's egg, floating free in the water of the bladder.

(*b*) Fynney, 1789. A female, married, no children, felt something give way with a snap in the belly in the region of the bladder, and soon after she experienced a difficulty in micturition, whereupon blood and a hydatid cyst was evacuated. There was subsequent uncontrollable vesical spasm and irritation. She died, and an autopsy was not obtained. With so little evidence before us I do not think this case can be accepted, for the parent cyst may have been situated in the kidney and burst into the ureter. There are about 100 cases of renal hydatids on record, and of which four cases have been under my own care. These are apt to burst into the ureter.

(*c*) Birkett's case, 1855. This case has been so often quoted and misquoted, that perhaps it is the same as that mentioned by Bright in his memoir on abdominal tumours, 1860. Birkett's is, as far as I know, the only unquestionable case of the spontaneous bursting of a pelvic cyst into the bladder. A man was admitted into Guy's Hospital suffering from retention; a catheter was passed and some hydatids evacuated through it; he died, and a large hydatid cyst was found between the bladder and rectum.

Treatment.—Although the question of treatment does not interest this Society, yet it is instructive to notice that when the cyst had by pressure and inflammation become adherent to the wall of the rectum or vagina, and the pelvic cellular tissue had been, so to speak, shut off from the subperitoneal layers, that the patient had a much better chance of recovery than when the surgeon aspirated, for in a very large number of instances the sac suppurated after aspiration, and the patient subsequently died of septic peritonitis or cellulitis. These cases were before the days of surgical asepticism, and those who wish to know the best methods of treating these cases in the future, cannot do better than read the valuable case reported by Mr. C. J. Bond, of Leicester, in the 'British Medical Journal' of April 11th, 1891, p. 795.

Literature.—Charcot and Davaine have laid the basis for the study of this especial disease, the former having collected 12 cases ("Mémoire sur les Kystes du petit bassin," 'Gaz. Méd. de Paris,'

Digitized by Google

1852), and the latter 30 ('Entozoaires,' 1877). Neisser adds 5 more cases, quoting 35 out of 805 cases of hydatid disease. Porak ('Gazette Hebd. de Méd. et de Chirurg.,' p. 206, 1884) collected 17 female cases, which I have quoted in the text. I have used M. Davaine's literature as a basis, adding 60 cases to those he has collected. I have verified the greater number of the references, and have omitted doubtful cases and those which have been quoted twice or thrice over. *January 6th*, 1891.

---

9. *Secondary melanotic sarcoma of the bladder.*

By J. H. Targett.

History.—From a labourer, aged 32, who was admitted into Guy's Hospital, under Mr. France, in 1859. His illness began with pains in the left eye two and a half years before admission. The eye gradually protruded, and a year before admission small nodules appeared on the body.

When admitted the patient was very ill. His left eye was displaced outwards by a large black tumour, which filled the orbit and protruded upon the cheek. There were numerous melanotic nodules scattered over the surface of the body and the limbs. He was much wasted, and suffered from great pain in the chest and difficulty of breathing. Death occurred three months after admission.

At the autopsy the lungs and liver were found to be extensively affected with secondary deposits of pigmented growth, and the base of the skull and the dura mater were invaded by the tumour in the left orbit.

Description of specimen.—On opening the bladder a soft pigmented polypus was found attached to the mucous membrane by a slender peduncle. It was situated on the posterior wall about an inch from the orifice of the left ureter. It was about the size of a filbert, and its smooth surface was marked with patches of brown pigmentation, giving it a stippled appearance. The pedicle was composed merely of mucous membrane, and was about one third of an inch in length. Histologically, the tumour was composed of small round and oval sarcomatous cells with granules of

Digitized by Google

pigment scattered among them. The pigment was of a light-brown colour, and was arranged in clumps outside the cells. The tumour was thickly permeated with capillary vessels.

This specimen, which has been in Guy's Hospital Museum since 1859, is of interest on account of its extreme rarity, and supplements the cases recorded by the author in the last volume of these 'Transactions' (vol. xli, p. 180). *April 21st*, 1891.

---

10. *The soft parts and pelvis of a male adult who had extroversion of the bladder.*

By Edgar Willett.

The deformity known as extroversion of the bladder is not uncommon, but it seems probable that few cases reach adult life, as judged by the scarcity of specimens like those shown, *i. e.* the soft parts and pelvis of an adult who had the abnormality mentioned. The history of the patient is that when about 21 years of age he was admitted in the Hatfield Workhouse Infirmary, that he lived there over forty years, and died there in March of this year, and it is owing to the kindness of Dr. Lovell Drage that the specimens were obtained.

A pelvis at the Royal College of Surgeons of a woman, aged 39, similarly afflicted, shows five inches of separation; it is a slight pelvis, but retains the ligament between the pubic bones; it was not possible to retain the ligament in this case without sacrificing the soft parts.

In the 'Path. Soc. Trans.' for 1862 (vol. xiii, p. 163), Mr. Canton described and showed a somewhat similar specimen from a man who died in Charing Cross Hospital, aged 24. It had many similar characters, such as double hernia, strong bony prominences, and unusually well-developed muscles of the rectum and anus, judging from the drawing, but there was much less separation, not more than about two inches.

The abnormality is much commoner in males than females.

The pelvis.—The interval between the pubic bones measures 5½ inches. The sacrum is made up of six or seven vertebræ, and has

Digitized by Google

special characters; the lateral masses of the first, second and third segments are curved backwards from the bodies instead of arching forwards; the extreme width is slightly increased, $4\frac{3}{4}$ as against $4\frac{1}{2}$; the coccyx is only partially ossified to the last bone of the sacrum; the junction of the sacrum with the two iliac bones seems to have been ligamentous only, and there probably was considerable movement at this situation, *i. e.* there was a true sacro-iliac joint.

The ossa innominata also have special characters; it should be noticed first that all the bony prominences are very much exaggerated; thus, the iliac crests, the spines, crests and angles of the pubes, the eminentiæ and lineæ ilio-pectineæ and the spines of the ischia are all unduly prominent. The grooves for the gluteal, obturator, and internal pudic arteries are deep and well marked.

The iliac fossa on the right side is very deep, suggesting unusual pressure from the cæcum. Around the margin of the left acetabulum are numerous spicula of bone.[1] When looked at from the front, nothing can be seen of the interior of the acetabula, whereas in a normal pelvis these cavities are clearly exposed.

From behind, it is seen that the posterior superior spines of the ilia are much closer together than usual (they are $1\frac{3}{4}$ inches apart as against 3 inches), and that the sacral spines, instead of projecting from between the back part of the iliac crests, lie deeply in the groove formed between these eminences.

The soft parts consist of the mucous membrane of the bladder, the penis, scrotum, anus and surrounding skin. On the anterior aspect and near the centre of the specimen is a prominent mass consisting of the hypertrophied mucous membrane of the bladder; it is roughly oval in shape, and measures 3 inches in its transverse and 2 inches in its vertical diameter; at the lower part of this mass, and rather to the right of the middle line, are the openings of the ureters. Below this is a short and stumpy penis, in a condition of complete epispadias; the mucous membrane of the glans is normal, but the skin of the rest of the penis is thickened, and the papillæ are hypertrophied from the constant irritation of the decomposing urine; the skin immediately below the penis is in a similar condition, as is also that of the flattened and divided scrotum, but to a less extent.

The scrotum is ill-defined and consists of two oval eminences, each of which contains a well-formed testis, but these, as can be

[1] He suffered much from muscular rheumatism.

Digitized by Google

seen from behind, are widely separated; there is an inguinal hernia on each side, the sac on the right side descending only into the upper or funicular portion of the tunica vaginalis, that on the left descending into the cavity of the tunica vaginalis itself.

The following structures are seen from behind:

(1) The edge of the great omentum adherent to the anterior abdominal wall at the point where the peritoneum is reflected backwards; (2) the two kidneys and ureters, which are normal; below the termination of the latter is an eminence which is the misplaced prostate; on it the vasa deferentia terminate, and below and to the outer side of these are the vesiculæ seminales The last two or three inches of the rectum, which was large and capacious, and shows great hypertrophy of the special muscles, viz. the external sphincter and the levator ani. The patient had control over the sphincter ani. *November 4th*, 1890.

---

11. *Vesical calculi.* (*Card specimen.*)

By Raymond Johnson.

The specimen consists of nine complete calculi and three fragments. They were removed *post mortem* from the bladder of a man, aged 79 years, under the care of Mr. Barker in University College Hospital. He died of carcinoma of the prostate, and had used a catheter regularly for eighteen months. The end of the gum elastic catheter was ragged and frayed.

The calculi are acicular, and the longest measures seven eighths of an inch. They consist of phosphates deposited on threads from the catheter, the thread in many cases projecting from the end of the calculus. *May 5th*, 1891.

Digitized by Google

12. *Myxo-sarcoma of prostate and bladder.* (*Card specimen.*)

By W. D. Spanton (per J. H. Targett).

The patient was a boy, aged 5 years, who was brought up to a hospital for a swelling of the lymphatic glands in the groin. The prepuce was long and adherent to the corona glandis. There had been difficulty in micturition for more than a month; he would often stoop forwards, resting his hands on his knees, and bear down forcibly in passing his water. There was no blood in the urine at any period of his illness. Under an anæsthetic a catheter could not be passed beyond the membranous portion of the urethra. *Per rectum* a solid elastic mass was felt in the position of the bladder, and, after the urine had been removed by supra-pubic aspiration, a tumour the size of a man's fist was discovered on bimanual examination behind the os pubis, which proved to be an enlargement of the prostate. The tumour steadily increased in size, and in its progress gradually spread towards the umbilicus, so that ultimately it occupied more than half the interval between the umbilicus and pubes. It also caused bulging of the perinæum.

The boy died thirteen weeks after the difficulty in micturition was first observed. A fortnight before death he had epileptiform convulsions lasting two days, and during the last few weeks of life he had no control over the rectum.

Autopsy.—The pelvic viscera were removed with the tumour *en masse*, and on dissection it was found that there was a hard, white gristly mass, about the size of a hen's egg, occupying the position of the prostate gland. This was surrounded by a soft gelatinous substance, which was especially abundant towards the rectum. The prostatic urethra seemed to have been destroyed by the new growth, and not even the finest instrument could be passed *per urethram*. For this reason the bladder had been drained above the pubes. There was no cystitis. Kidneys normal.

In its present condition the specimen shows a rounded tumour attached to the anterior wall of the bladder close to its neck. This tumour measures 2¾ inches from side to side, 2¼ from before backwards, and 1½ in thickness. It is of a soft gelatinous nature, and

Digitized by Google

is not encapsuled. On opening the bladder posteriorly a ring of large polypi is seen surrounding the internal meatus of the urethra. These polypi have a broad attachment to the vesical mucous membrane, and their free extremities are angular in outline from mutual pressure. Histologically they are composed of small round and oval cells situated in the submucous tissue, and covered with the normal mucous membrane. They are permeated by numerous large vessels. Sections taken from the prostatic tumour have the appearance of myxo-sarcoma. *December 16th*, 1890.

---

13. *Prostatitis and periprostatic abscess; cystic dilatation of prostatic glands; numerous prostatic calculi.* (*Card specimen.*)

By Sheridan Delépine.

The specimen is composed of the lower part of the *bladder*, with the lower end of the *ureters;* the greater part of the *prostate*, and the corresponding portion of *urethra;* part of the *vasa deferentia* and *vesiculæ seminales*. (Bladder opened from the back by incision passing through the middle of the trigone and veru-montanum. The lower part of the right lobe of the prostate has been removed in order to expose the cysts and calculi).

The most important lesions are:—1. *An abscess* occupying the space between: the bladder and rectum—the vasa deferentia and vesiculæ seminales—the so-called middle lobe of the prostate and the connective-tissue below the recto-vesical pouch.

2. *A number of small cysts*, which are the result of the dilatation of prostatic glands, and many of which contain—

3. *Small calculi.*—These are black in colour, rough, nearly spherical, measuring from under 1 mm. to 3 or 4 mm. in diameter. They are so abundant that it is impossible to make a clean section through the organ. They are chiefly composed of phosphate of calcium, carbonate of calcium, possibly some oxalate of calcium, colloid, and so-called amyloid matter. The prostatic cysts communicated freely with the abscess cavity on the one hand, and with

Digitized by Google

the urethra on the other hand. The urethra was found full of pus after death.

Lesions found in other organs.—Old phimosis. Chronic interstitial nephritis with recent interstitial inflammation superadded. Endocarditis affecting chiefly the tricuspid valve, &c.

For history see description of the heart (p. 59).

October 21*st*, 1890.

---

14. *Cystic chondro-adenoma of testis.* (*Card specimen.*)

By H. Betham Robinson.

This tumour was removed from a man, aged 37, on March 4th, 1890, by Mr. Mackellar, and to him I am indebted for reporting this case to the Society.

His attention was first drawn to the swelling eleven weeks before admission, but up to this date there was no pain or increase in size, only a sense of dragging. There had been no injury.

The right testis was somewhat globular, smooth on the surface in front, but behind rather nodular. It felt hard generally, but scattered through it were a few elastic spots; it was heavy. Over the front and upper part there was testicular sensation, and here, what seemed to be testicle substance, could be indistinctly made out; behind there was no testicular sense. There was no hydrocele nor enlargement of cord; the skin was not adherent; there were no enlarged glands. The left testis was normal.

The tumour, on section, proved to be a cystic chondro-adenoma. It was almost circular, with a diameter of about three inches, and encapsuled. The testis was spread out over the upper and front part of this growth, and the epididymis was behind it. The tumour was cystic, the cysts varying in size and being filled with a brownish mucoid fluid; there were no intra-cystic growths. In the connective tissue between the cysts were patches of almost translucent cartilage.

Histologically, the cysts are lined by a single layer of cubical epithelium. The connective tissue is a loose fibrous one, containing in it the islets of hyaline cartilage as before mentioned; myxoma-

Digitized by Google

tous change had taken place here and there, and there was some extravasated blood.

From its appearance there seemed no doubt about the non-malignancy of the growth. From its position it had apparently started from the neighbourhood of the rete testis.

January 6th, 1891.

---

15. *Cystic dilatation of the vasa deferentia.* (*Card specimen.*)

By J. H. Targett.

The specimen was taken from an adult dissecting-room body, of which no history could be obtained. The condition of the remaining genito-urinary organs is not known.

While dissecting the back of the bladder, an oval swelling was discovered in the course of each vas deferens. That on the *left* side was 3 inches from the tip of the corresponding vesicula seminalis, while the *right* swelling was exactly opposite the tip of its vesicula. These swellings proved to be cystic dilatations of the vasa deferentia; they were oval in shape, the left measured three quarters of an inch in its long diameter, and the right was a little smaller. They were filled with material like inspissated pus, which consisted microscopically of fatty granules. No spermatozoa, or other characteristic elements, were found. The vas beyond the cyst, towards the bladder, was shrivelled and its lumen obliterated, and a bristle could not be passed from the testicular end of the vas into the cyst.

Microscopical examination of the cyst-wall, after embedding in celloidin, showed that it was composed of layers of muscular tissue like those in the normal vas deferens. It was lined with granular material resembling the contents of the cyst described above. There was no evidence of any tuberculous lesions.

Remarks.—The specimen is exhibited on account of its rarity, as no similar preparations have been described before the Society. Soft, putty-like concretions, composed of spermatozoa, have been found in the ejaculatory ducts (Reliquet, 'Gaz. Hôp.,' 1873), and it

Digitized by Google

is probable that the cysts in this case were due to obstruction and local dilatation of the ducts, and that the testicular secretion which they contained had undergone degenerative changes.

November 18*th*, 1890.

---

16. *Primary carcioma of the right Fallopian tube with large cyst in connection with the new growth.* (*Card specimen.*)

By W. Essex Wynter, M.D.

The pelvic organs from a female, aged 50, showing a mass of carcinoma about the size of a bantam's egg in connection with the fimbriated extremity of the right Fallopian tube, which is dilated. The interior of the mass communicates with a cyst the size of an ostrich egg, exhibiting dendriform projections on its inner surface, and containing (in the recent state) a slightly opalescent thin yellow fluid.

The uterus and ovaries are free, with the exception of slight adhesions of the thin portion of the cyst to the anterior aspect of the fundus, which is retroflexed. The substance and lining membrane of the uterus appear free from disease with the exception of a polypus the size of a pea within the os internum.

The cyst was found ruptured at the *post-mortem*, and most of the contained fluid had escaped, but there were no signs of recent inflammation. *December* 2*nd*, 1890.

---

17. *Blood-cast of the uterus in a case of anæmia.* (*Card specimen.*)

By Sheridan Delépine.

The specimen is composed of a firm clot which occupied the cavity of the uterus and that of the cervix uteri. This clot forms a perfect cast of these cavities, and has a remarkable shape,

Digitized by Google

being composed of two distinct parts; one corresponding to the body of the uterus, thus triangular in shape, and of little bulk; the other corresponding to the cavity of the cervix, thick, irregularly oval, and of great bulk (considering the part it comes from).

FIG. 13.

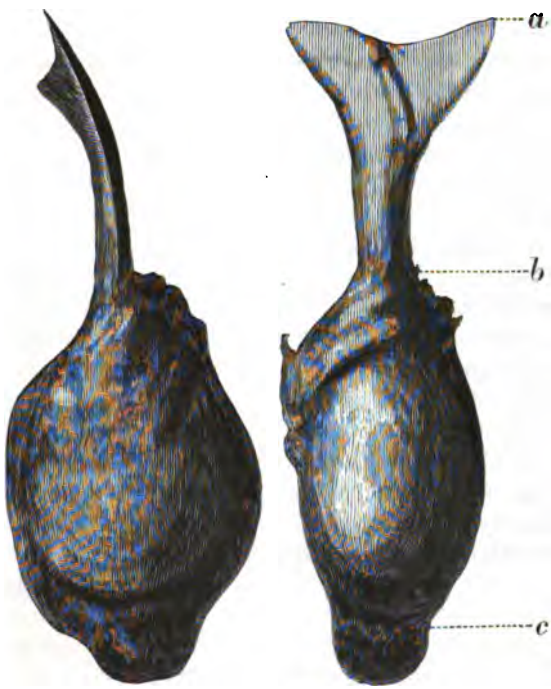

FIG. 13.—Uterine blood-cast, ¼. A. Side view. B. Front view. (From drawings by the author.) *a*. Angle corresponding to the opening of the left Fallopian tube. *b*. Os internum. *c*. Os externum; the clot projects slightly through this opening (*os tinca*).

The body of the uterus was in this case much smaller than the cervical part of the organ. After the clot had been removed the cavity of the body measured 1½ inches from the os internum to the opening of either Fallopian tube, the cervical canal measured 1½

Digitized by Google

inches from os internum to os externum. The same measurements apply to the corresponding parts of the clot, which in addition projected slightly beyond the external os.

Post-mortem examination.—Most of the lesions usually found in *cases of pernicious anæmia* were found in this case—general anæmia, subcutaneous hæmorrhages, advanced fatty degeneration of the heart, pigmentation of the liver, retinal hæmorrhages, &c.

History.—A lady's-maid, aged 44. The mother, a brother, and a sister had died of consumption. The father was still alive. She began when 23 to show distinct signs of ill-health, and was even supposed to be consumptive. *One year before* death she began to suffer from menorrhagia. *One month* before the fatal issue the uterine hæmorrhage suddenly ceased, and bleeding from the nose and gums began. On admission to St. George's Hospital, she was found suffering from anæmia, dyspnœa, anorexia, rapid and weak pulse, retinal hæmorrhages. The red blood-corpuscles were diminished in number and pale. The case was diagnosed as one of *pernicious anæmia.*

Remarks.—The case shows an interesting instance of *vicarious hæmorrhage,* probably *concomitant with obstruction of the uterine cavity.* It also shows how the *cervical canal may become distended* with accumulated fluid, even when the cavity of the body shows hardly any sign of dilatation. The proportions of the organ are otherwise those of a virgin uterus.

November 4th, 1890.

---

18. *Case of supernumerary median nipple and areola in a male.*

By W. Roger Williams.

The patient, who is the subject of this communication, was exhibited at the last meeting of the Society.

He was a tall man, aged 67, who presented the following remarkable combination of pathological conditions:

Digitized by Google

1. In the median line of the front of his body, over the lower part of the sternum, a little above the sterno-xiphoid articulation, and 2 inches below the level of the normal nipples, was a well-marked supernumerary nipple and areola the size of a shilling. This nipple, which was the size and shape of a pea, was of a brownish colour and devoid of hairs. It was surrounded by a well-marked, pinkish, tuberculated areola, from which grew numerous long hairs. No associated glandular substance could be detected.

2. At a point four inches below the left nipple, and rather internal to it, was a small rudimentary, supernumerary nipple, devoid of areola, but presenting in its situation a zone of hairs, mostly short, but a few quite long. No gland could be felt in connection with this rudiment.

3. His normal pectoral pair of nipples and breasts were of great size; quite as large as they often are in middle-aged women (*gynæcomasty*).

4. From his lower lip he has recently had recurrent epithelioma excised, as well as enlarged glands from the submaxillary region.

The patient was under the care of Dr. Purcell at the Brompton Cancer Hospital, and I am indebted to him for allowing me to publish the case.

Remarks.—Median supernumerary mammary structures are of very rare occurrence in human beings. I know of only three other cases.

Gosse[1] refers to a Wallachian *vivandière*, the mother of two children, who died shortly after the birth of her second child, from the effects of exposure and privation. On examining her body after death, Gosse was surprised to find a well-developed pair of supernumerary milk-giving mammæ, situated below and internal to the normal ones; and between these a rudimentary median one, five inches above the umbilicus.

Max Bartels[2] alludes to an instance of similar malformation in a man.

In the other case,[3] an exceedingly beautiful lady, the mother of five well-formed children, had a small rudimentary median mamma, rather below the level of the normal glands.

[1] 'Dict. des Sci. Méd.' (1819), t. xxxiv, p. 529.

[2] Reichert and Du Bois Raymond's 'Arch. f. Anat., &c.,' 1872, p. 306.

[3] Percy's "Mém. sur les femmes multimammæ, &c.," 'Journ. de Méd. de Corvisart,' An. xiii, t. ix, p. 381.

Digitized by Google

In each of these cases the supernumerary median mammary structure was rudimentary, and occupied the same position as in my case, viz. over the lower part of the sternum.

Median mammæ are very rare in the animal world, but instances occur in the Virginian opossum (*Didelphys Virginiana*), and in some other marsupials.

According to Darwin,[1] nipples were first acquired by marsupials after they had diverged from and risen above the monotremes, and were by them transmitted to the placental mammals.

I regard the occasional appearance of supernumerary median mammæ in human beings as due to reversion to this ancient ancestral arrangement.

For, as I have shown elsewhere,[2] redundant mammary structures do not arise just anywhere, but only in certain definite situations, which correspond with those occupied normally by the glands of polymastic animals.

There is no evidence whatever that such structures can arise as mere "sports" from ordinary sebaceous follicles.

March 17*th*, 1891.

---

19. *Cystic disease of breast in young women.*

By H. Betham Robinson, M.S.

The two following cases are instances of chronic interstitial disease with cysts in young women:

Case 1.—E. L. P—, a healthy-looking girl, aged 20, single, was admitted into St. Thomas's Hospital in July, 1890. Her mother had died of consumption. About two years before, she noticed a lump in the left breast on the inner side; this had gradually increased in size. It had always been hard and slightly painful, but not tender, her attention having been first drawn to it by the pain. There were no other lumps. There had never been any discharge from the nipple.

The tumour was above and to the inner side of the nipple,

[1] 'Descent of Man' (1879), p. 162.

[2] 'Journal of Anatomy, vol. xxv (1891), p. 225.

Digitized by Google

beneath the areola; it was hard and nodulated, fairly freely moveable, and intimately attached to the breast tissue. The skin was not adherent, nor was the nipple retracted. There were no enlarged glands. The right breast was healthy.

On removal the growth proved to be part of the breast tissue, and there was no sign of any capsule. In the centre it was composed of an aggregation of small tense cysts, not larger than a pea, containing a dirty-brownish fluid. The area of this mass of cysts was about the size of a half-crown. The connective tissue was tough and fibrous, and evidently altered by chronic inflammation. At the margin of this mass the cysts were not nearly so close together, and they seemed to be arranged somewhat in lines radiating from the nipple to the periphery.

Case 2.—A. F—, aged 19, admitted July 15th, 1890. She was unmarried and had always enjoyed good health. One sister said to have died of consumption. No catamenial irregularity.

Eleven months before admission she noticed a small lump in the upper part of the left breast about the size of a filbert. This was from time to time attended with shooting pain. The breast was strapped, but the swelling did not resolve.

On admission, there was a firm, nodulated lump situated just above the nipple, and about the size of a half-crown; it could not be differentiated from the surrounding breast tissue. The skin was free over it, and it moved freely on the deep tissues; it was connected with the nipple. The latter was not retracted, and there had been no discharge. The tumour was rather tender on handling. No enlarged axillary glands. Right breast healthy.

On July 31st the affected portion of breast was excised. On section the deeper part was seen to be much more fibrous than normal, and cupped slightly; there was no capsule. Scattered through this indurated tissue were small cysts containing a lightish-brown fluid. The deep surface of the tissue removed seemed a little puckered. The rest of the breast tissue was healthy.

As the microscopical appearances in the two cases were identical, they may be considered together. It is to be seen that the connective tissue is a dense fibrous one, and that it is especially sclerosed in close relation with the epithelial elements; in some places, however, there is a very extensive round-celled infiltration. Embedded in this fibrous tissue are a number of cysts of varying size. The smaller cysts have a lining of cubical or columnæ epithe-

Digitized by Google

lium with well-marked nuclei, which in places is quite regular and in a single layer, and in other places the epithelium is seen to be proliferating, and cells are more spheroidal. In the larger cysts the epithelium, whether in one or several layers, is markedly flattened, assuming the pavement form. In some of the cysts the epithelium projects into the interior, and is arranged on a connective-tissue basis; the latter, in some cases, is a true intra-cystic growth, while in others it appears due to solution of continuity between adjacent cysts. In many of the cysts there is a coagulated material which apparently has relation with cell destruction. These cysts, from the nature of their lining membrane, seem to owe their origin to dilated ducts. As well as the cysts, smaller spaces are to be seen, in most cases choked with epithelium. The lining epithelium of these consists of several layers of small spheroidal cells, arranged fairly regularly; but the epithelium inside consists of large swollen cells, many of them with ill-defined nuclei, but with a very granular cell-protoplasm. These cells arise from the cells lining the spaces, and resemble exactly those met with in a functionally active breast. These spaces appear to be acini, which seems almost proved from the close approximation of many of them to the dilated ducts.

Remarks.—We are all very familiar with the fact that corresponding changes to those detailed take place in the breast over 40, during the period of involution, but for such a condition to be met with in young unmarried women under 20 is very unusual, and seems worthy of consideration. The chronic interstitial change which has, probably from pressure, caused some obstruction to ducts and their subsequent dilatation, has induced in these cases an abnormal activity of the acinous epithelium, so much so that we might imagine we were examining an active gland. In this respect these cases differ somewhat from the disease in adults, for these, although we have plenty of cystic development and proliferation of their lining epithelium, I have not met with such activity in the epithelium of the acini. The cause of the connective-tissue change at so early an age is difficult to make not. In neither case was there any menstrual irregularity nor injury, nor, as far as I could ascertain, had there been any abnormal irritation of the gland.

March 3rd, 1891.

Digitized by Google

20. *Duct carcinoma simulating scirrhus.*

By H. Betham Robinson.

[With Fig. 1, Plate IV.)

A. S—, aged 51, was admitted into St. Thomas's Hospital in November, 1889, under Mr. Sydney Jones, and to him I am indebted for bringing this case before the Society.

She was an unmarried woman and, although she had not generally enjoyed good health, she had not been troubled in any way with her breast.

Five years before admission she had a fall and knocked the breast, but she did not notice any tumour till sometime after. There was no family history of cancer.

External to the nipple, and in the lower quadrant of the left breast, was a hard tumour, which was divided into two portions by a groove; the upper harder part had been noticed for sixteen months, and the lower softer part for twelve months. The growth had increased steadily. The whole tumour was free on the deep tissues and dragged upon the nipple when moved. The nipple was not retracted, nor had there been any discharge from it at any time. The skin was slightly adherent to the hard upper part, so that it puckered a little on moving the growth beneath it. The upper part was fairly well defined, but intimately connected with the breast, somewhat circular, hard, and about the size of a hen's egg; the lower part consisted of a cyst about the same size as the other part, and the tissue around it and between it and the upper part was rather nodular, such as would be met with in insterstitial mastitis.

There was some loss of flesh, but only slight pain at intervals. There was no enlargement of axillary glands.

On section, after removal, the lower soft part proved to be a smooth-walled cyst, containing a greenish-brown fluid, which was embedded in chronically inflamed breast-tissue, white in colour, but non-resistant to touch. At some distance above this, and imbedded in the same material, was the lump before mentioned, also whitish in colour, but very hard, and cupping slightly on section; it did not

Digitized by Google

show any signs of fatty change. This hard lump had the skin in close contact with it above, but it was not involved in the growth; below, it came very near the pectoral muscle, so much so that it had puckered the submammary connective tissue; in it were a few small cysts, about the size of a pea, containing a greenish fluid, but with no papillary growths.

Microscopically, it is to be seen that the breast is cystic, and that the latter condition is in relation with chronic interstitial changes. The cysts are very variable in size; in the larger ones, the lining epithelium consists of about two rows of cells, which are much flattened, the flattening being proportional apparently to the size of the cysts, and no doubt in relation with intra-cystic tension. In some, however, there is marked proliferation of the epithelium, the cells, which in relation with the basement membrane are cubical, becoming more and more spheroidal and swollen, and appear to be melting down into the secretion in the cysts. As well as this cystic condition, there is a great deal of solid growth, which is a columnar epithelioma, resembling exactly a similar growth taken from the rectum, as it is arranged chiefly in a tubular form, the tubes being cut in different planes. In some places this epithelium is arranged regularly in a single row on the basement membrane, but in others there are solid masses of cells, the majority of which are spheroidal, but, on careful examination, prove to be cubical at the periphery. The connective tissue generally shows very little round-celled infiltration, what there is being limited to a few patches.

Remarks.—This case is of great value from two points of view, the clinical and pathological. Considering the former, so far in all the cases of duct cancer that have been recorded, I do not think there has been one that could be mistaken before microscopical examination for scirrhus. In nearly all the cases some unusual features have been noted before removal, so that the surgeon has been warned as to the nature of the tumour being out of the ordinary. This case clinically appeared to be a typical circumscribed scirrhus, being very hard, and the skin adherent to it, and the diagnosis seemed confirmed, from its presenting on section the unripe pear appearance and from the cupping. In the light of what we now know as to its nature, we might have been struck with the fact that if it had been a scirrhus in such close proximity to the nipple, it was rather unusual that the nipple was not retracted,

Digitized by Google

Digitized by Google

DESCRIPTION OF PLATE IV.

Fig. 1 illustrating Mr. Robinson's paper on Duct Carcinoma of the Breast simulating Scirrhus. (Page 229.)

From a drawing by the author (Zeiss A. oc. 1).

The section shows a congeries of cystic passages, irregular in size and shape, and lined with cylindrical or cubical epithelium.

Fig. 2 illustrating Mr. Robinson's paper on a Recurrent Carcinoma of the Face arising in the Sebaceous Glands. (Page 315.)

From a drawing by the author (Zeiss D. oc. 2).

Epithelial masses are seen embedded in a connective-tissue matrix, which is crowded with small round-cells. The epithelial-cells are cubical at the margin, but in the centre of the alveoli they are large and swollen, the general structure resembling that of a sebaceous gland. There are no cell-nests in any part of the tumour.

Digitized by Google

1

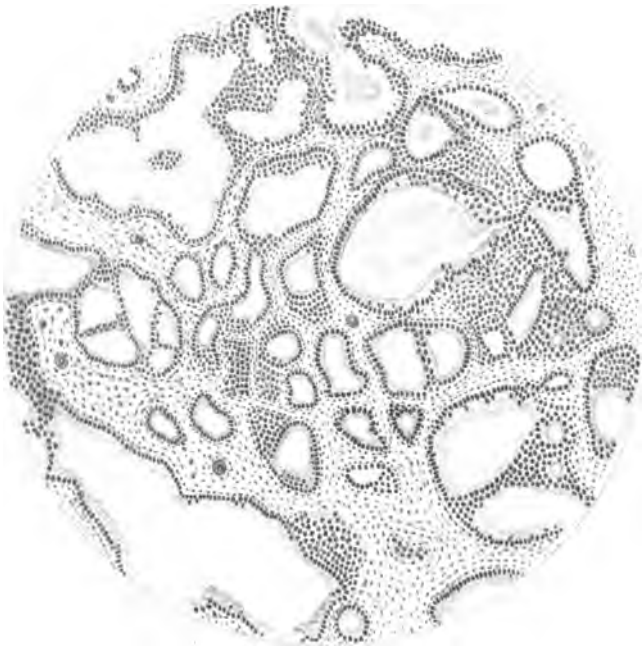

2

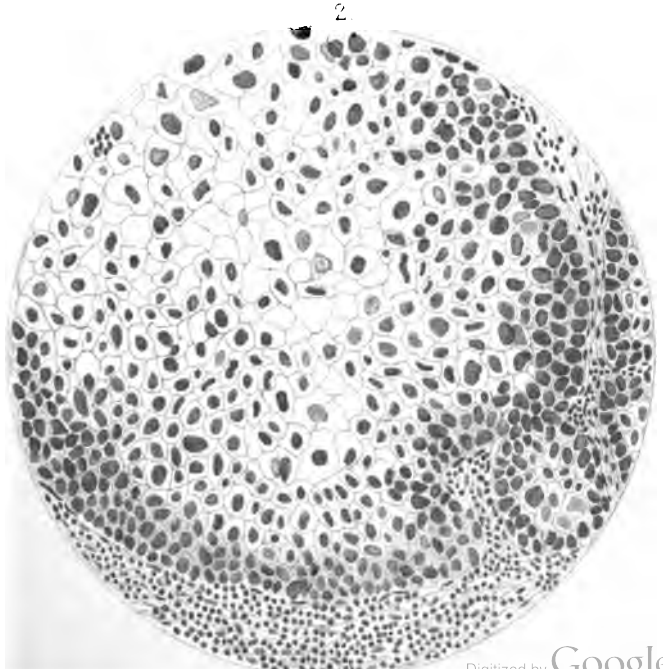

Digitized by Google

Digitized by Google

and, from the length of time the growth had been present, that the axillary glands had not been involved. Discharge from the nipple, if it had been present, might have given us the clue as to its nature.

Pathologically, we see that there is extensive cystic disease with a proliferating cubical epithelium, and a tendency for the latter to form intra-cystic growths. Although difficult to prove, I do not think it irrational to deduce from the nature of chronic inflammatory change, that this is the forerunner of the new growth. Accepting this origin, it behoves us to view less lightly this chronic inflammation with cysts, especially after the age of forty. Probably in a small proportion of cases such grave alterations ensue; but we must remember that they do do so, and avail ourselves of the earliest opportunity to extirpate the disease. The malignancy of this form of cancer appears to be rather low, so that early removal may mean permanent cure.

Duct cancer, which arises from the epithelium of tubes from the nipple to the intima, seems thus to have two clinical forms: the first, where the growth begins in the larger ducts as a papilloma or carcinoma, or as the former preceding the latter where the growth is soft and is attended by bloody discharge from nipple; and a second form which differs considerably from it, and which is very difficult to diagnose from that beginning in the acinous epithelium, and may not be able to be diagnosed until the microscope steps in and shows us we have columnar instead of spheroidal cells.

This patient was seen by me a few days before the meeting, and there is no sign of any recurrence. *March 3rd*, 1891.

Digitized by Google

VI. DISEASES, ETC., OF THE ORGANS OF MOTION.

1. *Fracture of first rib.* (*Card specimen.*)

By H. D. Rolleston, M.B.

The right first rib was fractured near its articulation with the spine. The fracture started just in front of and to the inner side of articulation with the body of the first dorsal vertebra, and travelled obliquely forwards to a point just in front of the tuberosity on the outer border of the rib. The rib was thus divided into two parts—(*a*) the head and tuberosity left in connection with the spine, and (*b*) the rest of the rib and costal cartilage in connection with the sternum.

From a soldier, aged 28, who was run over by a road car at Hyde Park Corner, and died ten minutes after with extensive surgical emphysema. The first four ribs on the right side, and the second to ninth ribs inclusive on the left side, were fractured; neither of the clavicles were fractured. The spine was fractured, without displacement, between sixth and seventh dorsal vertebræ. The right bronchus was completely ruptured just below the bifurcation of the trachea. The left lung was wounded by the fractured ribs. *February 17th*, 1891.

---

2. *Fracture of both first ribs.* (*Card specimen.*)

By H. D. Rolleston, M.B.

Both first ribs were separated anteriorly from their costal cartilages, which show commencing calcification. Both first ribs are fractured posteriorly.

Digitized by Google

The right first rib presents an oblique fracture which, passing obliquely through the neck, divides the rib into the head and tuberosity which are in contact with the spine and the rest of the rib.

The left rib is fractured through the neck just internal to the tuberosity.

From a man, aged 45, who was injured by a lift. On the right side all his ribs, except the twelfth, were fractured; on the left side his scapula was extensively fractured, and first to ninth ribs broken. His spine and sternum were uninjured. The spleen and left kidney were ruptured. *May 5th*, 1891.

---

3. *Fractures of the first rib.* (*Card specimen.*)

By H. D. Rolleston, M.B.

There is a complete fracture through the neck of the right first rib, running in an antero-posterior direction. The edges of the two fragments are serrated. There is no attempt at union; there is no callus. The two fragments are kept in contact by the periosteum, which was intact.

There is in addition a partially united fracture, which separates the tuberosity from the rest of the rib. This fracture arises from the first mentioned complete fracture, and runs directly outwards. The first rib is thus divided into (1) the head and part of the neck in contact with the spine; (2) the tuberosity; (3) the shaft.

From a man, aged 28, who was run over, and sustained a facture of his right clavicle and of all the ribs on the right side of his chest, except the twelfth. He died twenty days after the injury with an empyema. *May 5th*, 1891.

Digitized by Google

4. *Extensive necrosis of the vertex (with drawing of the skull). (Card specimen.)*

By H. D. Rolleston, M.B., for Dr. Dewsnap.

The skull-cap presents a large heart-shaped space, which measures 3 inches in an antero-posterior direction, 3½ inches from side to side, and has a circumference of 11½ inches.

This large hole has its edges bevelled at the expense of outer table, so that there is a rim of carious bone surrounding it. The measurements of the whole affected area are, antero-posteriorly 5 inches, from side to side 4½ inches, and in circumference 15½ inches.

This specimen was presented to the museum of St. George's Hospital by Dr. W. F. Dewsnap, who furnished the following history. A man, aged 40 years, in an attack of acute mania, butted his head forcibly against some iron railings. He was admitted at once to Colney Hatch Asylum. The scalp sloughed, as it was impossible to keep the dressings properly in position. The skull-cap underneath necrosed, and at a period of four months from the injury the dura mater sloughed, and an extensive hernia cerebri appeared, which lasted for the remaining three weeks of life. Death was preceded by right-sided convulsions and right hemiplegia. *Post mortem* there was a thick layer of blood-clot (⅛ inch) over the surface of left hemisphere. *May 5th*, 1891.

---

5. *Femora three years after osteotomy.*

By James Berry, M.B., B.S.

These femora were taken from a boy, aged 7 years, who died in the Royal Free Hospital on September 21st, 1889, of cerebral meningitis. On September 26th, 1886, three years before death, MacEwen's osteotomy had been performed on both sides for

Digitized by Google

genu valgum by Mr. Howard Marsh at St. Bartholomew's Hospital. The bones were divided with a chisel in the usual situation, and the operation was perfectly successful. The chief interest of the specimens lies in the very perfect repair which has taken place since the operation. Externally the bones show no trace whatever of the osteotomy, and it is impossible to detect, from examination of their external surfaces, the exact places at which they had been cut. A longitudinal section of the left femur has been made, and this discloses a faint but distinct trace of the line of section. At this spot there is a sudden transition in the interior of the bone from cancellous tissue below to much more compact bone above. This is undoubtedly the place at which the osteotomy was performed.

Another point of interest is the present high position of the scar in the bone. The osteotomy was performed just above the condyles; the line of section is now, however, seen to be at the junction of the lower with the middle third of the bone. The whole femur measures 10½ inches in length, the line of section is now 3¼ inches above the lower end. The explanation of this lies, no doubt, in the rapid growth of the lower end of the bone during the three years which intervened between the dates of the operation and of the boy's death. *December 16th*, 1890.

---

6. *Two specimens of extreme thickening of the calvaria in infants.*

By Samuel G. Shattock.

The first of these specimens was taken from an infant who died of bronchitis and whooping-cough when eighteen months of age. The mother was in good health; the father died in an apoplectic fit. The child was one of seven months' twins, the other twin being healthy, as were also two elder sisters. Only the two central and the right lateral incisors had been cut.

After death the viscera, with the exception of the lungs, were found healthy; the ends of the ribs were enlarged, and presented

Digitized by Google

the changes characteristic of rickets. (Case of E. White, admitted under Dr. Stone, June 5th, 1888.)

The calvaria is throughout extremely thickened. The several bones are formed, for the greater part of their thickness, by soft,[1] closely cancellous, osseous tissue.

The deeper part of the divided surfaces, shows a different construction. Here the bone is of more open texture, and its component trabeculæ thicker and hard; traces of parallel concentric lamination are very obvious in certain situations, and the inner surface is bounded throughout by a thin layer of compact bone. This laminated deeper part represents what remains of the original and once normal tissue of the bones. The thickening is greatest about the frontal eminences, and here reaches 1·8 cm. There is, moreover, a well-pronounced median elevation about the glabella: this I have seen also during life in a child which presented the typical signs of rickets. The edges of the bones are their thinnest parts, and these shelve in a noteworthy manner from the inner aspect, and scarcely at all from the outer, though along the inter-parietal suture this is reversed. This would indicate that the new bone is added mainly to the exterior; it may be compared, say, with the section of an oyster-shell, although there, of course, the growth is from within.

The inter-parietal suture is everywhere traceable on both inner and outer aspect; the fronto-parietal is largely obliterated, bridged across on the inner; in the divided edge the structure of these bones is continuous in the outer or more superficial parts.

The second specimen was also obtained from an infant eighteen months of age, admitted into St. Thomas's Hospital under Sir William MacCormac May 3rd, 1890, on account of fracture of the femur caused by a fall from a chair; death ensued the next day.

This child had been under Dr. Cory's treatment as an out-patient since April 12th, 1890, for congenital syphilis, the signs of which were unequivocal.

After death there were found beading of the ribs, very marked on the inner aspect, and showing on section irregular advance of ossification, and moderate swellings at the lower ends of the radius, ulna, and tibia.

Spleen large, very firm; other viscera normal. The several

[1] It is only in the recent state, or in specimens preserved in spirit, that the softness can be appreciated.

Digitized by Google

bones of the calvaria are throughout much thickened. The extreme thickness at the frontal eminences is 2 cm.; at the parietal eminences it is about the same; lower down the parietals average ·6 cm. in thickness, and they are less thick posteriorly than towards the front and mid-line. The apex of the occipital squama is ·5 cm. The anterior fontanelle measures from before back and from side to side 3 cm. The edges of the bones are their thinnest parts. This is especially marked along the inter-parietal suture; but this thinning obtains only on the outer aspect, so that the sutures are depressed below the general level; on the inner there is nowhere any shelving of the different bones. The outer portion of the calvaria is remarkably soft; it is resilient as sponge, and can be quite easily cut with a knife. Where the periosteum is stripped off, the exterior is finely reticular, or marked by the fine meandering furrows of vessels. An inner table is present, and to this succeeds firm diploe, which merges more outwardly into the thick investing layer of resilient sponge-like tissue described.

Remarks.—Here are two skulls, precisely alike in their pathological anatomy, whether macroscopic or microscopic, from infants of the same age. One is from a case of simple rickets, the other from a case of congenital syphilis.

British pathologists have never adopted Parrot's generalisation that all examples of thickening of the calvaria in infants are syphilitic ('Path. Soc. Trans.' vol. xxx, 1879)—"Les ostéophytes craniens sont propres à la syphilis héréditaire." That he did not limit the term osteophyte to a circumscribed formation only is shown by a preceding sentence—"Les ostéophytes craniens, s'étendent peu à peu de leur point d'origine aux parties voisines, . . . les bosses frontales et pariétales sont les derniers régions envahies, mais il peut se faire que finalement elles le soient; alors la calotte du crâne tout entière, est couverte par l'ostéophyte."

As those who have studied this subject know, there are many instances of such thickening recorded as a simple rachitic change, apart altogether from congenital syphilis.

But to the various specimens of rickets from the lower animals, shown at different times by Mr. Sutton,[1] we may point, as demonstrating beyond dispute, that rickets itself is fully capable of producing this condition.

[1] 'Path. Soc. Trans.,' vols. xxxiv, v, viii.

Digitized by Google

And we may do this, as showing that all thickenings of the calvaria in the young are not syphilitic, with the same confidence the we may point to the osteoplastic periostitis in full grown animals,[1] as proving that, whatever the causes of "idiopathic" periostitis are in the human subject, they are not all syphilitic.

It is noteworthy that the morbid production of bone is in both specimens confined to the exterior, whilst the inner table and inner parts of the diploë, though rarefied, are of normal hardness.

To take next the second case, that in which there is a distinct history of congenital syphilis.

Dr. Barlow has described and figured ('Path. Soc. Trans.,' vol. xxx, 1879, p. 333) the calvaria of a syphilitic infant, showing very similar though less extensive changes.

That rickets without syphilis may produce thickening of the calvaria is beyond dispute;[2] and the converse is equally true.

Without there being the changes characterising rickets at the epiphysial lines of the long bones, the skull may present in marked degree the new formations of bone on the exterior. This was so in the first and second cases reported by Dr. Barlow (loc. cit.). But, as Parrot[3] states, these formations do not differ in hardness from normal bone. They are the products of inflammation, but the new tissue otherwise presents nothing special in its characters.

What is the essential nature of the lesion which in rickets brings about this thickening of the calvaria or of other flat bones? If we adopt as the gross definition of inflammation an increased production of imperfect structures (Paget), these changes in the skull in rickets must, and I think rightly, be considered inflammatory; and so of the similar periosteal thickening which, in highly pronounced cases of rickets, affects the scapulæ, the hip-bones, or shafts of the long bones. Indeed, if such a skull as that shown be placed by the side of one from a case of osteitis deformans,

[1] Mus. Coll. Surg., 1136 and others.

[2] The conclusions of Parrot in regard to the antiquity of syphilis, based on the presence of cranial osteophytes in ancient skulls, are open to criticism.

[3] Under the osseous lesions of congenital syphilis, Parrot ('Path. Soc. Tr.,' vol. xxx) describes the periosteal new formations under the terms osteoid and rachitic, the latter being marked by the softness of the new bone, and associated with the epiphysial changes usually taken to characterise rickets. It is to be noted, however, that although Parrot uses the expression rachitic form of osteophyte, he does not recognise rickets as a disease, but simply as a syphilitic affection.

Digitized by Google

there is no less reason for naming the lesion in the rachitic skull inflammatory than that in the other. One difference there is, and only one, viz. this remarkable absence or deficiency of calcification of the new bone in the rachitic. Clinically, both enlargements are unattended with pain. So much might be legitimately held on the broad evidence of morbid anatomy; and in its histology the rachitic skull shows the unequivocal microscopic signs of inflammation.

I examined both of these calvariæ microscopically, by means of thin sections cut on a microtome, and without previous artificial decalcification; the material was hardened in Müller's fluid, and subsequently in alcohol.

Such preparations are not only more instructive than those prepared in the usual way, but they are absolutely essential for the proper observation of the morbid histology, since it is only thus that the calcified can be distinguished from the uncalcified parts.

It is well known to practical histologists that the matrix of bone when devoid of earthy salts stains readily with carmine solutions, whereas osseous tissue in which the salts are normally present does not.

In each calvaria the most striking abnormality is the unusual colouration of the trabeculæ. The peripheral portions of all the trabeculæ stain of a deep red; many of those at the outer growing surface are so stained throughout, showing as complete an absence of earthy salts as bone that has been artificially decalcified.

The appearances are in this like those of osteomalacia, save that in osteomalacia bone previously calcified is decalcified and unmade, whilst in rickets it is imperfectly calcified in the making.

In the uncalcified substance may be seen the normal lamellar disposition, and in normal numbers branching lacunae with their contained corpuscles,—all the structure of bone is present, but without the earthy salts. The sections from the syphilitic specimen include the entire thickness of the calvaria, and such show in every part these same appearances; the sections of the rachitic skull do not include the innermost portions, but they are precisely similar. In both, where ossification is in rapid progress at the surface, the production of the almost homogeneous matrix, the inclusion of the osteoblasts, and the formation of lacunæ, are all most easily to be traced, but in the matrix no deposition of earthy salts. For the description of the contents of the cancellous spaces I may select the

Digitized by Google

rachitic specimen, since it is upon the nature of this that the chief interest rests.

The elements are best differentiated by the hæmatoxylene stain. Except at the growing surface, and for a short way below it, the central portion of the tissue which occupies the spaces is of the lymphoid kind, such as naturally fills the cranial diploë; in the

FIG. 14.

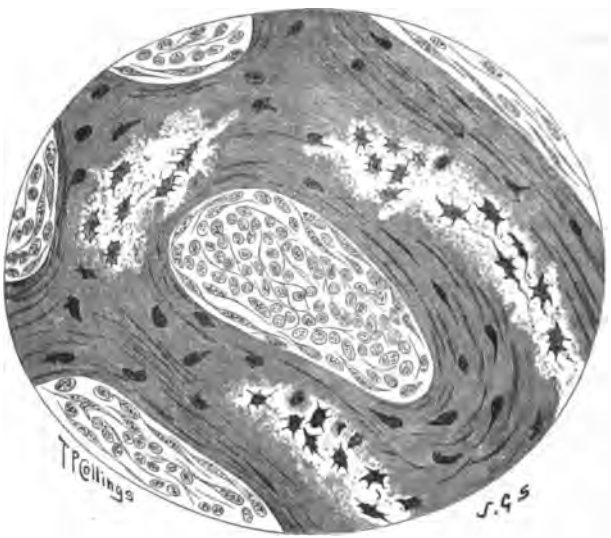

Section of the second calvaria, described in the text [syphilo-rachitis]. The section was cut without any artificial decalcification, and stained with ammonia-carmine solution. The shaded portions of the trabeculæ were stained of a bright red, and are devoid of earthy salts, contrasting with the unstained central areas, which pass by a granular margin into the uncalcified matrix beyond. The tissue in the cancellous spaces is of the lymphoid kind proper to the cranial diploë. (From a drawing by the author.)

spaces at the surface it is a richly-celled connective tissue, and similar tissue lines the spaces where these are filled with marrow. The round-cells of the marrow are so closely packed that such deeper parts are not so well adapted for observation as those about the surface where no medulla has yet developed; still, in such parts red blood-discs lie free in the stroma, with collections of orange granular pigment. In the superficial spaces, however, red corpuscles

Digitized by Google

are fairly abundantly strewn in the connective tissue from which ossification is proceeding.

Immediately around some of the capillaries are deeply-stained leucocytes, similar to those within them; and similarly deeply-stained leucocytes occur amid the connective tissue.

Histologically, then, the cardinal sign of inflammation is present, viz. diapedesis of blood-corpuscles, pale and red; and both from this and the grosser morbid anatomy the thickening must be regarded as inflammatory.

The calvaria from the other, the syphilitic, case shows similar changes.

This view of the inflammatory character of the lesion is borne out by the microscopic examination of the similar ensheathing formations of uncalcified spongy bone around the shafts of the long bones in highly pronounced cases of rickets. There may be in sheaths of such osseous tissue, 2 mm. in thickness, a complete absence of earthy salts, and yet all the structure of bone. If such sections be compared with those of the new tissue produced in osteoplastic periostitis of a long bone, made after artificial decalcification, it is difficult to tell the one from the other. In both the ensheathing layer may present the same architecture of finely cancellated bone filled with vascular connective tissue; and the evidence of diapedesis is plain in the presence of deeply-stained leucocytes, which contrast in size, depth of colouration, and absence of apparent granularity, with the nuclei of the connective-tissue corpuscles, and of which some present the bizarre figures so commonly seen in such wandering cells. Such ensheathing formations in rickets are met with altogether apart from the repair of fractures, and apart from any trace of curvature, and they cannot be regarded here any more than on the calvaria as of a reparative nature. There is as utter a want of reason for such a view as for so regarding the thickening of the skull and long bones in osteitis deformans.

I may point, again, to the rarefaction of the original substance of the shaft of the rachitic bone beneath the encasing periosteal formation, as like that which obtains in osteoplastic periostitis in the adult, when associated with inflammation of the original substance of the compact wall of the shaft, and to the similar rarefaction traceable in the rachitic calvaria beneath the layer of new bone on its exterior. In the divided surface of the rachitic

Digitized by Google

calvaria described, the stages by which the disappearance of the outer table is brought about are readily traced; even where the table is destroyed the rarefied tissue of the original bone is recognisable by its different grain and coarser texture.

Nor is there anything in the etiology of rickets that is discordant with such a view. There are many instances in pathology, of inflammation (apart from that of microbial origin) due to a morbid alteration of the blood, such as the cause of rickets is commonly held to be; *e.g.* the inflammation of the joints and pericardium, &c., in rheumatism; of the pericardium and pleura in Bright's disease; and of various parts in gout.

This, then, I submit, is the result of rickets as it affects the bones—inflammation; and the distinguishing mark of the anatomical product is the imperfect calcification of the new-formed osseous tissue.

And if such changes are inflammatory, it follows that both rickets and syphilis are capable of producing osteoplastic periostitis; and, so far as the distribution of the new bone goes, there is no certain means of distinction between the two.

In the skull-cap the new formations of syphilis are usually circumscribed, limited to particular areas; but this holds also in some of the cases of simple rickets.

The criterion, I think, we must take is the consistence of the new bone.

In rickets this is imperfectly calcified.

And where this remarkable want of calcification obtains in the osseous formations produced in a syphilitic subject, we are dealing with the two diseases combined. The syphilitic disease may, to a certain extent, determine the seat of inflammation; but it is the rachitic that is answerable for the imperfect calcification of the new bone, and the compound addition might be expressed by the compound term, syphilo-rachitis. 1891.

Digitized by Google

7. *Symmetrical periostitis of femur, with an unusual formation of new bone.*

By Anthony A. Bowlby.

Robert R—, aged 1 year, was admitted into the Metropolitan Hospital, under the care of Dr. Tooth, on November 18th, 1890. The history given was that for a few days before admission the legs and thighs had been swollen and the child had seemed ill; the patient had never been strong and healthy.

Dr. Tooth found evidence of general bronchitis, and requested me to examine the limbs. This I did on November 25th.

The child was in a good deal of pain and was restless. Its temperature was a little over 100°, and it looked very ill. There was no evidence of rickets, and the chest, head, and upper extremities were well formed. The legs were swollen from slight œdema, but the tibiæ and fibulæ were normal. The lower part of each thigh was greatly swollen, the right being considerably the larger of the two; there was no effusion into the knee-joints. The lower end of the right thigh presented an even, oval swelling, with red, stretched skin covering it, extending rather beyond the middle of the femur and fading gradually into healthy tissue. At its upper part the swelling was easily felt to be hard and bone-like, and was evidently in connection with the femur, whilst around the condyles fluctuation could be detected.

On the left side the swelling was much firmer, and more evidently due to a general enlargement of the whole femur involving the lower half of the bone. It was smooth, very hard, and its edges were ill-defined. It presented no fluctuation.

Both limbs were placed in splints, and an incision was made into the swelling on the right side by the house-surgeon, Mr. Parker. With a probe passed through the cut bare bone could be felt for a distance of two inches, and several ounces of thick healthy pus were evacuated.

From this time the thighs gave but little trouble, the swelling

Digitized by Google

and pain on the left side subsided, and from the incision on the right side there was only a slight discharge. The lung trouble, however, increased and was complicated by laryngitis; the child dying on December 11th, 1890.

The *post-mortem* examination showed inflammation of the larynx, with bronchitis and pneumonic consolidation of the base of the

FIG. 15.

Transverse section of the right femur, showing a ring of thick new bone separated from the original shaft by a considerable space.

left lung. The femora were removed, and showed the following conditions:

Right femur.—The lower half of the bone was enormously enlarged, the enlargement extending from the articular surface to above the middle of the shaft. The greatest circumference measured five and a half inches, whilst the circumference of the healthy shaft above measured one and seven eighths of an inch.

Digitized by Google

The upper edge of the swelling was rather abrupt, but nevertheless rounded and smooth.

On sawing the bone transversely just above the greatest diameter of the swelling, it was found that the original shaft of the femur formed but a very small part of the enlargement. The appearance of the section might well be compared to the side view of a wheel, for in the centre—representing the axle and hub—lay the section of the shaft of the femur, measuring a quarter of an inch in diameter, and around the circumference—representing the tyre—was a circle of bone and periosteum, measuring rather more than one eighth of an inch in thickness. The greatest distance from the centre of the old shaft of the femur to the inner edge of the new ring of bone, was five eighths of an inch, and across this space there lay several irregular fibrous bridges, which might be compared to the spokes of the wheel. In the space thus formed was some pus, and a hole in the outer ring of bone marked the place where the incision had been made seventeen days before death.

The shaft of the femur was not bare, but was covered by a thin layer of soft fibrinous material, and the bridges joining it to the outer ring of bone was similarly covered. The attachment of the diaphysis to the lower epiphysis was loosened, but there was no definite separation.

The left femur, before being sawn, measured four inches in circumference where it was thickest, and here it was more than twice as large as the normal shaft higher up. The enlargement was confined to the lower half of the bone, and its upper margin was shelving and rounded. On section it was found that, as in the other femur, the shaft of the original bone lay enclosed in a bony case, which was separated by a space from it. The intervening space was not so great as on the opposite side, and measured only a quarter of an inch across. The new shell of bone also measured a quarter of an inch in thickness, and the space was occupied by soft fibrous tissue and lymph, but contained no pus or blood.

The formation of new bone after periostitis is, of course, a common occurrence; but in the case under notice the bone formation was of an unusual nature. It seems certain that the periosteum must have been entirely separated from the whole circumference of the lower half of the shaft of one femur, and to a less extent from that of the other. It is further evident that the periosteum so raised, must have maintained its vitality, and commenced to form new

Digitized by Google

bone directly after its separation, and it is interesting to note with what extraordinary rapidity this bone was formed. The whole duration of the illness was not more than four or five weeks, and seventeen days before death an incision passed through the periosteum and evacuated pus, showing that at this date there was no considerable formation of bone. The proof of this is to be found in the specimen itself, which shows an aperture in the bony outer case corresponding with the incision and the sinus in the skin.

I should suppose that the inflammation was not very acute at its onset, and that the thick periosteum of an infant's femur was more easily separated from the bone and raised, than softened and perforated. Further, it is evident that before the pus was evacuated the periosteum must have already commenced to form bone, for had it not done so it would have collapsed when the fluid was withdrawn. It is only by assuming that it possessed some rigidity that we can explain the formation of the new bone at so great a distance from the original shaft. *March 17th*, 1891.

---

8. *Osteitis deformans in a single bone.*

By H. H. Clutton.

The specimen shows a vertical section of an adult tibia, which, with the exception of the two articular extremities, is enlarged from one end to the other. There is more new bone on the anterior surface than on the posterior, producing an apparent although slight curve, but not a real one. The medullary canal is almost completely filled up with new bone, which is as dense as the wall of the shaft.

Here and there a few pits and spaces may be seen, which in the recent state were filled with granulation tissue.

The specimen was removed by amputation in September, 1889, from a woman, aged 35, who had been in my out-patient room at St. Thomas's Hospital for ten years. She had an old angular curvature of spine for which no treatment was required, and the leg, for which she sought advice, had only recently been giving her trouble. The tibia was at that time only slightly enlarged, but

Digitized by Google

slowly increased during these ten years to its present dimensions No other bone was affected, and there was no history of syphilis, nor any other cause which could throw light on its origin. There was some suspicion that the skull might have become larger, but it was only an impression, which could not be verified by *post-mortem* examination. A brother of the patient was also an inmate of the hospital in 1889 with a chronic disease of the left humerus; but the father, who was frequently seen at this time, gave no evidence either in himself or in the history of his family of ever having had syphilis.

She suffered a great deal of pain, especially at night. Iodide of potassium and mercury were given over long periods and in full doses, but without any real or permanent benefit.

She only finally submitted to amputation on account of the constant pain, which made her life a burden.

Some small superficial ulcers formed in the summer of 1889, which induced her to be admitted into the hospital. The ulcers then quickly healed with rest in bed, but the pain in the tibia was seen to be sufficiently severe to keep her awake nearly the whole night.

The amputation was performed in September, 1889, through the knee-joint by Gritte's method, the patella being pegged to the femur. She lost all her pain, and the stump was healed in a fortnight. She left the hospital in October perfectly well, and very pleased that she had at last submitted to amputation.

In November at home she had a fit, followed by left hemiplegia. She rallied for a time, but died on December 13th. No *post-mortem* was obtained.

The interest in this case rests upon the doubt, which may be reasonably entertained, as to the class or subdivision of bone diseases under which it should be placed. For myself I am inclined to look upon it as an unusual case of osteitis deformans.

1. There was a complete absence of a syphilitic history, and no lesions or traces of lesion, which could be attributed to syphilis, were at any time discovered.

2. The uniform enlargement of the tibia from one end to the other, with the exception of its articular extremities, the almost complete obliteration of the medullary canal, and its density are conditions as much in favour of this disease in its advanced stage as of syphilis.

Digitized by Google

The objections which may be raised are—1. The age of the patient, which must have been 25 when the disease first commenced. But it has yet to be proved that the disease is confined to old age, and in one of Sir James Paget's cases ('Med.-Chir. Trans.,' vol. lxv, p. 234) the bones first showed evidence of the disease at the age of 28. 2. Only one bone can be proved to be affected, although there was a suspicion that the skull was increasing in size. Mr. Bowlby was the first, I think, to record a case in this Society's 'Transactions,' in 1883, of *one* bone—the femur—being affected with this disease. And we are all familiar with single bones in our museums which look exactly like cases of osteitis deformans, but the history is not forthcoming to confirm our impressions. In the 'Path. Soc. Trans.' for 1888, I recorded an instance in which the disease was unsymmetrical, the left humerus and right radius being the part involved, whilst the patient showed other evidence of osteitis deformans. This case I used as an argument in favour of accepting some single bones as rare instances of osteitis deformans, for the patient had, in addition to the unsymmetrical enlargement, the general characters of the disease. 3. An objection might be raised to the absence of any curvature in the bone. But the patient scarcely ever put her foot to the ground, except when she came to the hospital. She had a pension from the Royal Hospital for Incurables, and did nothing but needlework. She had a marked angular curvature of spine, which forced her, in the first instance, to assume this sedentary life, long before the enlargement of the tibia became apparent. And one bone only being affected, she naturally stood on the sound one, and scarcely ever leant heavily on the leg that was so painful.

I think it is generally believed that the curvature in osteitis deformans occurs during the earliest stage of the disease, when rarefaction has not yet been replaced by condensing osteitis, for it is one of the first signs noticed. If this be so, probably the weight of the body in progression is the explanation of the curvature, and this cause of curvature was, I think, absent in my case.

April 21*st*, 1891.

Digitized by Google

9. *Osteitis deformans.*

By Joseph Griffiths.

While in Paris, during the past summer, I found an incomplete skeleton showing the changes characteristic of osteitis deformans in the upper extremities. This is now in the Cambridge Museum.

The bones found were the clavicles, scapulæ, humeri, radii, and ulnæ, femora, tibiæ, and fibulæ; the foot and hand, together with the skull, vertebral column, ribs, and pelvic bones were missing. The chief interest of this specimen lies in the fact that, contrary to what is usual, the disease manifested itself in an advanced stage in the bones of the upper extremities only, those of the lower extremity being but slightly affected.

The clavicles are thick, heavy, and large, with their normal curves much exaggerated, and more marked on the left than the right side, as is the rule in the remaining bones of the upper extremities; the *scapulæ* are also thick and massive, with their spines, processes, and inferior borders especially thickened, the plate or body being strongly curved backwards in the left, and therefore deeply concave on its costal surface, in order presumably to fit on the very curved upper part of the back, a feature so marked in the attitude of these patients; the *humeri* are similarly thickened with uneven surfaces, and their shafts are bent outwards and forwards near the middle; the extremities being unaltered in form, with the exception of small osteophytic growths near the articular margin, resembling those seen in arthritis deformans; but the articular surfaces are covered with dense bone which is in places eburnated. The shafts are not only bent as above described, namely, outwards and forwards near the middle; but they are twisted on their long axis to such a degree that, if the plane of the upper end be considered fixed, that of the lower, which would naturally and normally correspond, is turned outwards through an angle of 45° on the left side, less on the right. The ulnæ remain in their size and shape unaltered, except for the presence of osteophytic growths near the upper end, and of some roughnesses on the surfaces of the shafts in their upper halves, due to some chronic periosteal inflam-

Digitized by Google

mation. The radii are elongated and much thickened, especially in the upper halves of their shafts, and greatly bent outwards and slightly forwards as if to accommodate themselves for their increase in length, the ends being fixed to the ulnæ, which are not profoundly altered. These, like the humerii, are twisted on their long axis, but the lower end is twisted in the opposite direction, namely, inwards, the left through an angle of 75°. This could in part be accounted for by the twisting outwards of the humerus, but not wholly, as the measurement clearly shows.

The lower extremities, as has been already mentioned, are but slightly affected, and it may be doubted by some whether the change in them is an early manifestation of the disease.

The femora are thickened in the lower halves of their shafts from new bone formed on the exterior, as if due to chronic periostitis; the surface of the bones are in that situation rough and uneven, and the lines for the attachment of muscles are somewhat more pronounced than natural. The tibiæ and likewise the fibulæ are similarly affected, and here, as in the femora, the change is marked only in the lower halves of the shafts. A longitudinal section of the right humerus shows the thickening of the shaft to involve not only the dense compact tissue, but also, to a less degree, the outer part of the cancellous interior thus encroaching upon the medullary cavity, and also a great thickening and condensation of the cancellous structure to the depth of about one third of an inch immediately under the articular surface. In these particulars, as well as the external form and shape, the bones agree with the description of this affection as given by Sir James Paget. The only case in which the bones of the upper extremities were affected, as in the one now described, is to be found amongst the cases in Sir James' original paper (Case 5). In this the bones were not so markedly affected in the upper as the lower extremities. The change was most marked in the humerii, and in the left more than the right, as in the present instance, but no mention is made of the bones of the forearm being similarly affected.

It would seem from the study of these bones I have described that the disease begins in the form of osteal and periosteal inflammation, affecting at first certain portions of the shafts, from which further extension takes place to involve gradually the entire shaft. Another interesting point to note is the twisting of the humerii and radii on their long axis. This twisting I have, how-

Digitized by Google

ever, noticed in another specimen in the Cambridge Museum, in which the femur is typically affected and twisted to a slighter degree.

1890.

---

10. *Acromegaly.*

By H. D. Rolleston, M.B., for A. A. Kanthack, M.B.

The present case was first shown before the Berlin Medical Society by Prof. Virchow, January 16th, 1889, who subsequently published a lengthy paper on the same, which appeared in the 'Berlin Klinishe Wochenschrift,' January, 1889. This paper was translated by me for the 'Illustrated Medical News,' 1889.

This man, Westphalen by name, a Westphalian by birth, is a most typical example of acromegaly. He presents excessive hypertrophy of the extremities, of the "membres supérieurs, inférieur, and cephaliques." From childhood he was big and strong, but he cannot give a date to which he could attach the appearance of these changes. There is no loss of sexual function in his history. Such loss has been observed in many men suffering from acromegaly. Westphalen is married and has six children. None of the children suffer from acromegaly. This man has always been fairly strong, he can carry 8 cwt. comfortably on his back. His muscular development is good, showing a certain correspondence to the growth of the osseous parts.

His hands are enormous, and present the typical "paw-like" appearance: circumference of thumb, first phalanx = 4 inches; circumference of middle finger, first phalanx = $4\frac{7}{10}$ inches.

His feet are also enormously hypertrophied: circumference of hallux = $5\frac{1}{3}$ inches. The length of his body is only 5·8 times that of his foot, instead of being six times the length of his foot. The enormous size of his hands and feet is due, as may at once be seen, to a disproportionate development of the soft tissues (skin, subcutaneous tissues, and muscles), though the bones also are concerned in this.

Digitized by Google

Westphalen's head also is characteristic: its periphery being $26\frac{1}{2}$ inches (the average measurement being less than 20 inches). Length of head = $9\frac{1}{5}$ inches (average being less than 8 inches). Breadth of head = $6\frac{7}{10}$ inches (average being less than 6 inches). His head is otherwise quite proportionately developed.

The *lower jaw* is not "excessively large," as has often been asserted to be the case in acromegaly. His head is simply "justo major." The soft parts of the head are not developed in the same proportion as they are in the extremities, but his lips, nose, and some of the lower portions of his face are considerably enlarged.

The other day I examined his urine, following a recent suggestion, and found a large quantity of sugar (sp. gr. = 1030); but the urine was dark in colour and he has no sign or symptoms of diabetes.

Westphalen tells me that Prof. Schultz, of Bonne, found sugar in his urine some months ago. *October* 21*st*, 1890.

---

11. *Calvaria showing irregular absorption of bone from a case of congenital syphilis.*

By J. F. Payne, M.D.

This specimen came from the body of a male infant, Frank W—, admitted under my care into St. Thomas's Hospital, September 29th, 1890, when 9 weeks old, suffering from bronchitis. There was also extreme and persistent snuffles and muco-purulent inflammation of the conjunctivæ. The ends of the long bones were somewhat enlarged, the ribs showed slight beading; *the cranial bones appeared natural.* The child was tolerably well nourished, but febrile, the temperature on the second day rising to 102°, and the daily maxima ranging from 101° to 104° during the illness.

It was the first-born child, and the family history showed nothing remarkable. The mother was alive and well; the father had died of diphtheria four months before.

Digitized by Google

The illness had begun with dyspnœa and fever; there had been no fits or other significant symptoms. Judging that the child was suffering from congenital syphilis, I prescribed small doses of mercury as well as an expectorant mixture. The results were at first favourable, as the snuffles diminished and the general condition improved; but after a fortnight diarrhœa came on, the child lost flesh rapidly, and became very ill, so that the mercury was omitted. A few days afterwards an ulcer appeared on each cornea.

While these unfavourable symptoms were going on a remarkable change was noticed in the bones of the skull. The frontal and, to a less extent, the other cranial bones, which had been quite smooth, began to feel irregular to the touch, and gradually became excavated into irregular shallow depressions, separated by ridges. There was no redness of the scalp or sign of inflammation, and no other part of the skull appeared specially soft or compressible. During this time the temperature, which had been lower, rose again, showing daily maxima of 103°, 104°, and 105°. The child died with diarrhœa and increased signs of bronchitis on October 24th, 1890.

The *post-mortem* examination made by Dr. Gulliver showed no visceral disease except broncho-pneumonia, the brain and membranes being natural.

The bones of the vault of the cranium presented, however, very remarkable changes. The skin and periosteum were normal in appearance, but both frontal bones looked as if eaten away by irregular ulcers, the bone having been absorbed and its place occupied by membrane only. The absorption was chiefly of the outer table, but affected the inner also to some extent. The edges and intervening portions of bone were not notably thickened, but perhaps slightly so, and very irregular or jagged at the edges. Similar changes, less extensive, were seen in the parietal bones, especially the left.

The general appearance of these bones was that of something worm-eaten or gnawed out, but the absence of any inflammation or injury of the periosteum made it impossible to call the change caries or ordinary necrosis. When the calvaria was prepared for a museum specimen, the changes were found to be somewhat more extensive than at first appeared, but no new feature was revealed.

Remarks.—I feel constrained to regard this morbid condition as a manifestation of congenital syphilis, though the other symptoms

Digitized by Google

were not very well marked. I have not before met with the precise type of syphilitic disease here seen; but it is evident that if, by more gradual absorption the edges of the erosions were worn away, this condition might pass by an insensible transition to the more ordinary form of craniotabes, as seen in congenital syphilis. It was a remarkable fact that the morbid process should have been observed to come on while the patient was under antisyphilitic treatment. This would appear to show that the changes in bones come on at a definite and rather late period in the evolution of the disease, and that mercurial treatment was in this case unable to arrest, even if it did not accelerate them.

It is remarkable that this form of bone disease, and even the ordinary craniotabes, seem unknown in the syphilis of adults; the well-known syphilitic caries being a very different disease. This fact would seem to show that the morbid changes are due to a special action of the syphilitic virus on the process of ossification. In the same manner may be explained the production of lesions of the long bones and the ribs, as in this case, very similar to those of rickets. It is, I think, impossible to deny that such lesions do occur in congenital syphilis as well as in rickets, whether it be due to a combination of two diseases or to the process of ossification being unfavourably affected by both. We need not, however, on that account confuse together, as I think M. Parrot did, all the lesions produced by these two diseases, and refer them to syphilis alone. *May* 19*th*, 1891.

---

12. *Gummatous disease of occipital lobe due to inherited syphilis; perforation of skull.*

By J. Hutchinson, Jun.

The most remarkable features of this case were the very extensive destruction of cerebral cortex—nearly the whole of one occipital lobe being involved in gummatous deposit—and the presence during life of a protrusion through the skull of the intra-cranial membranes and fluid. A pathological feature of no little interest

Digitized by Google

was the fact that the large gumma, which certainly had existed for some five or six years before death, had been unattended by any general meningitis.

The patient was a girl who was for over nine months in the City of London Infirmary, and for the opportunity of examining her during life and of obtaining the specimen subsequently, as well as for full notes of the case, I am indebted to the kindness of Mr. Buncombe, the Medical Superintendent.

A short account only need be given of her family and previous history. Her father was a very intemperate and dissolute man, who was said to have had syphilis. One brother had died at eleven months from "convulsions;" one brother and a sister were alive and said to be healthy. The patient was said to have been a very healthy child until after the age of twelve, when so-called "abscesses" formed in the subcutaneous tissues of the back and neck, for which she attended Great Ormond Street and St. Bartholomew's Hospital. They healed and fresh ones formed from time to time, ultimately they all cicatrised with the formation of supple white scars. Although not absolutely certain, it is more than probable that these were gummatous in nature, the character of the scars being the most marked feature pointing in this direction. It should be mentioned that her ill-health at this period was referred to an accident to the spine sustained some ten months before the first abscess appeared; and that when aged three years she was said to have had convulsions followed by discharge from the ears.

At the age of sixteen a swelling developed on the left side of the head, which was noticed to pulsate, and which steadily increased to the size of a mandarin orange. Whilst this developed the patient lost power in her legs and became practically blind. This was due to neuro-retinitis followed by atrophy of both discs. Whilst in the infirmary her symptoms were chiefly—1, weakness of both legs, practically paraplegia, with incontinence of urine and fæces at times; 2, weakness of left arm; 3, œdema of the left half of the body, varying much from time to time; 4, frequent severe headache, chiefly referred to the vertex. Her mental condition was good, and she answered questions readily and rationally. She was very anæmic, and the urine contained one sixth albumen. She had one convulsive seizure lasting some eight minutes.

The tumour of the head was about the size of a mandarin orange, was situated 2½ inches above and behind the mastoid

Digitized by Google

process, soft and pulsating at times, with a thin covering of skin over it, which showed no signs of inflammation. Pressure on it caused pain, but it could not be wholly reduced.

The kidneys at the *post-mortem* examination were not found to be so extensively diseased as the long-persisting albuminuria had led one to infer. They were rather large, the capsules not adherent, and on section showed evidence of chronic interstitial and tubular nephritis. There was no amyloid degeneration and no gummata or scars in either organ. The liver and spleen were normal.

The scalp was found to be thinned over the protrusion, and the skin was only separated from the sub-arachnoid fluid by fibrous tissue which was adherent to the borders of the aperture in the skull. The latter measured 2 inches by 1½ inches, its borders were slightly thickened, the cavity communicated with the left lateral ventricle. Both ventricles were much dilated. Close to the aperture was a large gummatous, firm mass, involving the greater part of the left occipital lobe, extending down to the tentorium, which was matted to it, and invading the upper part of the corresponding lobe of the cerebellum. There was a good deal of calcareous degeneration just behind the ventricle. Microscopic sections of the gumma showed various stage of fibrous change, caseation, and vessels in all stages of narrowing up to obliteration. Sections were specially examined for tubercle bacilli by my friend, Dr. Galloway, without result. As it was said that the patient had suffered from ear disease the left tympanum was opened, but found to be quite normal. There was no trace of general meningitis, and the central nuclei and rest of the cerebrum appeared quite healthy, though the former were compressed by the distension of the ventricles.

On the outside of the skull, about 1 inch in front of the aperture, was a small patch of roughened bone.

The case is certainly a rare example of extensive perforation of the skull due to absorption of bone without any necrosis or caries, and there seem to have been very few similar cases recorded. In the museum of the London Hospital is part of a skull showing a large aperture in the frontal bone, through which during life a protrusion occurred. There was a history of injury, and it was thought possible that the perforation was due to a tumour. It was found, however, that it was situated immediately over a large gumma of the cortex and meninges. The patient was an adult man under the

Digitized by Google

care of Dr. Jackson. In the case at present reported the diagnosis of inherited syphilis was made, although the eyes and teeth presented no features characteristic of that disease, and the patient was given iodide of potassium for a considerable period.

Other points worthy of note in the case are the very extensive destruction of one occipital lobe without marked impairment of mental power, and the great distension of the ventricles—no doubt due to the presence of the gumma. *March 17th*, 1891.

---

13. *Caries of the scapula.* (*Card specimen.*)

By L. A. Dunn, M.B.

The specimen consists of the entire left scapula, with the exception of the coracoid and acromion processes and the glenoid cavity. The whole of the spine is seen to be rough and carious. The anterior four fifths of the supra-spinous fossa is occupied by a carious excavation, which is continuous with the upper surface of the spine. The same condition exists in the anterior third of the infra-spinous fossa.

In the position of the glenoid cavity is seen an irregular surface, apparently where an epiphysis has been separated; whilst just below this the axillary border is broadened out into a rough expanded cavity, which tracks round to the subscapular fossa, and communicates with a somewhat circular carious cavity occupying the upper and anterior half of this fossa.

History.—The specimen was removed from a boy, W. B—, aged 9 years, who was admitted into the East London Children's Hospital, May 14th, 1889, with impaired movements of the left shoulder-joint, and a chronic abscess pointing at the posterior border of the left axilla. The abscess was opened and drained. The axillary border of the scapula, just below the glenoid cavity, was rough and expanded; subsequently deep fluctuation was detected in the supra- and infra-spinous fossæ, together with crepitus over the acromion process.

An incision was then made along the whole length of the spine of the scapula, letting out a quantity of pus, and exposing a bare

Digitized by Google

rough spine, which had quite separated from the acromion process; further rough bone was felt in both fossæ on the dorsum of the scapula, and a similar condition was found to exist in the venter by passing the finger over the superior border.

A second incision was now made along the vertebral border of the scapula, and the bone, which was rapidly shelled out of what periosteum still remained adherent, came away (having apparently separated at an epiphysial line), leaving the glenoid cavity and the coracoid and acromion processes. These had to be removed some ime afterwards.

The atient made a good but somewhat protracted recovery.

January 20th, 1891.

---

14. *Epiphysitis (so called) in infants.*

By William Henry Battle.

There are here five specimens illustrative of acute disease of the long bones in infants, and instead of reading a detailed account of each I will, with your permission, point out some of the more important features which they present in common.

The four patients from whom they were derived were under twelve months of age. Three of them died from exhaustion, one from pneumonia also.

In each specimen the disease is situated at the articular end of the bone, and in one instance (a femur) both the extremities of the bone are affected.

In all the disease gave rise to suppuration, and in every case with one exception the suppuration extended into the joint of which the affected end of the bone formed part. The exception was in Case 4, where the abscess was found in the soft parts of the thigh, and the joint was healthy.

The evidence of disease differs but little in the specimens presented. It consists of a loss of substance of varying extent situated near the end of the diaphysis of the bone, and this has extended in some cases as far as the nucleus of the epiphysis, but in none is

Digitized by Google

the epiphysis affected to such an extent as to cause one to think the starting-point of the disease was in it, whilst in some (notably in specimen 1) there is such destruction of the end of the diaphysis that it is evident that the disease was mainly active in that part.

The epiphysis is not separated in any of the specimens, but in some the disease has extended almost across the line of junction between epiphysis and diaphysis, and in one the neck of the femur has become sunken and shortened. In others the destruction is limited to an area the size of a pea, whilst in no case is the sharply defined opening through which the products of inflammation escaped of a size corresponding to that of the cavity seen beyond it. This cavity in each instance was found filled with pus, and in most granulations lined the wall to some extent. This was generally seen in the cases where the disease had been of longest duration; and in these there is also recent increase of bone from subperiosteal deposit near.

In only one specimen, No. 3, has there been destruction of the articular cartilage, and in that specimen the nucleus of the epiphysis is exposed to the joint surface; this is, however, probably the result of the action of the pus, which was imperfectly drained from the diseased hip, and bathed the cartilage.

In none of the patients, with the exception of No. 4, in whom the abscess dependent on the bone disease made its way into the thigh, was there evidence of congenital syphilis, and in none could we obtain clear history of injury. It appeared rather as if some incautious movement of a limb by the person in charge of the child first revealed the presence of mischief by the pain to which it gave rise.

In Cases 1, 2, 3, joints were incised and pus evacuated with relief, but at the time of operation it was not always possible to find the diseased spot; it was sometimes only found at the *post-mortem* examination.

I think that these specimens help to support certain conclusions with regard to the disease.

1. That it is essentially an osteomyelitis of the very vascular growing end of the diaphysis, the characters of which are simply modified by the condition of the bones in very young children.

2. Although the disease usually commences in the growing end of the diaphysis, it may affect the epiphysis primarily, but usually extends towards it from the commoner starting-point in the diaphysis, and causes secondary changes, not infrequently ending in

Digitized by Google

the partial or complete destruction of the epiphysis. Recorded cases prove that, as in later life, the whole of the diaphysis may be destroyed.

3. That the disease is not a pyæmic condition, properly speaking; for although the lesions may be multiple, they are confined to the bones in the first instance, and the suppuration in the joints is dependent on the bursting of a local abscess into the joint, and is not the result of a pyæmic infection. The patients usually die from exhaustion, and if there is any internal inflammation, such as a pneumonia, it does not present the characters of inflammation due to pyæmic infarcts. The percentage of recoveries is much higher under appropriate treatment than that obtaining in pyæmia.

4. The disease may give rise to a pyæmia, as osteomyelitis at a later period of life may do.

5. Those bones which are most commonly affected are the femur and humerus; in the former both articular ends, in the latter the upper extremity.

6. The acute arthritis of infants is a condition of joint which may result from several causes, of which osteomyelitis and pyæmia are the most common. Localised osteomyelitis must not be excluded as a possible cause for an arthritis until section of the articular ends of the bones forming the joint has been made, and its absence thus proved; for the opening by means of which pus escapes into the joint is sometimes very minute, and may escape observation.

Case 1.—A boy, aged 7 months, admitted to the East London Hospital for Children, June 21st, 1890.

He was said to have had a fit on the 13th June. The right shoulder was found to be swollen on the 20th, but the arm had been noticed to be stiff for some days before. The left knee was found swollen on the 20th; nothing was noticed before this with regard to the left leg. There was no history of syphilis. The child had had otorrhœa.

On admission, and for some time afterwards, swelling of the shoulder and knee was present with high temperatures, supposed to be caused by a pleuro-pneumonia from which the child was suffering. Suppuration became evident on July 4th, and the joints were incised and drained.

The child died on the 13th of August.

Humerus.—The shoulder-joint contained some pus. About one

Digitized by Google

third of the head of the humerus, posterior aspect, had been destroyed and hollowed out into a large irregular cavity, which extends a short distance into the diaphysis, the loss of substance covering an area the size of a filbert. The cartilaginous surface left shows little change. There appears to be some of the epiphysial centre for the head remaining.

The left femur, which measures five inches in length, presents at the junction of the cartilaginous articular surface of the external condyle with the anterior surface of the shaft a depression, which is closed with soft connective tissue. On the outer side, about 1¼ inches from the lower border of the external condyle, there is a distinct sinus, large enough to admit two probes, leading into a cavity situated chiefly in the growing tissue between the epiphysis and diaphysis, somewhat irregular, lined with granulation tissue. A probe could be passed across and through the sinus in front, which appeared almost healed. Pus extended for a short distance along the centre of the diaphysis. The lower end of the bone is somewhat thickened from subperiosteal deposit.

Case 2.—A boy, aged 12 months, was admitted on August 1st, 1890, with suppuration in the left knee-joint. He had cried with pain for six weeks. Swelling was first noticed on July 31st; the mother thought it was not there the day before. There was no history of syphilis or of injury.

On August 2nd the joint was incised, washed out, and drained. Although disease of the bone was suspected, it was not possible to find it. On the 12th there was considerable thickening of the lower one third of the femur. He died on the 13th, with a high temperature and symptoms of exhaustion.

Femur.—The incisions were almost healed; there was no pus in the joint; the articular surfaces of the bones were apparently healthy. At the junction of the lower epiphysis with the shaft there is a small opening in the popliteal surface above the external condyle, and a probe can be passed across, and protrudes in front through a sinus, in the middle line and above the articular surface. When the soft parts had been cleaned away the anterior of these showed a sharply defined margin; the posterior was irregularly pitted. Both lead to an irregular cavity at the junction of the shaft and the epiphysial cartilage; this has been formed chiefly at the expense of the diaphysis, the end of which is covered, and the bone replaced to some extent with granulation tissue. This loss of

Digitized by Google

substance has taken place more along the anterior, posterior, and outer surfaces of the diaphysis. There is some recent subperiosteal deposit around the lower end of the shaft.

In the fresh state this cavity contained a certain amount of pus.

During life there were no signs of disease in the left hip, but at the *post-mortem* examination incision showed the presence of much thin pus in the joint, and on removal of the bone a minute opening was seen in the back of the neck of the femur, as distinctly defined as that made by the passage of a pin through cardboard. After removal of the capsule and soft parts there is seen an irregular loss of substance, bridged over in some parts with periosteum only, leading to a cavity which extends down the shaft of the bone, and involves nearly the whole of the neck. This loss of substance has permitted the posterior part of the neck to become shortened, and the head of the bone to sink in over the cavity.

Case 3.—A female, aged 6 months, was brought to the out-patient department of the East London Hospital on the 18th of September, with some thickening about the upper end of the right thigh, which had been noticed for two days. There was no defined tender spot, and the movement of the joint was good. There was no history of recent injury, and none of syphilis in either mother or child; but the latter had suffered from an eruption of the skin when four weeks old. A fortnight later there was a large abscess over the hip, extending into the pelvis, and behind the femur to the outer side of the limb; the movements were too free, and the limb flexed at the hip and everted.

The abscess was opened with antiseptic precautions, but the child died some days later from pneumonia.

At the *post-mortem* examination the upper end of the right femur presents in the posterior aspect of the neck a distinctly defined circular opening the size of a small pea, through which a cavity the size and shape of a large pea is visible. Towards the epiphysis of the head, and again towards the upper end of the diaphysis, the lining of this cavity is rough; elsewhere it is smooth and even. The articular surface of the head shows at the summit the rough exposed epiphysial nucleus, from which all cartilage has been removed, and around this, irregular hollowed-out pits in the remaining cartilage, much of which has been absorbed.

Case 4 was that of a boy, 4 months old, who was under observation from the 4th to the 19th of July, 1890. The family

Digitized by Google

history was good, and the child was said to have had no illness until one month before, when swelling with great pain came on in the left knee. This swelling had been increasing for a fortnight. There was no history of injury.

On admission there was considerable thickening around the shaft of (the lower half) the femur.

At the *post-mortem* examination a fluctuating swelling was found on the outer side of the lower end of the femur, extending for 2½ inches in the upward direction. There were no signs of disease in the viscera. In the middle line of the anterior aspect of the lower end of the bone was an oval opening, the size of a barleycorn, just above the articular surface. From this a short canal led down into the cancellous tissue of the epiphysis, which was little more than a soft pulp. The periosteum was intact, but the opening above described communicated with an abscess cavity under the muscles in the outer side, which occupied some two square inches, and contained about 2 oz. of thick pus. The knee-joint was quite healthy. No other bones appeared to be affected.

May 5th, 1891.

---

15. *Ossifying epulis of lower jaw.* (*Card specimen.*)

By L. A. Dunn, M.B.

The tumour, which is about the size of a small nutmeg, and consists of a central stem of cancellous bone surrounded by a soft fleshy covering, was removed from the lower jaw of a boy aged 13 years. The fleshy covering was proved by the microscope to be myeloid sarcomatous tissue.

History.—During his infancy the patient had a nævus on the right side of the lower jaw, close to the situation of the canine tooth. This was cauterised at two hospitals, and apparently cured, but subsequently a small swelling occurred at the site of the operation, which very gradually attained its present size.

The tumour was attached to the outer aspect of the right alveolar process of the lower jaw, and pushed the lip outwards, and the

Digitized by Google

anterior bicuspid tooth inwards (the right canine tooth was missing, and indeed never was cut). The mucous membrane was slightly ulcerated at one spot. The tumour was easily removed by means of a chisel, and the patient rapidly recovered. *May 5th*, 1891.

---

16. *Central sarcoma of femur.* (*Card specimen.*)

By W. H. Battle.

W. B., aged 28 years, market constable. For three months before admission he had had occasional slight pain in left knee, and for one month there had been slight swelling above the patella. By a fall a week later the knee was rendered painful and more swollen. On the day of admission (January 10th, 1890) he fell again, and the knee was found to be much swollen, especially above patella. With rest and cold the joint swelling subsided, but the swelling above the patella remained, the left thigh measuring (2 inches above patella) 3 inches in circumference more than the right. The swelling steadily increased, and the pain also. Egg-shell crackling was not obtained, but the swelling was felt to be in the femur. He refused operation for three weeks, but at last consented, and on February 26th an incision was made into the swelling, and the bone was found to be the seat of a new growth, both on the surface and in its medullary cavity; amputation was then performed through the lower part of the middle third of the femur. The sawn bone and the flaps appeared perfectly healthy. The stump healed well, and patient was discharged apparently well on the 9th April.

The bone had been fractured just above the condyles; a new growth infiltrated the lower end of the bone, ceasing above the knee-joint; the deeper muscles, especially anteriorly, were affected.

On microscopic examination the growth was found to consist of mixed round and spindle cells.

The points of chief interest in the case are mainly two:

1. The presence of fracture of the femur of uncertain duration, due to a growth of the bone of central origin, and probably dependent on injury.

Digitized by Google

2. The fact that, although, from the nature of growths of this kind in this position, it is considered best to amputate at the hip-joint, amputation of the thigh well above the disease, but in the continuity of the bone, was performed without local recurrence.

The amount of shock which resulted from the amputation of the thigh in this case was so marked, that it was evident that amputation at the hip would have proved fatal from that cause had the operation been further extended.

It seemed better to perform such a removal of the limb in two stages if necessary, but frequent examinations of the stump showed no local recurrence, and none was found when the *post-mortem* examination was made some months later. *May 19th*, 1891.

---

17. *Glandular carcinoma of upper jaw.*

By H. Betham Robinson.

This tumour was removed from a man, aged 55, by Mr. Clutton in September, 1890, and to him I am indebted for bringing this case before the Society.

Two years before he first noticed a little lump on the left superior maxilla just external to the canine fossa; there was from time to time discharge from the left nostril, and then the tumour disappeared. For the last four or five months before admission the swelling remained permanently, and continued to increase in size, and became painful at night. Five weeks before admission he noticed another lump, the size of a horse-bean, at the lower margin of the left orbit; this had increased rapidly, and almost joined the primary tumour. The discharge from the nostril, which had ceased, reappeared during the last four or five days.

There was a small gland below the jaw, which had been present almost the same time as the first swelling.

On admission there was marked fulness over the left superior maxilla, especially below left orbit, where there was a localised, soft, elastic swelling attached to the bone, but the skin free over it. Below this was general swelling over the maxilla, quite hard

Digitized by Google

and resistent. The soft elastic growth extended to the posterior extremity of the alveolar margin. No enlargement of alveolus nor depression of palate; no bulging between cheek and jaw; no prominence of left eye; no obstruction of left nostril, but some obstruction of lachrymal duct. The gland below jaw hard, but freely moveable.

At the operation the growth was found to have arisen within the antrum, and to have absorbed its anterior bony wall; the orbital surface of superior maxilla was involved, and it extended also into the nostril and backwards into the spheno-maxillary fossa. The growth was fairly firm and of a pale grey colour, and it was apparently all removed.

The gland below the jaw was removed a few days later. Microscopically the growth is seen to be epithelial, varying considerably in structure. The epithelium is arranged in alveoli, and of a spheroidal shape; in some of the alveoli the cells are identical in shape throughout, with well-marked nuclei; while in others they are very swollen and irregular in size, with nuclei not so well marked, and many of them vacuolated. There is no evidence of nest formation. The connective tissue shows extensive round-celled infiltration. The gland also showed that it was invaded by typical spheroidal carcinoma.

The type of this tumour, then, is that of a spheroidal carcinoma, a very rare if not previously undescribed tumour in this region. Although suggesting at the operation a columnar-celled growth, there is no trace in any of the sections of a columnar epithelium at the periphery of the cell masses. There can be little doubt that the growth started in the mucous membrane of the antrum, but instead of growing from the surface epithelium it has arisen from the acini of the secreting glands.

Recurrence of this growth has since taken place.

May 19*th*, 1891.

Digitized by Google

18. *Columnar carcinoma of humerus secondary to tumour of upper part of rectum.*

By Bernard Pitts, M.A., M.C.

The patient, a woman aged 32, was under my care in St. Thomas's Hospital in February, 1890, with obstruction of the bowels caused by a large growth in the upper part of the rectum. Her previous history was good; she married at twenty, and her trouble commenced directly after her last confinement, some eighteen months before admission, with abdominal pain, and difficulty in passing her motions. For the last year she had been losing flesh, and suffered from tenesmus and attacks of profuse and offensive diarrhœa.

On examination her abdomen was found to be greatly distended, coils of intestine very distinct, and visible peristalsis.

The lower part of the rectum was dilated, and about 3½ inches up a firm mass could be felt completely encircling the bowel, and with a central opening just admitting the tip of index finger. The mass was hard and irregular, and very fixed in front. The symptoms were so urgent that I performed left lumbar colotomy, and opened the bowel at once, and a large quantity of liquid treacle-like fæcal matter escaped. The patient rapidly improved, and when the abdominal distension had subsided a hard mass could be felt through the abdominal wall in the left iliac region. From the extent of the growth, and from the attachments, it was clearly not advisable to attempt extirpation. She left the hospital on April 6th, having gained flesh greatly, and in fair health. I saw her from time to time during the year; she was able to do her ordinary household work. The bowels were open once a day by the colotomy opening. There was occasional discharge of blood and mucus by the anus, but scarcely any fæcal matter passed this way.

Early in November, whilst making her bed, she felt something snap in her right arm, and found she had lost all power in it. She came to the hospital, and a fracture was detected a little above the centre of the humerus, with a little swelling of the soft parts, but no evidence beyond the fracture and her previous history of any growth. A plaster splint was applied, and she attended as an

Digitized by Google

out-patient till December 10th. Union had not taken place, and a very considerable tumour of the bone was manifest. She was suffering so much pain, and was emaciating so rapidly, that she at last consented to again come into hospital. The colotomy opening was about the size of a shilling, without any prolapse, and no excoriation of the surrounding skin. The rectal tumour had increased in size, but not to any great extent. No evidence of further growth in the abdomen or elsewhere was to be detected.

On December 24th, 1890, I amputated at the shoulder-joint by skin flaps, having first ligatured the artery in the axilla. The patient made a rapid recovery, and left the hospital on January 14th, 1891, with a perfectly healed stump, and having gained flesh in a surprising manner. Indeed, she left the hospital looking far stronger than after the colotomy one year before.

The tumour of humerus is of large size, and looks very like an ordinary subperiosteal sarcoma which has involved the medullary cavity. The growth extends up to the head of the bone, and is of pretty firm consistence. The primary fracture is evident at the lower part of the growth; the upper fracture was probably done during the manipulation at the amputation.

A microscopic examination of the tumour made by Mr. Shattock shows it to be, as expected, a columnar carcinoma, so perfect in character that it would be impossible to distinguish it from a similar growth in the rectum.

I can find no reported case of such a growth in bone secondary to tumour of bowel, and the specimen is of considerable interest as an example of most perfect reproduction in bone of the original type of glandular tumour of bowel. In the 'Pathological Transactions' for 1886 a case is recorded by Mr. Jonathan Hutchinson, jun., of a similar growth in the humerus, removed by amputation at the shoulder by Mr. Jonathan Hutchinson, and which was suspected to be a secondary cancer to some primary growth in the alimentary canal, but where unfortunately there was no opportunity for *post-mortem* examination, and where no abdominal symptoms had been present during life.

In the present case it is quite clear that the tumour cannot be described as a cylindrical sarcoma, and the specimen shows how closely in general appearance a carcinoma in bone may resemble a sarcoma, and possibly by some have been described as such, if we had not had the direct evidence of the primary bowel tumour.

Digitized by Google

The life history of columnar carcinoma of bowel has not been very satisfactorily determined, for the growth is often present for a long time without giving rise to any direct symptoms; it may remain for at least one or two years local, not even implicating surrounding structures. Considering the constant irritation such a tumour is exposed to by the evacuations, it is remarkable how such quiescence can be maintained. So few of these tumours have been removed at an early period that we can form no estimate as to the prognosis in early and complete excision, but it must be more hopeful as regards life than in carcinoma in most other places.

On the other hand, we occasionally meet with cases where the growth in bowel has been so small as not to give rise to symptoms, and yet large secondary deposits have been found in the glands and liver; but it does not at all follow that the primary growth has been of short duration. *February 17th*, 1891.

---

19. *Charcot's disease of both knee-joints.* (*Card specimen.*)

By J. H. Targett, M.B.

These specimens were removed from a female dissection subject, aged 77 years, of whom no history could be obtained. The remaining large joints of the body were not affected, but the condition of the carpus and tarsus was not specially noticed.

Description of specimen.—The *left* knee-joint has been macerated. The shape of the lower end of the femur is modified by the complete destruction of the external condyle, and the formation of well-marked bony lips to the articular surfaces. The articular surface of the internal condyle shows small patches of the normal articular lamella, which were covered with healthy articular cartilage in the recent state; but the greater part of this surface is covered with a layer of spongy new bone, one third of an inch thick, which has a rounded everted margin overhanging the compact tissue of the shaft. In the site of the external condyle the cancellous tissue of the shaft forms the articular surface, the margins of which are likewise beset with overhanging new formations of bone. The

Digitized by Google

change in the shape of the head of the tibia is the result of a deep excavation of its articular surface, so that the distinction between the external and internal portions of this surface is entirely lost. The upper surface of the head of the tibia is marked by a broad groove, deeper behind than in front, the long axis of which corresponds with the sagittal diameter of the bone. The area of this excavated surface is much increased by the development of new bone on its external and posterior margins. By means of this new bone the upper end of the fibula has become ankylosed to the tibia. The articular surface of the patella shows marginal bony outgrowths.

When the bones were articulated the head of the tibia was much displaced outwards, so that the long axis of the tibia was nearly at right angles to that of the femur. The groove on its upper surface was adapted to the stump of the external condyle, and the inner margin of the tibial articular surface fitted with accuracy into the intercondyloid notch. It will be observed that the internal condyle of the femur has thus escaped friction.

On the *right* side, where the soft parts have been preserved, the changes are remarkably similar. The external condyle of the femur has been largely destroyed, and is represented by a rounded stumpy process; while the internal condyle is reduced to a narrow ridge, 1½ inches in height, and ¾ of an inch in thickness. The upper surface of the tibia is much worn away, especially at its posterior internal angle, and the bone itself is displaced and rotated outwards as on the opposite side. The articular surfaces of the tibia and femur are everywhere covered with a fibro-cartilaginous material, which in some places is smooth, and in others nodular or beset with villi. The cavity of the joint is considerably enlarged owing to the destruction of bone, and its interior shows many polypoid bodies and additamentary bones attached to the capsule. The fibula is ankylosed to the tibia by bony deposit as on the opposite side. Owing to the destruction of the head of the tibia, the semimembranosus tendon is attached to the bony deposit in the capsular ligament. Histologically the polypoid bodies within the joint are chiefly composed of cartilage, the matrix of which is hyaline in some parts and fibrous in others. The cartilage capsules are small and not numerous, and in the centre of the body they are undergoing calcification. *March 17th*, 1891.

Digitized by Google

20. *Patella with (dislocated internal semilunar ?) cartilage fixed to it.*

By H. D. Rolleston, M.B.

The patella had attached round the margin of its articular surface a meniscus of cartilage, thinner on its inner than on its outer border, and adherent only by its outer border to the margin of the articular surface of the patella. The attachment was, like that of the semilunar cartilages, to the head of the tibia by the coronary ligament. The articular surface of the patella was normal.

Between the articular surface of the patella and the overhanging surface of the cartilaginous meniscus there was a space lined with synovial membrane, resembling that normally found between the head of the tibia and the semilunar cartilages. This condition was found all round the ring of cartilage except at the upper border of the patella, where the patella and the cartilage were adherent for the whole extent of the latter.

At the middle of the outer border of the patella this abnormal cartilage became much wider (three times the width of the remainder) and also thicker. The shape of this abnormal cartilage thus resembles the profile of a signet ring (*vide* drawing).

This patella was removed from the right knee of a man, aged 44 years, who died in St. George's Hospital under the care of Dr. Whipham. As the result of a severe injury seventeen years before death the right tibia had been dislocated outwards, the external condyle alone of the femur articulating with the tibia, the internal condyle projecting under the skin.

At the *post-mortem* there were chronic rheumatoid changes in the joint, lipping of the cartilage and osteophytes on the condyles of the femur, and partial destruction of the external semilunar cartilage. The conical ligaments were intact. The internal semilunar cartilage was absent from its position, and no trace of it was to be found on the head of the tibia. Unfortunately the head of the tibia was left in the body, and so could not be exhibited along with the patella to support the view that the adherent meniscus of cartilage was the dislocated internally semilunar cartilage adherent to the patella.

Digitized by Google

It is suggested that at the time of the injury which produced the partial dislocation of the tibia outwards the internal semilunar cartilage was torn off from the tibia and completely separated

FIG. 16.

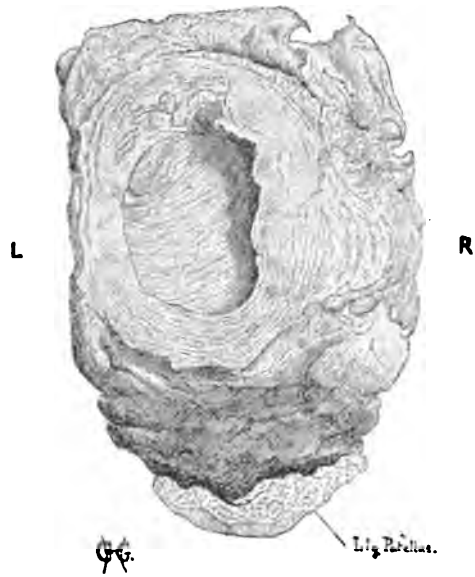

The parts described. The patella is viewed from behind, and is furnished with a flattened circular fibro-cartilage. R. Right side. L. Left side.

from its connections; that this free cartilage turned over so that its tibial surface became applied to the patella, and its two free ends turned to the outer border of the patella; and that, aided by traumatic synovitis (set up by the injury to the joint), it contracted adhesions to the margin of the articular surface of the patella. That the two free ends overlapped and became adherent, and in time became so firmly welded together by the pressure of the femur as to form the enlargement on the otherwise uniform ring of cartilage.

The fact that the crucial ligaments were found intact at the *post-mortem* might be taken as evidence against the view that the internal semilunar cartilage had been dislocated, for this could not have taken place so completely without rupture of the crucial liga-

Digitized by Google

ments. But it should be remembered that the crucial ligaments, if ruptured, might contract fresh adhesions.

That there are considerable difficulties in explaining the presence of this abnormal cartilage in connection with the patella there is no doubt. Its presence must have been either congenital or acquired.

As the knee-joint had been subjected to severe injury, it seems more reasonable to suppose that the internal semilunar cartilage was torn off by the partial dislocation outwards of the tibia, and subsequently contracted adhesions to the patella, than to regard it as a hypothetical congenital abnormality. *March 3rd*, 1891.

---

21. *A piece of the patella cartilage knocked off and forming a loose body in the knee-joint.*

By W. Bruce Clarke, M.B.

On May 1st, 1891, James Wilson, aged 28, slipped as he was getting on to an omnibus, and hurt his knee, knocking the knee-cap against the edge of the steps. He was brought into the West London Hospital with his knee very much swollen, and put to bed. A back splint was applied to the limb. As his knee-joint was fixed in the flexed position when he came in, one of the semilunar cartilages was supposed to have been dislocated. After a few days the effusion in the knee-joint subsided, and he was allowed to get up. He was, however, seized with violent pain in the knee whilst he was walking in the ward, produced, he thought, by catching his toe against a chair. His knee-joint was then very carefully examined, and the internal semilunar cartilage was found to be dislocated, and to move very freely in any direction. Under these circumstances, as he was a young and healthy man and anxious to get to work again as a platelayer, an operation was proposed. When the knee-joint had been opened, the semilunar cartilage was found to be loose, and was stitched down. Whilst, however, I was pulling the patella out of the way, so as more readily to insert the stitches, I discovered that a piece of the

Digitized by Google

cartilage from the under surface of the patella had been knocked off, evidently quite recently, exposing the bone underneath, and almost before I had time to turn round the piece of cartilage in question was floated up into view and picked out. It was carefully compared with the abraded surface, as I was anxious not to leave behind a piece of the abraded cartilage. There was no doubt whatever that it exactly fitted into the abraded surface.

The joint was closed and healed readily, and the man was at work again in six weeks.

He has since been under my care for a loose body in the other knee-joint, from which another loose body had been removed seven years previously by Mr. Baker of Birmingham.

It is perhaps of some interest to note that this joint, which had been operated on seven years ago, had now become the seat of rheumatoid change, as evidenced by lipping of the cartilage on the edge of the articular surface of the femur, though the right knee-joint, on which I operated first, was perfectly healthy.

This specimen is, so far as I know, unique. I have been unable to find any record of a similar one. It would appear, if the history of the accident be a correct one, that the patella was knocked by the steps of the omnibus, and partially dislocated, so that the cartilage on its under surface was abraded by the edge of the condyle of the femur, just as the skin of one's knuckles is when it comes into contact with any hard surface. It is likewise worthy of note that the movements of the joint are quite perfect.

March 3rd, 1891.

---

22. *Two loose bodies removed from a knee-joint separately with an interval of four weeks.*

By Edgar Willett, M.B.

The two loose bodies were removed from the left knee-joint during the summer of 1890 by Mr. Harrison Cripps, who kindly gave permission to publish the case; the history was as follows:

The patient, a healthy young man of 23, an assistant at an

Digitized by Google

asylum, stated that his left knee had been slightly stiff for many years. Towards the end of July, 1890, while playing cricket, he suddenly felt something give in his knee, and noticed shortly afterwards that there was a lump on each side of the patella. He was admitted into St. Bartholomew's Hospital on July 31st; there was some effusion in the knee-joint, and a loose body was easily felt on the outer side of the patella. On August 6th an incision was made over it, and the body was removed without any difficulty: the wound healed readily without any complications. Three weeks later, just as the patient was about to leave the hospital, he found another "loose body" in the inner side of the joint. On September 2nd, four weeks after the first operation, this was removed in a similar way with an equally good result.

On examining the two bodies the resemblance to each other is most marked; they are flat, about an inch square, cartilaginous on one surface, calcareous or bony on the other, slightly doubly convex on the cartilaginous surface. By one of the edges they fit together so accurately as to make it almost certain that they once formed part of the same mass; they had probably become detached from the cartilage covering the outer condyle.

March 3rd, 1891.

---

23. *Fifty loose bodies removed from a knee-joint.*

By James Berry, M.B., B.S.

These fifty loose cartilages were removed by operation from a knee-joint. They vary much in size, the largest being 1¼ inches long and 1 inch broad, the smallest not much bigger than a large pin's head; the others are of all sizes between these two extremes. The larger ones are flattened, the smaller ones either round or flat.

All are white in colour, smooth and shiny on the surface; none have pedicles, nor were they attached in any way to the synovial membrane. The chief peculiarity about these bodies lies in their structure. The larger ones consist of a number of small nodules

Digitized by Google

of cartilage held together by an intervening network of very loose fibrous tissue, the whole surrounded by an imperfect fibrous capsule. No epithelium can be seen upon the outer surface. The smallest bodies consist of a single nodule of cartilage surrounded by a layer of fibrous tissue. It is evident that these small bodies have been derived from the interior of the larger ones.

The patient was an otherwise healthy young man, aged 18. For about six months he had been subject to attacks of synovitis in the right knee, which prevented him from doing his work. About two or three weeks before admission to the hospital he had noticed that something moved about in his knee. He had never had rheumatism or gonorrhœa, nor had he ever to his knowledge injured his knee.

I removed the loose bodies by direct incision, and the wound healed in a few days. It is now more than three months since the operation was performed, and no further symptoms have hitherto been detected.

As to the origin of these loose bodies I am unable to express any definite opinion. I believe that they have not been formed from fringes of synovial membrane because they were all free in the joint, and because the portion of the synovial membrane that was seen at the time of operation appeared to be quite healthy. Only at one spot at the upper part of the joint this membrane was thickened and formed a hard lump, and this may have been the spot from which the loose bodies were derived.

October 21*st*, 1890.

---

24. *Loose bodies from a tubercular knee-joint.*

By Howard Marsh.

[With Plate V.]

Mary R—, aged 17, was admitted into St. Bartholomew's Hospital in May, 1890, for tubercular disease of the left knee, which had been in progress for three or four years. Thickening of the synovial membrane had produced moderate swelling, but the joint was cool and free from pain. The leg, however, was flexed upon the thigh, and the tibia was displaced backwards, and

Digitized by Google

rotated outwards to such a degree that the deformity could be corrected only by excision of the joint. At the operation, when I had divided the quadriceps extensor tendon, and was turning the patella down, five loose bodies escaped from the cavity of the joint. They were about the size of almonds, glistening and perfectly smooth on the surface, of a pale yellow colour, and apparently consisted of masses of fat. The joint was extensively diseased. The synovial membrane was thickened, and had overlapped the articular cartilage covering the internal condyle of the femur and the inner facet of the tibia; the cartilage was widely eroded, and the inner facet of the tibia was deeply excavated. These changes had evidently been long in progress; but there was no suppuration, and the joint contained no fluid. The patient made a good recovery, the wound healing except at the angles by primary union.

The temperature was normal throughout, and the dressings were changed only twice—once on the night of the operation, as there was free oozing, and again on the tenth day. The bones were fastened together with bone pegs, the ends of which were cut off short, so that they were submerged beneath the skin.

On examining the section, which had been removed from the femur during the operation, I found two bodies, similar to those which had escaped from the joint, still attached to the synovial membrane in the situation in which they were originally formed. As all these bodies appeared to be alike, a description of one will apply to the others also. The specimen selected for examination was found, after immersion in spirit, to consist of a shell or capsule enclosing a central mass with an intervening space. The capsule was firm, and of the consistence of coagulated fibrine. The central portion resembled in general appearance those shaggy masses of fibrine which are often found in the cavities of bursæ. I am indebted to Mr. Edgar Willett, the Curator of the Museum, for the following report:

"Under the microscope, the difference between the outer layer, or shell, and the central portion, or kernel, is very distinct. The outer layer varies in thickness according to the size of the bodies, but has an average depth of rather less than one sixteenth of an inch. It is composed of a uniform granular collection of cells, without any stroma or definite structure. The transition to the inner part, or kernel, is very marked. This (the kernel) has an imperfect and irregular structure of its own, the most striking feature of which

Digitized by Google

is the presence of a considerable number of well-defined collections of small cells, either circular or oval in shape, and recalling at once the look of the giant-cells found in tubercular deposits. Although some of the sections have been stained, with a view to demonstrate the presence of tubercle bacilli, these were not detected. There are also numerous small irregular spaces with well-defined walls, and filled with granular material. These are probably blood-vessels, the coagulated blood in which has assumed a granular appearance. The rest of the structure is too indistinct and uncertain for a detailed description, beyond that it shows, in places, a wavy, almost fibrous appearance."

I have not met with loose bodies of this kind before, but after Mr. Willett's report of their microscopical structure I regard them as tubercular formations in the fringes of the synovial membrane, to which some are still connected, while some have been detached. Their capsule apparently consists of a layer of coagulated fibrine, while the cavity they present is probably due to softening, the result of imperfect nutrition. The view which some might be inclined to hold, that these masses are similar to the melon-seed-like bodies often found in the sheaths of tendons, is, I think, negatived by the fact that the two differ from each other in the structure which they present. The melon-seed-like bodies are quite amorphous—merely granular, or at the most dimly fibrillated, —evidently nothing more than masses of coagulated fibrine. The bodies which I show to-night present the microscopic structure of tubercle in, I think, an unmistakable form.

In a very able and interesting essay on tuberculosis of bones and joints, Mr. Alexis Thomson, of the Royal Infirmary, Edinburgh, has a chapter on nodular tubercle of the synovial membrane, a condition first described, as he informs us, by Riedel. Mr. Thomson says, "The appearances in typical cases closely resemble those seen in certain forms of arthritis deformans; the synovial membrane is much thickened and quite firm; its free surface and margins are thrown into fringes and folds like a cauliflower; the latter overhang the articular surfaces (that of the patella appearing almost buried) but are not in contact with them, nor do they become adherent to the cartilage in the fashion characteristic of the gelatinous membrane. Pedunculated excrescences and nodular masses, often of considerable size, may project from the surface of the membrane, which may itself be covered by a layer of fibrinous

Digitized by Google

Digitized by Google

DESCRIPTION OF PLATE V.

Illustrating Mr. Howard Marsh's paper on Loose Bodies from a Tuberculous Knee-Joint. (Page 276.)

From drawings by Miss A. Stone.

Fig. 1.—Part of a section of one of the tubercular loose bodies. At the highest part of the section is a more deeply stained zone of granular cells, which form a general crust or shell to the loose body. About an inch below this is a giant-cell. In the general substance are shown the divided surfaces of obliterated blood-vessels.

Fig. 2.—A section of an ordinary melon-seed body for comparison, showing a general granular, and at places a dimly fibrillated structure.

Digitized by Google

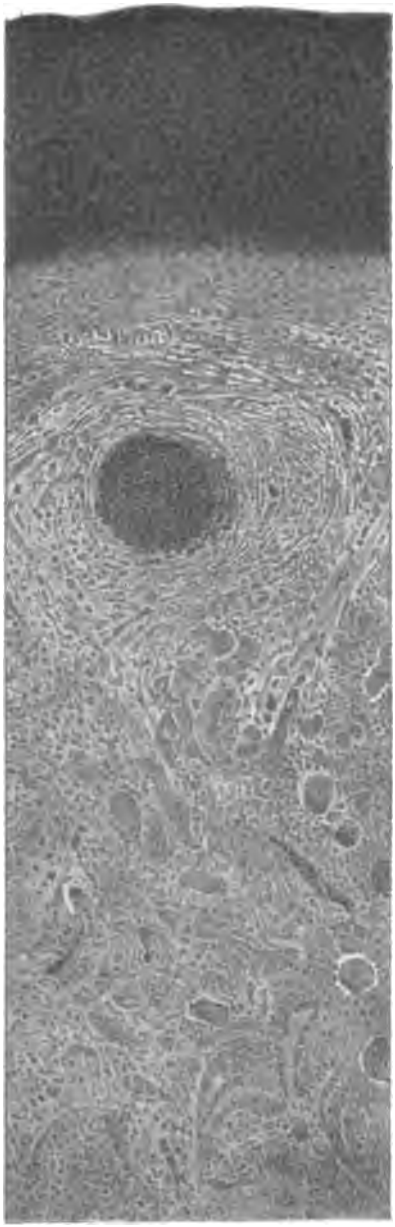

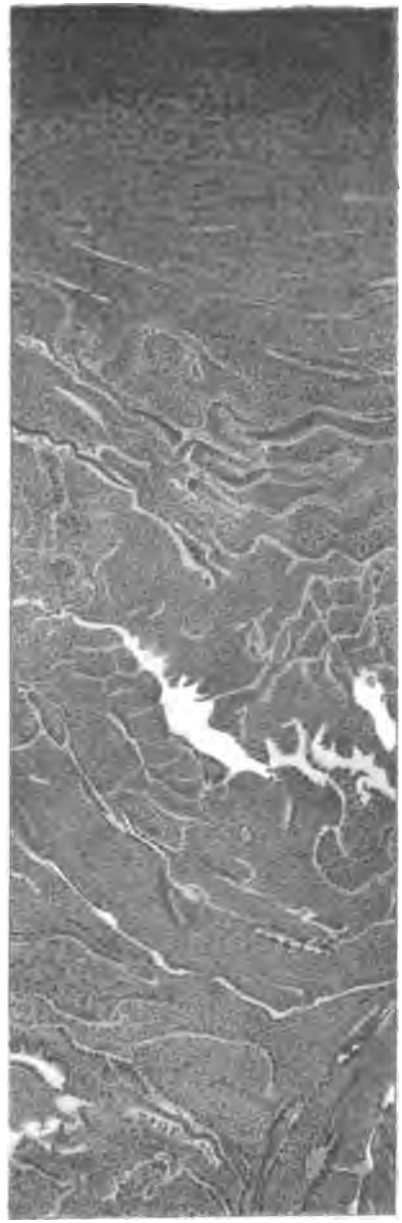

Digitized by Google

Digitized by Google

lymph, or be shining and translucent, and of a rose-red colour from vascular injection. The joint cavity usually contains a quantity of turbid fluid, in which there may be masses of clotted lymph or melon-seed-like bodies; or, again, bodies consisting in part of fully developed tissue, *e.g.* cartilage, bone, &c. The last mentioned may be present in large numbers and be of considerable size. The clots and melon-seed bodies are simply made up of coagulated fibrin, but those consisting of fully developed tissue are derived from the synovial membrane as follows:—An inflammation of the membrane results from the entrance of the tubercular virus into its tissues, which is at first characterised by an effusion into the joint, and a deposit of fibrinous lymph on the surface of the membrane; a process of organisation then ensues, whereby the superficial layer of the membrane, together with the lymph, becomes converted into a very vascular granulation tissue, in which are to be recognised a number of young tubercular granulations, situated for the most part around the newly formed blood-vessels running towards the free surface. As a result of these changes the synovial membrane becomes thickened in the nodular fashion already described, while polypoidal portions are detached by movement of the joint, and are found free in the cavity of the latter as lymphy clots or as organised 'loose bodies,' the embryonic cells belonging to the synovial tissue undergoing a further development into cartilage or bone. Portions of white fibro-cartilage may be found in these bodies, and are probably derived from the semilunar discs in the case of the knee."

Mr. Watson Cheyne, in his lectures at the College of Surgeons last year, also mentions the subject, and states:

"The synovial membrane is reddened, often thickened, and shows one or more firm prominences on the surface. The joint frequently contains fluid, and rice-like bodies. The nodules contain numerous tubercles, often closely packed together." He mentions a case in which on the inner side of the knee-joint a nodule was felt, which seemed like an attached loose cartilage. On cutting down, this was found to be a polypoid thickening of the synovial membrane. The nodule was freely removed. On examination it was found to be tubercular. *March 3rd*, 1891.

Digitized by Google

25. *Genu recurvatum in a fœtus at term.* (*Card specimen.*)

By Samuel G. Shattock.

[With Plate VI.]

The fœtus, save for the condition of the knee-joints, is well developed, and was born at about the full term. Death took place during delivery from asphyxia, and the specimen was subsequently presented to the museum of St. Thomas's Hospital by Mr. B. E. Spaull, in whose practice the case occurred.

The accompanying figures, which were traced from the specimen, will show at a glance the abnormal disposition of the lower limbs *in utero*, which brings about the hyperextension of the knee-joints in the condition under notice, and for which the term "genu recurvatum" is used by German writers; although to those who adopt such nomenclature as "in-knee" and "out-knee," "back-knee" may seem perhaps a proper equivalent.

The lower limbs, instead of being flexed at the knee as they normally are throughout gestation, are over-extended, the feet lying against the neck, with the soles pressed under the chin.

The hip-joints do not admit of flexion beyond a right angle.

The left knee cannot be brought beyond the straight line; the right allows only of the slightest degree of flexion—it cannot be flexed to the same degree that it can be over-extended.

The feet lie at right angles to the leg, and are in no ways clubbed, either by inversion or eversion, flexion or extension. The pressure of the feet which are tightly jammed, from the flexion of the head, against the lower jaw, has led to a remarkable deformity of the face; there is no chin.

The front of the lower jaw lies 1·5 cm. behind the front of the upper and at a slightly higher level; dissection, however, shows no dislocation (the articulation is normal), but a curious want of growth in the arch; the arch as such is almost wanting, the body of the jaw being directed abruptly from the ramus of either side towards the middle line.

Dissection of the left knee-joint.—This I carried out in a way to observe what structures prevented the reduction of the deformity. The removal of all the muscles allowed of no change whatever in the position. I next divided the capsule longitudinally on either

Digitized by Google

side of the patella, and turned the latter completely down, but the joint was as incapable after this as before of being brought to the straight line. On attempting flexion it was easy to observe that the resisting structures were the anterior portions of the capsule, *i. e.* those in front of the lateral ligaments; these became extremely tense. The external lateral ligament was relaxed on straightening the joint, and made tense in the position of hyperextension; the internal was in like case. The patella, when in position, lies altogether above the trochlear surface of the femur, and between the two bones is a synovial space separated from the rest of the joint by a delicate film of membrane. As the anterior surface of the femur is here slightly concave, the patella in the hyperextended position loses its usual prominence; this accounts for the difficulty with which it is sometimes felt during life in this deformity; it has sometimes been thought, erroneously in most cases, to be absent. I then cut the capsule horizontally between the tibia and the femur as far back as the external lateral ligament, and nearly as far as the internal; still the joint would only admit of being brought as far as the straight line: it is needless to say that the posterior part of the capsule is relaxed when the joint is straightened. On cutting the capsule on the inner side as far back as the internal lateral ligament, the knee could at length be flexed, though only to a limited extent, not to a right angle, though to somewhat more than an angle of 45°. The obstacle to further flexion was the crucial ligaments.

When the joint is forced in flexion, the anterior fibres of the anterior crucial ligament are made tense, the posterior relaxed; and at the same time the posterior fibres of the posterior crucial ligament are relaxed, the anterior fibres made tense. In addition to these changes, it is especially noteworthy that, from the forced hyperextension and long-continued immobility, the ends of the bones have undergone change in form, as the astragalus is found to have done at the time of birth in the more severe cases of congenital equino-varus.[1]

The upper surface of the tibia presents no obvious alteration in form, but the lower end of the femur is markedly misshapen.

The area of the femur articulating with the tibia is much ex-

[1] For what relates to the pathology of club-foot I may refer to the paper by Mr. R. W. Parker and myself in the thirty-fifth volume of the Society's 'Transactions.'

Digitized by Google

tended forwards, and this has led to the disappearance of the lower and chief part of the trochlear or patellar surface, though the two do not lie in the same plane, but meet at an obtuse angle. The surface in contact with the tibia is as a whole concavo-convex from before backwards, the anterior concavity corresponding with the slight convexity presented in the specimen by the anterior margins of the facets on the tibia bordered with their semilunar cartilages. The plane of that portion of the condylar surface which is in contact with the tibia is directed forwards and unnaturally upwards, so that when the joint is brought to a straight line, there is a wide interval in front between the flat articular surface of the femur and that of the tibia. The lower surface of the femur is, in short, flattened anteriorly, and the proper trochlear surface correspondingly curtailed in the vertical direction.

So much for what dissection shows in regard to the altered anatomy of such a joint.

And in passing, the practical conclusion to be drawn is that any operation practised for the reduction of genu recurvatum in its extreme grades, when it will not satisfactorily yield to manipulation, should be directed certainly to the moiety of the capsule in front of the lateral ligaments, whatever else it may be thought advisable to divide. Yet, whilst the ligamentous structures are growing, and ready to adapt themselves to the requirements forced upon them, it is remarkable how exercise, active or passive, will increase their growth in length, and render operative measures unnecessary.

The tenotome might be passed without risk by one or more perforations between the tibia and the femur, so as to divide horizontally on either side the whole of the capsule as far back quite as the lateral ligaments.

The method should be here as in club-foot. In the paper before referred to, Mr. Parker and I have pointed out the important fact played by the shortened ligaments in preventing the reduction of severe grades of the deformity, and Mr. Parker there advocated, and has since more fully done so,[1] the advantage to be gained by dividing the shortened ligaments as well as the shortened tendons. Mr. Edmund Owen has successfully dealt with a case of genu recurvatum under his care[2] by free transverse open incision across the whole front of the knee above the patella. The case concerned

[1] 'Congenital Club-foot,' 1887.

[2] Medical Society, reported in the 'Lancet,' May 2nd, 1891.

Digitized by Google

Digitized by Google

DESCRIPTION OF PLATE VI.

Illustrating Mr. Shattock's communication on Genu Recurvatum. (Page 280.)

From drawings by the author.

FIG. 1.—An outline of the fœtus described in the text, showing the abnormal disposition of the lower limbs in utero (the knee-joints hyper-extended) which leads to the malformation.

FIG. 2.—The head, &c., of the same. The right foot has been drawn aside to show the absence of chin, resulting from the pressure of the lower jaw against the feet.

FIG. 3.—A dissection of the left knee-joint viewed from the outer side. The tendon of the biceps is shown passing to its insertion into the head of the fibula, and the external popliteal nerve crossing over the outer condyle of the femur, which is unduly prominent behind owing to the hyper-extension of the joint.

FIG. 4.—The bones of the same joint *in situ*, the lateral ligaments being left. In consequence of the hyper-extension the surface of the femur, articulating with the tibia, is unduly extended forwards and flattened.

FIG. 5.—The lower end of the femur viewed from the front. The two facettes which appear are those articulating with the upper surface of the tibia. Above them is a narrow articular strip, the sole remains of the trochlear or patellar surface, the patella having lain almost entirely above this in consequence of the over-extension of the joint.

Digitized by Google

Fig. 1.

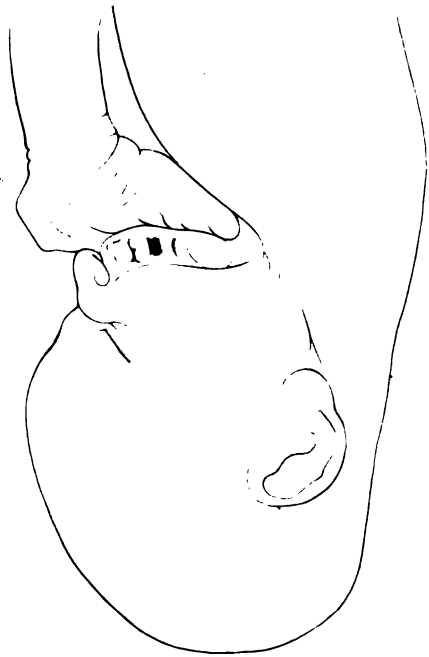

Fig. 2.

Fig. 4.

Digitized by Google

Digitized by Google

a girl three and three quarter years of age, a head presentation, birth occurring with the feet resting upon the shoulders; even under chloroform the legs could not be brought into a line with the thighs. Mr. Owen divided the quadriceps extensor by a free transverse incision which *fully exposed the trochlear surfaces;* the bones could now be flexed to a right angle; massage and manipulation were still being employed when the case was reported. Here the capsule was of course divided with the other structures, above the patella; but I imagine a nearly similar result might be gained by dividing the capsule alone as suggested, and leaving it to manipulation to effect the rest.

The history attaching to the present specimen is simply that the child died asphyxiated during delivery, before the head was born. The position was cephalic. Adams ('Club-foot,' second edition, pp. 221, 350) erroneously states that all such cases are breech presentations.

There are other previous children in the family who present no abnormality. Lonsdale met with three children born of the same mother, all of whom were affected with the deformity ('Lancet,' Sept. 4th, 1855, cited by Adams, loc. cit., p. 351).

There was, in the case under notice, no marked deficiency in liquor amnii, and no tumour of the uterus.

I have dissected two other such cases, which are briefly referred to in the paper noticed ('Path. Soc. Trans.,' vol. xxxv). In the more marked of them the hip-joints admitted of only limited extension; the knees were over-extended and incapable of being brought beyond the straight line; after all the muscles had been dissected away no flexion of the knees was possible, and, as in the present specimen, it was only after dividing the whole of the capsule in front of the lateral ligaments that the joint could be flexed: the articular surface of the femur had undergone alterations in form, in adaptation to the over-extended position in which the joint was fixed. And similarly in the second of the two cases no flexion was allowed, even after all the soft structures save the capsule and ligaments had been dissected away.

That the condition is not one merely incidental to parturition is clear, not only from the existence of specimens which show the fœtus with the knees extended within the membranes (Museum Coll. Surgeons, 3646A; Guy's Hospital, 853[50] and another), but from the fixation of the knees in this abnormal position of hyper-

Digitized by Google

extension. The latter fact proves the condition to be one due to a prolonged malposition *in utero*. The soft structures, the ligaments more especially, on the side of relaxation, under such circumstances literally grow too short, and so resist the proper movement of the joint in the contrary direction.

In the child at birth, as Hueter pointed out, the hips and knees do not admit of full extension; neither does the foot. But under normal circumstances the flexed hips and knees and ankles are not so fixed by environment that all movement is impossible; were it so the range would be far more considerably limited at the time of birth than it is.

As in congenital club-foot, whether calcaneus or varus, so in genu recurvatum, there are different grades. So far as the fixation of the joint goes, the present is of the extreme kind, though cases of greater deformity are recorded—there may be such a complete hyperextension that the anterior surface of the leg may be brought against the front of the thigh.

The joint is as fixed as in the most severe case of club-foot, and if an operation were not absolutely needed, it would at least expedite the cure. But there are others where passive movement and manipulation suffice, and in practice most are of this kind; cases where, although the lower limbs during gestation have been disposed with the feet towards the head instead of towards the buttocks, some amount of flexion at the knee has presumably been allowed. And, in passing, the readiness and completeness with which cure may be brought about is as invincible an argument as it is in the case of congenital club-foot, that the malposition cannot be due to the paralysis of any particular group of muscles arising from lesions of the central nervous system.

Genu recurvatum, like club-foot, is sometimes limited to one limb. Mr. R. W. Parker tells me that he has seen one case of this, though they are rare. In St. Bartholomew's Hospital Museum there is a specimen (No. 1226) of a fœtus of about seven months, within the membranes and uterus; and in this, whilst the right lower limb is in the normal position, the knee of the left is extended, and the foot lies in an enforced position of talipes varus against the opposite cheek, the sole being apposed to the wall of the uterus ('Path. Soc. Trans.,' vol. xxxv, woodcut 11, p. 440).

Through the kindness of Mr. Pitts I am able to record two marked examples of this unilateral form, lately admitted into

Digitized by Google

St. Thomas's Hospital, the first of which is represented in the accompanying figure.

FIG. 17.

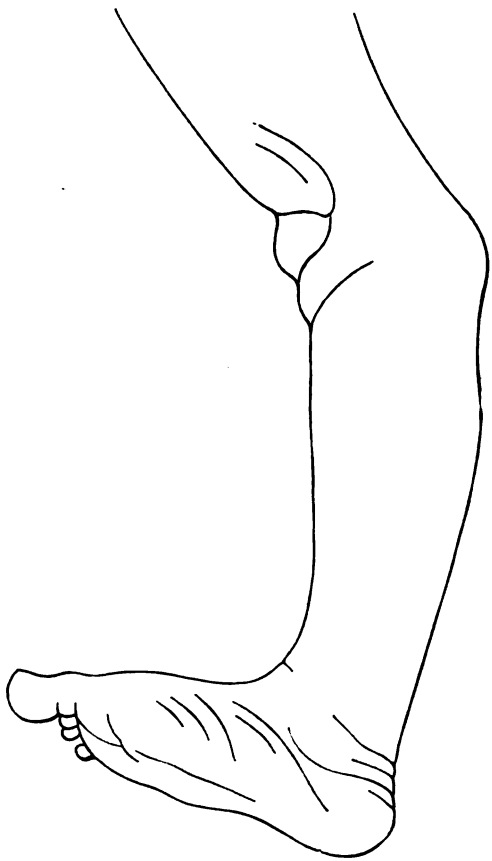

From a unilateral case of genu recurvatum admitted into St. Thomas's Hospital. The rounded eminence at the back of the knee is produced by the projecting condyles of the femur. There are three deep furrows on the front of the knee, resulting from the hyperextension of the joint.

The child, a female, was ten months old, and presented no deformity except that of the right knee, of which the woodcut gives

Digitized by Google

an accurate representation, reduced from an ink tracing made directly from the limb on a sheet of glass.

The position in which the knee was naturally kept was that of hyperextension; passive flexion was allowed to about the same degree as the joint was over-extended, the movement of flexion being accompanied with a sudden slip, due evidently to an abnormal configuration of the articular surfaces: the patella was well developed. Both the hip-joints admitted of full extension, and the foot of the affected limb could be brought to a right angle.

The case was treated by being put on a splint in a position of flexion as far as was allowed, and passive movement was daily had recourse to.

After two months' stay the knee could be flexed to a right angle; the patient was then discharged, the above treatment being continued. The mother died shortly after the child was admitted, and was not herself seen, but she was said by a relative to have fallen downstairs about the middle of pregnancy.

The second case, which was also admitted into the hospital by Mr. Pitts, was that of a female child, four days old, which was prematurely born at the seventh month. The hyperextension allowed in the right knee almost reached a right angle, but in the other direction the joint could not be bent beyond the straight line. No other deformities were present. In general characters the malformation completely resembled that shown in the figure of the foregoing case. The amount of liquor amnii was computed at between four and five fluid ounces only. The labour was quick. The position of the left lower extremity was normal; that of the right was such that the toes were over the shoulder and the heel directed forwards. The child was the first of an unmarried woman. *The mother two months before delivery fell downstairs, striking the back and right side.*

The child was not subjected to treatment and died about a week after admission from inanition.

Hibon[1] asserts, from a review of cases he had collected, that when the condition is bilateral the fœtus most often presents a series of malformations or an arrest of development which renders it a monster.

A more extensive collection of cases, however, shows that the

[1] 'Luxation congénitale du tibia en avant.' Thèse de Paris, 1881.

Digitized by Google

malposition is not rarely double, and is the only deformity present, as in the first cited case of the present communication.

The reversion of the knee may be accompanied with rotation of the leg, either inwards or outwards (Hibon, loc. cit.).

The position of the feet varies. In the case recorded the feet are symmetrically wedged beneath the chin, and not deformed.

But they may lie with the soles against the chest in the position of talipes calcaneus (fig. 14, R. W. Parker, loc. cit.; fig. 71, Adams, loc. cit.). Or, as in Cruveilhier's case ('Anatomie Pathologique,' 2 livraison, pls. ii, iii), the feet may be in a position of varus; and so in the example figured by Adams (fig. 38, loc. cit.).

In the present instance the abnormal extension of the knees is associated with an unusual degree of limitation to the extension of the hips. The hips are in the right position, viz. that of flexion, but their fixation proves how little movement was allowed to them during intra-uterine life.

Adams (loc. cit.), in discussing the complications of talipes, refers to genu recurvatum under the title of "rigidity of knee-joints in an extended position;" and he observes that such cases as have fallen under his observation have generally been associated with other complications, such as stiffness of the hip-joints, club-hands, &c.

As to what the precise causes are that bring about this anomalous position of the lower limbs, few data are yet forthcoming.

In the course of their development the lower limbs are at first simple lateral extensions from the trunk, disposed almost transversely, and folded against the body of the embryo; the feet are subsequently brought downwards by rotation from the hip-joints combined with flexion of the knee, the extensor surfaces being carried forwards and the flexor surfaces backwards.

The first thing that suggests itself is that the rotation of the lower limbs at the hip-joints has occurred in the contrary direction, so that the feet have been brought upwards to the head in place of down towards the buttocks. This is what really seems to take place in sireniform monsters, or those in which the lower limbs are fused together beneath a common integument; the combined limbs are disposed with the hips flexed and knees extended, the feet being directed towards the cephalic extremity.

There is, however, this important difference between the two cases. In the sireniform monster the feet are reversed; that is to

Digitized by Google

say, when the limbs are straightened at the hips, the heels look forwards and the patellæ backwards: in genu recurvatum when the hips are extended the heels are directed backwards and the patellæ forwards as in the normal limb.

Hence in the sireniform monster, although the knees are in the extended position, there is no hyperextension, but slight flexion, for the ham, and not the front of the knee, is directed against the trunk.

In the monster there is in all cases arrest in the development of the pelvis and pelvic viscera; and this arrest of the posterior extremity of the axis is usually taken as explaining the other malformation. Such an arrest would entail so close an approximation of the primitive lower limbs either as to allow of their fusion, or to bring about their being formed from the first in a single median bud.

Be it either way, since those borders of the primitive limbs which are directed backwards, or post-axial, are those that lie in proximity, it is along these that the confluence would take place; and as these subsequently give rise to the outer borders, it is by their outer borders that the limbs of the siren are found to be conjoined.[1]

An abnormal direction of rotation during development will not, therefore, explain the position of the lower limbs present in genu recurvatum.

The causes, as yet, can only be conjectured.

Some cases, then, may be due to sudden accidental displacements of a limb from jolts or shocks, the malposition once brought about being subsequently incapable of rectification; others to some unusual and irregular contraction of the uterine wall during the later periods of gestation; others to a reflex adaptation on the part of the fœtus to a faulty environment which has led to want of space in some particular area of the uterine cavity, such as might arise from the growth of tumours in or about the uterus, or to diseased conditions of the uterine wall which prevent the proper degree of dilatation of a particular region or zone during gestation.

But some cases, I imagine, may be due to intra-uterine tetany, a disease fairly common in infants, and, as it affects the lower limbs, producing flexion of the toes, extension of the ankle-joint with inversion of the foot, and as regards the knee-joints, extension of these; and being a passing condition, and one marked by no recognisable lesions of the central nervous system or muscles

[1] Specimens 228, 233A, Mus. Royal Coll. Surg., show this very clearly.

Digitized by Google

concerned, no signs of it persist, except, it may be as suggested, in this unnatural position of the lower limbs; the legs once jerked up to the head, the malposition of the knees would hardly, or with great difficulty, admit of rectification.

Let it be noted, too, that tetany in a small proportion of cases is hereditary, as in those recorded by Dr. Abercrombie, 'On Tetany in Young Children, 1880,' in which there occurred at different times in each of two families, four cases, and in another family, three. This observation may be placed by the side of the case recorded by Lonsdale (loc. cit.) in which three children, born of the same mother, all presented the condition of genu recurvatum. In Wutzer's case, the malformation was observed in a father and three sons.

Although, however, heredity plays a part in congenital subluxation of the knee-joint, it has not the same significance as in the other partial or complete congenital dislocations, such as those of the hip or elbow, where the condition is in most cases due to a defective development of the articular portions of the bones. In genu recurvatum the changes in the articulation are secondary to, and not the cause of, the malposition.

It may be observed, too, that the state of tetany is not necessarily accompanied with consciousness; the spasm may persist, or it may occur for the first time during sleep. Tetany, so far as observed, is bilateral. This offers a certain amount of difficulty in applying the theory suggested to unilateral instances of genu recurvatum; unless it is that although the spasm affects both limbs, one alone happens to be forced into this particular malposition, the other being prevented by differences in the mutual positions of the lower limbs which may allow the uterine wall to contract before the displacement has been effected, and so prevent its occurrence.

In the cases recorded by Chatelain, Kleeberg, and Motte there is a history of external injury; the same is true of the second and the third instances reported in the present paper; and this amounts to about all the positive evidence adducible for the production of the malposition which brings about the deformity.

In Chatelain's case, the mother during the course of pregnancy had met with a violent fall towards the end of the seventh month.

In Kleeberg's, the mother, two months before delivery, gave herself a violent blow in the abdomen against a bed; this was

Digitized by Google

followed by great pain, and violent movements of the infant for several days.

In Motte's case, the mother during pregnancy had been accustomed, many times in the day, to carry on the left side of the abdomen one of the great saucepans in which countrywomen cook food for cattle; the child was born in a cephalic position.

In the third of the cases reported by myself in the present paper, the mother had two months before delivery fallen downstairs, striking the back and right side; the child was but seven months old when born; and in the second case there was a similar history during the middle of pregnancy.

Hibon (loc. cit.) found that in young subjects subluxation forwards of the knee-joint could not be produced after death without separation of the femoral or tibial epiphysis. There is no evidence, however, that this ever obtains in the congenital form.

Subluxation of the tibia forwards, or hyperextension of the knee-joint, is known to occur as a rare event after birth, from destruction of the joint by disease. There is a specimen of this kind, the joint being ankylosed by bone, in University College Museum, and another in St. Thomas's; in the latter instance (No. 784, Pathological Catalogue, St. Thomas's Hospital Museum), the tibia is ankylosed by osseous tissue to the femur almost at a right angle, the patella being similarly fixed to the femur at the highest part of, or above, the situation of the trochlea. This is the specimen figured in Plate IV, vol. ii, 1820, of Cooper and Travers's Surgical Essays; the case is recorded (p. 82) as having been one of white swelling; the leg was displaced forwards at right angles to the thigh, and when walking on his crutches the patient presented a most grotesque appearance, as the bottom of his foot first met the eye when he was advancing; the limb was amputated by Mr. Cline, sen., in St. Thomas's Hospital.

Finally, Albert (loc. cit.) places under the same name the hyperextension of the knee-joint which is met with in weakly children; after paralysis of the quadriceps; and in locomotor ataxy. There is a figure of the condition in ataxia given by Gowers ('Diseases of the Nervous System'). Albert explains all such cases, in which, of course, whilst there is hyperextension, there is no loss of proper flexion, as follows: In the first place the leg is thrown forwards, and the necessary fixation of the knee-joint as the body rests upon the leg cannot be effected through the

Digitized by Google

quadriceps. Hence the body falls forwards, whereby the line of gravity is carried in front of the knee-joint; the joint is brought thus into extreme extension and kept so; in time, as a consequence, it becomes over-extended as the resisting ligaments yield.

I append a list of authors who have, under different titles, recorded cases of congenital genu recurvatum. But although, as it will appear, a considerable number of instances have been observed during life (and there are many observed that have not been recorded, as one may easily gather from conversation), still very few examinations have been made of the affected parts after death; and for this reason the present communication may supply a want in what relates to this subject.

Bibliography.

A. C. Chatelain.—Quoted by Malgaigne, 'Traité de Fract. et des Lux.,' tome ii, 1855; 'Bibliothèque Médicale,' tome lxxv, p. 103, 1822.

Cruveilhier.—'Anatomie pathologique,' 2 livraison, pls. ii, iii, 1829–35.

Dr. H. Bard.—'Boston Medical and Surgical Journal,' vol. xi, p. 258, 1835.

Wutzer.—'Müller's Archiv,' 1835.

Kleeberg.—'Zeitschrift für die gesammte Medicin,' Hamburg, Bd. vi, p. 160, 1837.

Bouvier.—'Bulletins de l'Académie de Médecine,' 1837, t. ii, p. 701.

V. Ammon.—'Die angeborenen chirurgischen Krankheiten des Menschen,' Berlin, 1842, p. 114.

Lonsdale.—'Lancet,' September 4th, 1855.

Lane.—'Lancet,' vol. i, p. 63, 1858.

J. Youmans.—'Boston Medical and Surgical Journal,' October 25th, 1860, vol. lxiii, p. 249.

W. Adams.—'Club-foot,' 1864.

E. T. Caswell.—'American Journal of Med. Soc.,' vol. l, p. 82, 1865.

'Bulletin de la Société Médicale de Reims,' No. 12, p. 67, 1873.

H. Maas.—'Archiv für klin. Chir.,' Bd. xvii, p. 492, 1874.

Labbé.—'Bulletin de la Société de Chirurgie de Paris pendant de l'année 1874,' Paris, 1875, p. 508.

Digitized by Google

Motte.—"Chirurgie infantile," Mémoire publié en 'Bull. de l'Acad. Royale de Méd. de Belgique,' t. x, 3rd Série, No. 2, 1876.

W. Körte.—'Deutsche Zeitschrift für Chirurgie,' Bd. vii, p. 69, 1876–7.

J. H. Hartigan.—'Congenital Malformation of the Knee-joint.' A paper read before the Medical Society of the district of Columbia, 'National Medical Review,' February, 1879. Two cases observed by the author.

W. A. Warner.—'Cin. Med. Adv.,' November, 1879.

"*W. H. S.*"—'Cin. Lanc. and Clin.,' July 12th, 1879.

J. Guérin.—'Œuvres grand in-8°, avec atlas,' 1re livraison, p. 43, 1880.

Carl Nissen.—'Inaugural Dissertation,' Magdeburg, 1880.

Nissen refers to further cases of congenital deformity of the knee-joint, as described in Langenbeck's 'Archiv,' Bd. x, s. 743, and Bd. xii, i, p. 66.

Schmidt's 'Jahrbücher, Bd. cxii, p. 307.

'Zeitschrift für die gesammte Medicin von Dieffenbach, Ficke und Oppenheim,' Bd. vi, p. 160.

Albert.—'Lehrbuch der Chirurgie,' Bd. iv, 1880, p. 514.

Guéniot.—"Sur la luxation congénitale du genou," 'Bulletins et Mémoires de la Société de Chirurgie de Paris,' séance du 7 Juillet, 1880, t. vi, p. 442; *eodem loco*, séance du 7 Décembre, 1880.

Bertin.—*Eodem loco*, séance du 14 Décembre, 1880; et 'Union Médicale,' 14 Octobre, 1880.

Hibon.—'Thèse de Paris,' 1881; 'Luxations congén. du tibia en avant.'

R. W. Parker and *S. G. Shattock.*—'Pathological Society's Transactions,' vol. xxxv, 1884.

Bradford and *Lovett.*—'A Treatise on Orthopædic Surgery,' New York, 1890.

February 17th, 1891.

Digitized by Google

VII. DISEASES, ETC., OF THE ORGANS OF SPECIAL SENSE.

1. *Malignant polyp of the nose.*

By Arthur E. Barker, F.R.C.S.

The following case offers an example of what I believe to be a rare form of polyp of the nose, in so far as it presented many of the characters of an ordinary polyp and yet was fatally malignant. How far it should be considered a rare form of neoplasm I should not like to say, inasmuch as the characters of the growth, when taken in their entirety, present many features which are unfamiliar to me; and, after careful microscopical examination of various parts of the tumour, I am not sure what place should be given to it in the category of malignant new growths. On this point I hope for the assistance of this Society, many members of which have probably met with growths of the kind, though, perhaps, not in the nose. Personally I have only had one such tumour to deal with, and am only aware of the removal of one other like it having been recorded.

The growth from which I have prepared these sections was removed on June 22nd, 1888, from one of my private patients at my house. The lady was about forty years of age, and of fine physique. She had suffered from the usual symptoms of nasal polyp for about one year. Eight weeks previously a part of the growth was removed, but without relief; and she had come up from Suffolk for its complete extirpation.

On examination, a mass was seen nearly projecting from the left nostril. It differed but little in appearance from an ordinary numerous polyp, except that it had some hæmorrhagic spots on its most prominent surface; but, as it had been previously operated on, this fact had little significance. The mass, as far as it could be seen, was of the usual shape, and attached high up in the nose. It did not look particularly vascular, and did not bleed on light pressure.

Digitized by Google

On first seeing this growth I confess I took it for an ordinary polyp, and removed it in the usual way with forceps. But before the operation was finished it was abundantly evident that the growth was quite different from those commonly met with in this region. In the first place it broke away abruptly rather than tore; it seemed very short in the grain, so to speak, and quite inelastic. Its consistence reminded of bread soaked in white of egg. The bleeding was very free, and I was inclined to defer the removal of the deeper parts of the growth; but the patient urged me to complete the extirpation, as she could well bear it. This I did, rapidly taking away a large quantity of material in blocks and lobes, some as large as my thumb. Just as I had finished, the patient, who was remarkably courageous and cool, got a little faint, and then had a slight anæmic convulsion, which, however, soon passed off when she was laid upon a sofa. By the time she had washed her face she was quite comfortable, and she returned to her home in Suffolk on the same day. I measured the amount of blood lost during operation, and found it to be ʒxiij, exclusive of what remained on handkerchiefs and napkins.

After returning home this patient remained quite well for six or eight weeks, but not long after this recurrence took place, and by November 5th, 1888, the nostril was again blocked by the growth. Part of this was then removed by her medical man, Dr. Wallis, of Leiston, under whose care she remained until she died on February 4th, 1889, of the recurrence eight months after operation. Towards the end there appeared a large swelling on the cheek by the side of the nostril, and also in the throat. She required at the last an enormous quantity of morphia to relieve her pain, and consumed in twelve days (according to a letter which Dr. Wallis has kindly sent me recently) "336 grs., in quantities varying from 2 to 48 grs. daily." When free from pain, she was able to converse most sensibly. From this we may infer, I think, that the growth had probably not penetrated through the ethmoid bone into the brain, as I believe has taken place in one other case of apparently the same kind of which I have heard.

The growth, hardened at once in spirit, shows the following structure. It consists of two perfectly distinct tissues, one epithelial, the other connective. The first is seen in the form of tall, and in part, ciliated cells covering the surfaces of the lobes of the mass; also in separate spaces in its interior. These spaces are

Digitized by Google

often round or oval, and sometimes irregular. They do not appear to be lined by any special limiting membrane, but the epithelial cells are seated directly upon the connective tissue of the bounding stroma. The epithelial cells are packed tightly in these spaces, and are irregular in shape, but not anywhere quite columnar. In many spots one sees, in the centre of the epithelial cell-groups, rounded masses of colloid or mucoid degeneration, such as may be seen in columnar or adenoid epithelioma of the rectum. In parts of the tumour where the epithelial cell-groups are largest and most fully aggregated, this process of mucoid degeneration is far advanced, so that the hyaline rounded globules are only separated from one another by irregular rows of epithelial cells, of such varied form as almost to raise a doubt as to whether they are epithelial at all. But, by following out the process from the smaller to the larger masses of clear material, any doubt is set at rest.

The stroma consists in part of a delicately fibrillated connective tissue with elongated nuclei, and in part of almost myxomatous tissue with angular nuclei. In other parts, again, the tissue is more embryonic in appearance, numerous round connective-tissue cells being aggregated together with very little intercellular matter; while not far off the latter is abundant and structureless, with large oval nuclei scattered through it.

That this tumour belongs to the epithelial group of neoplasms I think there can be no doubt, but what exactly to call it is a matter of some difficulty. On the whole, it appears to me to approach more nearly to what has been called *carcinoma myxomatodes* than to anything else.

Report of the Morbid Growths Committee on Mr. Barker's specimen.—We have examined the sections of the nasal polypus, called by Mr. Barker "Carcinoma myxomatodes," and agree with his description.

Mr. Barker's drawings give an excellent idea of the peculiarities of the minute appearances, and we have nothing to add to his written description. It corresponds very closely with the growth described in Ziegler's pathology under the name "Cylindroma carcinomatodes."

A. A. Bowlby.
C. J. Symonds.
H. H. Clutton, *Chairman.*

Digitized by Google

2. *Nasal calculus.* (*Card specimen.*)

By Raymond Johnson.

Removed with forceps from the left nostril of a boy aged 11 years, who four years previously had accidentally pushed a locust-bean into the nose.

The specimen consists of the outer skin or testa of the bean, coated with salts to a thickness of about a millimetre. It was broken in the process of removal.

The coating consists of carbonate of lime, containing a small admixture of phosphates.

---

3. *Osteoma of temporal bone.*

By C. A. Ballance.

The patient, a married woman aged 24, was admitted to St. Thomas's Hospital in October last. The history was as follows: From the age of twelve some swelling, and occasional pain of a severe character, had been noticed in the right ear, and during the whole of this time there had been otorrhœa. The discharge had

Fig. 13.

A representation, natural size, of the osteoma described, viewed from the outer surface. The deep notch in the upper and right side corresponded with the external meatus.

latterly been very offensive and the pain unbearable. On examination, a mucous polypus was seen projecting into the concha; and beyond this the meatus was found obstructed, except at the upper

Digitized by Google

and anterior part, where a fine silver probe found a small channel which led into the deeper part of the meatus. At the operation no difficulty was experienced in removing the growth, which was attached to the bone forming the posterior inferior part of the canal. The outer surface of the osteoma was convex (see drawing), and was on a level with the rest of the surface of the temporal bone. The inner part of the bony meatus and the tympanum were enlarged, carious, and filled with inspissated pus; posteriorly the dura mater was exposed, and in front the tympanum was in communication with a large deep-seated abscess, situated in the zygomatic and infra-auricular regions. The patient made a good recovery. She said that her father had been operated on for something in the right ear. The growth was three quarters of an inch in diameter, fairly circular, and on removal a hole fully half an inch deep was left in the side of the skull.

May 19*th*, 1891.

Digitized by Google

VIII. DISEASES, ETC., OF THE DUCTLESS GLANDS.

1. *Tuberculosis of the thyroid gland.* (*Card specimen.*)

By E. C. Perry.

A microscopical section of a thyroid gland showing miliary tubercles.

Jane L—, aged 10 years, was admitted into Guy's Hospital under Dr. Wooldridge. She died of tuberculous meningitis. At the autopsy, the bronchial glands were found to be caseous, and one of them was suppurating. The thyroid gland was of normal size and appearance, except that it contained numerous yellowish-white points, the size of millet seeds. Tubercles were also found in the lungs, liver, spleen, supra-renals, and kidneys.

February 3rd, 1891.

---

2. *Tuberculosis of the thyroid gland.* (*Card specimen.*)

By Arthur Voelcker, M.D.

From three cases of general tuberculosis in children. In each, the presence of miliary tubercles is shown by microscopic examination.

May 19th, 1891.

Digitized by Google

3. *Exophthalmic goitre in a girl causing death by asphyxia.*

By W. G. Spencer.

The patient, a girl aged 20, was under the care of Drs. Ferris and Davidson of Uxbridge for a year, suffering from exophthalmic goitre. The bronchocele continued to enlarge until it caused an attack of dyspnœa, which was relieved temporarily by local measures. The bronchocele formed a large mass in the neck reaching from behind the sternum upwards, making it impossible for the patient to lower the chin.

The dyspnœa recurred, and she was sent up to the Westminster Hospital. When seen, she was sitting up in bed, gasping for breath, aiding respiration by fixing her arms, with deep cyanosis and great recession. The pulse was 170 and feeble at the wrist, although the heart was acting very strongly.

With the patient sitting up, I performed tracheotomy as quickly as I could, after having injected some cocain along the line of incision. Fortunately I had half a dozen assistants, or the operation would have been impossible. The veins on the surface of the capsule were very large. When the capsule was cut into, the gland-substance bulged out, showing how great was the tension within. The bulging mass was partly cut and torn away, and the two sides strongly retracted outwards. The hæmorrhage was greater still from the veins in front of the trachea, but I was able to clamp them all before incising the crico-thyroid membrane, the cricoid cartilage, and upper ring of the trachea. It would have been impossible to open the trachea lower down without still more hæmorrhage.

No relief followed the opening of the trachea, nor after the passage of a full-sized Parker's cannula. When a vulcanite tube was inserted for nearly 4 inches, air pressed freely through, the cyanosis and recession disappeared, and the pulse at the wrist became strong with a rate of 160 per minute. She breathed easily, and went to sleep for an hour or two, then mucus began to collect which could not be coughed up through the long tube. The house surgeon tried to shift the tube, but without success; some little

Digitized by Google

blood flowed in from the wound, and the patient died in asphyxia.

The specimen shown consists of the larynx, trachea, and upper part of the bronchi, in front of which are a large bronchocele and a persistent thymus gland. The aorta, innominate and carotid arteries, the internal jugular veins, also the vagi and recurrent nerves, have been left in position.

On looking at the specimen from the front, the bronchocele is seen to have been produced by a uniform enlargement of both lateral lobes and of the isthmus, forming a tumour more than 1 lb. in weight, after the escape of the blood and the shrinkage in spirit. The incision made during life forms a notch at the upper part of the tumour, at the bottom of which is a median incision through the cricoid cartilage and upper end of the trachea. The tumour extends from the upper border of the thyroid cartilage, the prominence of which was just to be felt during life, down into the thorax. Attached to its lower border by fibrous tissue is a persistent thymus, lying in front of the pericardium, having the appearance of, but of larger size than, the head of the pancreas.

On looking at the specimen from behind, after the removal of the œsophagus, the trachea is seen to have been compressed laterally from the larynx above to within one inch of the bifurcation below. Lobules of the growth surround the trachea and meet in the middle line behind.

At the posterior and outer aspects of the mass on each side are the carotid, vagus, and internal jugular, lying in separate grooves in the growth, the carotid being most internal, and at most one inch from the vein, whilst the nerve lies between.

The recurrents are completely embedded in the growth after their reflection.

On the right side the much enlarged superior thyroid artery is a branch of the subclavian, on the left the vessel takes origin from the aorta between the left carotid and subclavian. The sympathetic nerves and ganglia were also spread out on the back of the growth.

A cut section of the tumour shows that it is a cystic colloid hypertrophy of the thyroid gland. A section of the thymus has been made, which has the characteristic structure of that organ.

The manner of death in this patient is certainly rare in exophthalmic goitre. Many cases yield to medical treatment, or the goitre never assumes a large size. It is further of great interest

Digitized by Google

that after the removal of a large portion of the goitre in some recent cases, a cure of the disease has resulted, and such results strengthen the idea that the pathology of exophthalmic goitre is closely connected with the thyroid gland.

In conclusion, it may be asked whether the persistent thymus has anything to do with the disease. Probably nothing.

Dr. Hebb kindly examined the central nervous system, especially the medulla, but no pathological changes were found.

March 3rd, 1891.

---

4. *Substernal goitre arising in an accessory thyroid.*

By Bernard Pitts.

This specimen was removed from a man, aged 54, on January 12th, 1888.

For seven or eight years he had noticed a slight swelling just above his sternum, and this had increased rather rapidly during the last year.

He never suffered any inconvenience from it till the commencement of 1888, when he was suddenly seized with a severe fit of choking whilst taking a walk; the difficulty of breathing lasted five minutes, and greatly alarmed him.

On examination, he appeared a healthy man, with a small round swelling just visible in the median line of the neck, immediately above the sternal notch, and evidently extending behind the sternum.

On deep inspiration some stridor could be detected. He had never had any difficulty of breathing at night.

The tumour was removed by a median incision, and shelled out without much difficulty; no large vessels required ligation, but a considerable cavity was left extending for the most part behind the sternum, and was packed with iodoform gauze.

The patient made a speedy recovery, and lost all stridor.

The tumour is discoidal in shape, measuring 2 inches in diameter and 1¼ inches in thickness.

Digitized by Google

A section is placed under the microscope, and shows ordinary thyroid structure; the vesicles are dilated and filled with colloid material.

This tumour made its appearance rather late in life, and without any connection with the thyroid gland proper, the thyroid being of normal size. It probably, therefore, developed in connection with an accessory thyroid. The greater part of the tumour was behind the sternum, and the trachea was very markedly flattened from before backwards, in a manner quite unusual from ordinary goitre pressure, even when the enlargement of both lobes extends downwards behind the sternum.

Such substernal goitres are referred to by Virchow, who states that the trachea is usually thus flattened.

December 16*th*, 1890.

---

5. *Pigmented small intestines, adrenals, and semilunar ganglia, from a case of Addison's disease.* (*Card specimen.*)

By Dr. Allchin.

Specimens removed from body of female, aged 29, single, a cook, who died in the Westminster Hospital from syncope, eleven days after admission.

A typical case of Addison's disease, the symptoms of which commenced five years ago with vomiting, increasing muscular weakness, necessitating giving up work for the past eighteen months. Pigmentation only noticed during past twelve months. The bronzing of face and hand was most extreme, rather less so in arms, neck, axillæ, and legs, and very slight on abdomen and thighs. A few streaks of pigment in buccal mucous membrane.

The mucous membrane of the small intestine for the greater part of its length shows tracts of pigmentation, some several inches in extent. Microscopic examination by Dr. Hebb shows the pigmentation to be in the mucosa, but it is quite obvious from the peritoneal surface. Gullet, stomach, and colon quite free from

Digitized by Google

pigment. The intestines were matted together by old adhesions, thin but firm, at the edges of which there was much pigmentation of the peritoneum.

Adrenals caseous. Right measures $2\frac{3}{8}$ by $2\frac{1}{8}$ inches; left, $2\frac{1}{8}$ by $1\frac{3}{8}$ inches; and each is about $\frac{3}{4}$ inch thick.

Semilunar ganglia large and thickened on the right side, thin and wasted on the left. Thoracic and abdominal aorta notably constricted throughout. *May 19th*, 1891.

Digitized by Google

IX. DISEASES, ETC., OF THE SKIN.

1. *Rodent ulcer of scalp.* (*Card specimen.*)

By H. H. Clutton.

The specimen comprises the posterior part of the skull and scalp, with a portion of the brain beneath. The area of disease measures 5 inches in length by 3 inches in its widest part. The bone is destroyed over most of this area, except for a transverse ridge about its middle. In the centre of the posterior of the two spaces is a rounded projection ⅛ inch above the rest of the surface, which a section shows to be a hernia cerebri protruding through an aperture of the dura mater.

This section also shows a comparatively thick layer of new growth adherent to the outer surface of the dura mater, but with the exception of the spot before mentioned the dura mater was not perforated and not adherent to the brain beneath, which was quite free from growth or inflammation. There were no secondary growths in any part of the body.

History.—Woman, aged 69 at time of her death, 1889, who had had an ulcer of the scalp for nineteen years, commencing in a "birth mark" which was injured by a comb.

First operation (August, 1880).—Ulcer removed and proved to be rodent ulcer. Chloride of zinc paste applied, and bone subsequently removed by necrosis.

Second operation (January, 1881).—Ulcer removed, and chloride of zinc applied; bone, measuring 2½ inches by 2 inches, subsequently removed by necrosis; cicatrix, which healed by May, 1881, measured 4½ inches by 2½ inches.

Third operation (September, 1884).—Two round nodules at margin of scar removed, and chloride of zinc applied; bone came away in October.

Digitized by Google

FIG. 19.

A vertical section of the rodent ulcer described in the text. For a distance of about two inches above the hernia cerebri the bone is entirely wanting, and is replaced by a thick layer of the new growth which lies on, but does not perforate, the dura mater, and forms the floor of the ulcer.

Digitized by Google

Fourth operation (March, 1885).—Removed ulcerated part which had never healed since last operation; dura mater exposed and scraped—healed in July, 1885.

Fifth operation (August, 1886).—Removal of nodules in crumbling bone at the margin; chloride of zinc to bone.

Subsequently pulsating dura mater was more and more exposed by crumbling fragments of bone coming away. The growth seemed always to extend in the bone without destroying the parts beneath.

A drawing made in 1888, shows the manner in which the nodules of growth formed in the bone at the margin of the old cicatrix.

The interest of this case lies in the fact that the dura mater was exposed for six years before death, that its outer surface was covered with growth, and yet with the exception of one small area it was neither perforated nor adherent to the brain beneath.

April 21*st*, 1891.

---

2. *Carcinoma of scalp.*

By S. Paget.

From a gentleman, aged 75. The growth had been observed for about four years; it had at first presented the appearance of an ordinary sebaceous cyst. During the last the growth had increased more rapidly, and had broken down in the centre. General health good. The growth had never been painful. There was no enlargement of the lymphatic glands.

The growth was on the left side of the forehead, its lower margin being about two inches above the orbit. It was circular in outline, with a diameter of $1\frac{1}{2}$ or 2 inches. It was just moveable on the bone beneath, but not freely moveable. It was firm and tough; a smooth, even convex surface, raised quite half or two thirds of an inch above the level of the scalp; the skin thinned, adherent, and discoloured over it. Centrally, the growth had broken down, forming a deep hole, with edges abrupt above and undermined below; at the bottom of the hole were coarse, tough granulations,

Digitized by Google

emitting a scanty offensive discharge, not vascular, closely adherent to the bone. The bone was nowhere quite bare.

I removed the growth very freely, leaving only the periosteum, and exposing and scraping the bone beneath the central part of the growth; the bone here was somewhat thickened and lumpy, but not soft or carious.

The under surface of the growth showed the same ring-shaped elevation as the upper surface, so that the whole growth had somewhat the shape of a ring-pessary, with a central mass of granulations.

The patient did well; the wound was very large, but it all healed at last; the central exposed bone granulated slowly, without exfoliation. The wound was well grafted.

April 8th, 1891.

Report of the Morbid Growths Committee on Mr. Stephen Paget's crateriform ulcer of the scalp.—The specimen consists of a nodular boss, devoid of epithelium on the surface, exposing an elevated ring of irregular, rounded papillary projections, surrounding a central crater-like cavity, about 1½ inches in diameter.

The healthy cuticle presents a well-defined ragged edge, through which processes of growth have burst. The edge is in places slightly everted, and in others undermined.

Microscopically, the skin up to its ulcerated border, which overhangs the growth, presents no proliferative changes. The growth consists of a collection of alveoli crammed with cells similar to those of sebaceous glands; the cells in the centres of the large alveoli have more or less completely degenerated into granular masses, but these have nowhere undergone corneous changes, and no cell-nests are present.

The central degenerated masses are in part sharply defined from the still living cells, which occupy the peripheral portion of the alveoli.

In the superficial part of the growth the alveoli are large and closely packed, forming the processes which project from the surface. Deeper down the alveoli are for the most part smaller, more numerous, and show less degeneration; in many places these can be traced to the larger masses, from which they appear to have budded.

Below this, the proliferating connective tissue predominates.

Digitized by Google

Small groups, of irregular forms and various sizes, of epithelial cells are embedded in this; the larger ones show degeneration in their central parts; in form they are mostly tubular. There is no network of cell-columns which can be said to be certainly indicative of lymphatic infection.

The connective tissue between the alveoli at the free surface, and also some of the alveoli themselves, are ulcerating away. At one spot on the surface there is an oblique section of a hair follicle, in the neighbourhood of which there is much cell infiltration.

At one margin of the growth there is an apparently normal hair follicle, surrounded by inflamed connective tissue, and adjacent to its lower part there is a normal sweat-gland.

At the outer border the growth is well defined, as if it were limited to the sebaceous glands connected with certain hair follicles, but it is not encapsuled. The appearances are those of an active proliferation of the sebaceous follicles over a circumscribed area, with budding processes projecting deeply into the corium and subcutaneous tissue, with compression and destruction of the covering skin, but without invasion of either the cuticle or the sweat-glands.

There is no keratoid change, nor is there any evidence that the growth is connected with the Malpighian layer.

The freedom of the epithelium, covering the adjacent undermined surface is a noteworthy feature.

G. Newton Pitt.
F. Charlewood Turner.
H. H. Clutton, *Chairman.*

---

3. *Carcinoma following lupus of face.* (*Card specimen.*)

By James Berry.

Male, aged 45. History of lupus at age of 15—"cured in six months," but "face always remained red." Two months ago face began to swell, and nine days later ulceration commenced at right side of upper lip, near ala of nose. Treated with cold

Digitized by Google

water applications; the ulceration rapidly spread, and on January 22nd, 1891, patient came to the Royal Free Hospital.

There is no history of syphilis, and anti-syphilitic remedies have had no effect as yet. There is one enlarged gland in the anterior parotid region. The disease has extended visibly in the last few days.

February 3rd, 1891.

---

4. "*On a supposed case of indigenous leprosy*" [*really carcinoma*].

By P. S. Abraham, M.A., M.D., B.Sc., F.R.C.S.I.

In the month of May, 1890, paragraphs went the round of the daily sensational Press to the effect that a case of indigenous leprosy had been discovered in Warwickshire, and that there was no doubt whatever as to its being an example of true Eastern leprosy, because it had been so certified to be by doctors.

A few weeks afterwards, the vicar of the parish, wherein dwelt the supposed leper, wrote to the Honorary Secretary of the "National Leprosy Fund," with the request that a medical man conversant with leprosy be sent to examine the case, and advise what should be done under the circumstances; for there was naturally much alarm felt in the neighbourhood, and there was difficulty even in obtaining the services of a nurse for the invalid. I was then requested to visit the patient, and this I was enabled to do, thanks to the courtesy of the Rev. Beresford Potter, and of the local practitioners, Messrs. R. and R. J. Pitt.

The note which I made at the time of my visit is as follows:

"*Present condition.*—The patient, an old woman, is lying in bed, apparently in much pain, and in so great a state of nervous excitement that a thorough examination is most difficult. The atmosphere of the whole cottage is very offensive, and almost insupportable in the room itself—the evident cause being defective dressing.

The face, body, and limbs are greatly emaciated. The left arm exhibits a large fungating growth about the region of the elbow,

Digitized by Google

above which the arm is much enlarged, with the integument œdematous; the skin of the forearm is thick and brawny, scarred in several places, and mottled with large and small patches of dark brownish discoloration. The hand is swollen and œdematous, the fingers somewhat flexed, with some of the terminal phalanges apparently gangrenous, and the nails thick and overgrown. The ungual phalanx of the little finger has been lost by ulceration. The hand is warm, and there is some power of movement of the fingers. Sensation does not seem to be much affected, for when the back of the forearm, the hand, or the fingers, are lightly touched, the patient, with eyes averted, is aware of the fact. No enlarged glands could be felt in the axilla, but as the slightest movement of the arm gave pain, a complete investigation into this point could not be made.

"The other extremities, and the skin of the rest of the body, show no spots, patches, or any disease whatever. Every other part, but this arm and hand, is now, and—according to the patient—has always been, perfectly clear and healthy.

"*History.*—The patient states that about thirty years ago she noticed a growth 'like a bean' on the forearm—the skin subsequently becoming scaly and thick around, and that the latter condition gradually extended downwards towards the hand, and upwards towards the elbow. The swelling of the limb came on comparatively recently; and the cauliflower-like mass about the elbow appeared only some two months ago. Her general health has always been good, with the exception of occasional attacks of indigestion. Her family history is good, and she has never known or seen any one with a disease of the kind. She was born at Coventry, and has never in her life been out of Warwickshire. She is the wife of a labourer, who at one time—many years ago—used to go about the neighbourhood buying and selling rags and refuse. Her age is sixty-nine."

Mr. Pitt, senior, has been kind enough to furnish me with some further details in reference to the history, &c., of the case. Her father died of apoplexy at the age of 75 or 76; his children were all healthy. Her mother died from an injury to the knee, aged 42. The patient is the mother of two sons, both living and healthy, and she has had two still-born children. The husband commenced dealing in rags and bones about thirty years ago, but although the woman has often been questioned very carefully on

Digitized by Google

the subject, it cannot be clearly made out whether the disease appeared before or after the rag and bone business was entered upon. Mr. Pitt's impression is that it was after. The patient had always steadily refused treatment for her arm, and it was only lately that she allowed the doctor even to see it.

As may be supposed, I strongly urged the poor woman to go to a hospital or infirmary, where she could be properly looked after, and possibly relieved by operation of her useless and painful limb; and in this I was heartily supported by Mr. Pitt and the vicar; but she point-blank declined, saying that she was going to die in her own bed—as she did, in fact, a few weeks after I saw her. No *post-mortem* examination was permitted; but after persuading, by a substantial method, the husband to give his consent, Mr. Pitt was good enough to excise and send to me by parcel-post the specimen which is exhibited here to-night.

The day after its arrival this very excellent drawing of it was made by Mr. Burgess, and it gives, to a certain extent, a fair idea of the appearance of the member during life.[1] The œdema of the skin had, however, entirely disappeared, and the fungating growth at the elbow had become very much shrunken. The mottled discoloration of the skin and the claw-like appearance of the fingers are particularly well shown; but the skin in life was not so rugose and nodular as represented in the drawing.

It was no doubt in a great measure due to these last-mentioned characters that the idea of the case being one of leprosy arose. The hand, indeed, with its clawed digits and ulcerating phalanges, one of which had actually dropped off, bears a superficial resemblance, at least, to the hand of many a leper; and, moreover, Mr. Pitt informed me that on a previous visit which he had made, there seemed to be anæsthesia of the skin of the hand.

The absence of all other signs of the disease, however, as well as the history of the case, make it quite clear to my mind that it has nothing whatever to do with leprosy; and this opinion has been confirmed on microscopical examination.

Sections have been taken from the growth at the elbow, from a small raised patch on the skin some inches above the tumour, from one of the discoloured scars and from another spot on the forearm, and from the ungual phalanx, which had ulcerated off, and had fortunately been preserved in spirit by Mr. Pitt. I have examined

[1] This is now in the Collection of the Royal College of Surgeons.

Digitized by Google

sections from all these places for the bacilli of leprosy, but, naturally, none have been found. The growth at the elbow is a rapidly proliferating, succulent, epithelioma. The cells are very large, the largest, indeed, that I ever remember to have seen in in such a neoplasm; many of the nuclei are in process of karyokinetic division; and there are numerous cell-nests. Occupying the centre of some of these are large protoplasmic masses, reminding one of the psorosperms figured by M. Wickham and others, but of which at present I have no practical knowledge. I have seen similar appearances in other sections of epitheliomata, and have always taken them to be merely young epithelial cells before division.

There is a considerable amount of inflammatory small-celled nfiltration between and among the anastomosing prolongations and masses of epithelium. The sections from the small raised patch on the arm show commencing epithelioma, as do those from the spontaneously amputated ungual phalanx. In some of the latter sections, there is, beneath the epidermis and its "increscences," a granuloma-like formation, containing a few multinuclear giant-cells, such as one may find in lupus; and a similar structure is observable in sections taken from the skin of the forearm. This fact, indeed, tends to support a suggestion of Mr. Hutchinson, that the disease in this case possibly commenced as a superficial lupoid ulceration, scarring over at the spot first attacked and spreading at the edge, and that the epithelioma has been a secondary development. The cancerous growth at the elbow may have commenced in a gland, but it seems to me more probable that it started from the epidermis. It had eaten quite into the joint, which appears to be altogether disorganised, but no dissection of it has yet been made.

Apart from whatever pathological interest the specimen may possess in itself, and this interest I fear has been greatly diminished by the imperfect manner in which I have been able to present it, the case appears to me to be worthy of notice, if not instructive, from another point of view. Had the patient succumbed a few weeks earlier, we should, no doubt, have had to quote her in future as a possible case of indigenous leprosy; and the literature of that disease would have been still further complicated, and our subsequent etiological inquiries confused by another doubtful record.

Digitized by Google

Report of the Committee appointed to examine Dr. Abraham's specimen.—We have examined Dr. Abraham's case of supposed indigenous leprosy, and agree with him in considering it to be one of squamous-celled carcinoma.

W. WATSON CHEYNE.
G. THIN.
EDGAR CROOKSHANK.

Digitized by Google

X. MORBID GROWTHS.

1. *Two cases of dermal cyst of finger.*

By E. C. Stabb.

Case 1.—Cyst removed from palmar surface of terminal phalanx of right index finger of a blacksmith, aged 30. Two years previously he ran a piece of iron into the finger, which bled at the time, but healed in about a week. Four months afterwards he first noticed a small swelling at the site of the injury, which gradually increased in size, and was an inconvenience to him. It was punctured by a doctor, and creamy matter squeezed out, on two separate occasions, but the swelling returning, he desired to have something more done. The cyst was removed by an elliptical incision, including a piece of skin to which it was adherent; it was firmly connected to the tendon sheath by fibrous tissue. There was a delicate connective-tissue capsule outside the cyst. The cyst itself was thick-walled, rounded, a third of an inch in diameter, and white in colour.

Microscopically the cyst wall proved to be composed entirely of epithelium, the outer layers being nucleated, and presenting a well-marked granular layer, the inner being composed of squamous cells, showing no nucleus, and apparently corresponding to the free surface of the epidermis. The cyst contained broken-down epithelial cells, and granular matter.

Case 2.—Cyst removed from palmar surface of second phalanx of right middle finger of carman, aged 23. Nine months previously he crushed his finger between two casks, lacerating the skin, which healed in a few days. About five months after this he found he could not completely flex his finger on account of a small swelling, which gradually increased in size up to the time of removal. The

Digitized by Google

cyst, about half an inch in diameter and rounded, was not adherent to the skin or tendon sheath, and shelled out readily. To the naked eye, and microscopically, it presented the same characters as the previous one.

The point of interest in these cases lies in the fact that, in each, the development of the cyst appears to be directly consequent upon an injury to the part of such a nature as to carry some of the epidermis into the deeper tissues. *January 6th*, 1891.

---

2. *Sebaceous carcinoma of face.*

By H. Betham Robinson.

(With Plate IV, Fig. 2.)

The above tumour is a recurrent growth from the case of "Epithelioma of the lower Eyelid," described by me in the last volume of the 'Transactions' (vol. xli).

The original tumour was removed from a man, aged 72, in December, 1888. It had been growing one year, and was of a "beehive" shape, and quite free on the deep tissues. There were no enlarged glands.

The growth, microscopically, showed a squamous-celled epithelioma mixed with a considerable quantity of vascular granulation tissue. The epithelioma was of an unusual type in that the cells never advanced beyond the spheroidal shape, and in the growth there were a few ill-defined epithelial nests without corneous centres.

Clinically, the tumour was allied to the "crateriform ulcer" of Mr. Hutchinson, and I suggested that it was possibly an epithelioma starting in one of the skin appendages.

The specimen was referred to the Morbid Growths Committee, and they reported on it as follows:—"We do not find any true nests or pearls; there are collections of large epithelial cells having a concentric arrangement, but this seems determined rather by the site in which the cells are found than upon any inherent peculiarity

Digitized by Google

in the growth. . . . . There appears to us to be no reason for regarding this (the granulation tissue) as other than the altered connective tissue of the skin. There is everywhere, in glands, hair follicles, and in the connective tissue, evidence of proliferation, all of which we would attribute to the effect of the epithelial growth and the attendant suppuration. . . . In conclusion, we are of opinion that the specimen is one of squamous-celled carcinoma, modified by the situation and by the suppurative process."

The patient again came to me at the end of January, 1891, with a tumour in the left parotid region, which first appeared four months before. There was no recurrence at the original seat of disease.

A small swelling arose four months before in the situation of the pre-auricular glands, and it was removed in the country. The growth, however, recurred very soon, and on admission it was filling up the region between the ramus of the jaw and the pinna. The skin was adherent to it, and of a purplish-red colour. The tumour felt elastic and did not seem very deeply fixed. There were no other glands enlarged. The growth was removed on February 5th. The facial nerve ran through the tumour, but this was dissected out, and, although after the operation there were signs of weakness of the face muscles, when he left the hospital on February 16th there was not the least evidence of facial paralysis. The tumour was very soft, being easily broken down with the finger.

As this growth was not accompanied by suppuration, the histological appearances have been easier to determine than in the original growth.

Microscopically, the tissue is seen to be arranged in columns and alveoli, the latter apparently being transverse sections of the former. The masses of epithelium are separated by connective tissue, which shows a well-marked round-cell infiltration in places. The epithelial masses show the following structure: Next the connective tissue the cells are columnar or cubical with well-marked nuclei. From the periphery to the interior the cells get more spheroidal, so that in the centre they are very swollen and loosely connected, and their protoplasm is granular and their nuclei are not so well stained. In the centre of some of the cell masses is a granular material arising from cell destruction. There are no true epithelial nests to be seen, and in a few places the enlarged epithelial cells have somewhat a concentric arrangement.

Digitized by Google

The structure of the tumour shows a marked likeness to that of a sebaceous gland. From the absence of birds'-nests, and from the epithelium never becoming scaly, it certainly is not like an ordinary squamous carcinoma, and it is doubtful, if even it does not arise from a sebaceous gland, whether it should belong to this group. I have called the tumour a sebaceous carcinoma, and I would include it among the glandular rather than among the squamous carcinomata. *April 7th*, 1891.

---

3. *Columnar-celled carcinoma involving the lower jaw.*

By H Betham Robinson.

The specimen, described below, was removed from a man, aged 49, by Mr. Sydney Jones, on October 18th, 1889.

There was no history of tumour formation in the family, and the man himself had previously enjoyed good health.

About ten weeks before admission into the hospital he had a blow from a horse on the right side of the lower jaw, and there was a little bleeding from the mouth at the time; there was no wound of the skin. Three weeks after he had a little pain in the same region, which then was noticed to be swollen. Five weeks before admission he began to poultice it, and after a few days it was incised, but only blood escaped. From this time he continued to poultice it, but it increased in size and became very painful.

On admission he was healthy-looking. There was a swelling about the size of an orange on the outside and below the lower jaw. The skin over the swelling was red, thickened, and adherent, and at two or three spots there were signs of breaking down; there was some dark coloured discharge from an opening in the skin about the centre of the tumour. The swelling itself felt hard, except in the centre, and it appeared to be continuous with the jaw. The swelling was situated on the outer side and below the jaw, extending nearly to the mid line, and back to the anterior border of the masseter; it could also be felt on the inner side of the jaw beneath the mucous membrane, extending up almost to the reflexion of mucous membrane. There were no enlarged glands.

Digitized by Google

The jaw was removed from the mid line to the second molar tooth.

Death took place two days afterwards from pneumonia, and at the autopsy this was the only lesion discovered.

On section the tumour is seen to be rounded with a fairly well-defined outer edge, and to be wrapping round the lower border of the bone. The bone itself is not expanded; its outer surface is, however, eroded by the growth. The tumour has a fibrous appearance, and scattered through this are small cysts, none larger than a pea, with smooth lining. It resembled very much a periosteal sarcoma.

On microscopical examination there is to be seen a fibrous stroma with extensive round-celled infiltration. Embedded in this are epithelial masses arranged in a lobulated manner. On the outside of these masses the epithelium is columnar, but towards the central part the cells become spheroidal. In some places there is a cystic condition of these cell groups produced by cell degeneration, and in these the cells lining the interior of the cavity are flattened, probably from pressure. There are no epithelial nests to be seen. The soft tissue in the interior of the bone shows no growth at all, only a little inflammatory round-celled infiltration, and from this, coupled with the non-expansion of the bone, we can say definitely its origin is not central.

Remarks.—This tumour strictly, I think, is not one "of the lower jaw," but "involving the lower jaw." Of one like it I can find no record in surgical literature, but it bears some likeness histologically to some of the cystic tumours described by Mr. Eve in his lectures at the Royal College of Surgeons in 1882. It resembles rather closely a large tumour of the lower jaw therein mentioned, which had been removed by Mr. Heath. There a tumour had been present for some years, which had increased rapidly after a blow. It is not mentioned whether the jaw was expanded, but its account states that small cysts and nodules of bone were distributed through a tumour having a marked likeness to a fibro-sarcoma. Histologically this rather agrees with my specimen, except that the connective tissue is not here embryonic.

As to the origin of this tumour, it must have started either from one of the skin appendages or from some epithelial remnant in relation with the first branchial bar. If, from the latter, which seems the more probable, there is good reason for its resemblance to certain

Digitized by Google

cystic jaw tumours which may arise from similar remnants embedded in the maxilla; and, again, we know that curious cystic epitheliomata arise in the neck lower down, whose origin can only be attributed to similar remnants in relation with the lower arches and clefts.[1]

The only other point worthy of notice is the rapidity of the tumour formation, dating from the injury three weeks before. This history only excites one suspicion, as to whether the injury was the exciting or attracting cause, the latter seeming the more probable from what we know of the rate of growth of similar tumours elsewhere. *May* 19*th*, 1891.

---

4. *Intra-cystic carcinoma of pectoral region.* (*Card specimen.*)

By Edgar Willett.

The tumour, which was about the size of a walnut, was removed by Mr. Thomas Smith from the pectoral region (just below the right clavicle) of an elderly lady, who had noticed its growth for four or five years, during which time it had slowly increased in size.

Under the microscope it shows two structures which are quite distinct in certain places, but which gradually merge the one (1) into the other (2).

(1) Here, the structure (? primary) consists of a number of branching processes, composed almost entirely of glandular cells, which are held together by a faint stroma; amongst these processes are irregular spaces, which may, perhaps, have been blood-channels, but which do not possess any definite lining epithelium; sets of these processes are collected together into groups more or less circular in shape, and these are surrounded, for the greater part, by a well-defined capsule of fibrous tissue; this arrangement gives the appearance of a compound papilloma protruding into a cyst.

[1] *Vide* Treves, "Malignant Cysts of Neck," and Quarry Silcock, "Cystic Epitheliomata," 'Trans. Path. Soc.,' vol. xxxviii.

Digitized by Google

(2) Here the structure (? secondary) consists of large groups of spheroidal glandular cells, collected into spaces, which are formed by a network of fibrous tissue (*i. e.* encephaloid carcinoma), but here the fibrous meshwork occupies as much of the field as do the groups of cells, whereas in most situations in (1) little if any fibrous tissue can be seen except at the periphery, as stated above.

It seems probable that the tumour originated in an out-lying and separate portion of the mammary gland: the latter itself was not affected, nor were the axillary or supra-clavicular lymphatic glands. *December* 16*th*, 1890.

---

5. *Mediastinal carcinoma secondary to scirrhus of the pancreas.* (*Card specimen.*)

By H. D. Rolleston.

The superior mediastinum was occupied by a large firm growth, which overlay the great vessels and upper part of the pericardium, and posteriorly compressed the trachea and bronchi by involving the bronchial glands.

The growth compressed both innominate veins and the superior vena cava to such an extent that a probe could only be passed with difficulty. The pulmonary artery was compressed, but especially its right division. The aorta and the branches arising from the arch were surrounded by growth, but were not narrowed to any appreciable extent. Both vagi were involved in the growth. The trachea just above the bifurcation and both bronchi were compressed and infiltrated by new growth which projected into their interior.

Passing along the right bronchus the growth had begun to infiltrate the upper lobe, and had bound the apex down to the chest-wall. The growth had projected into the pericardium to the right of the superior vena cava.

There was a hard lump in the pancreas towards the splenic end; the head was not implicated.

On microscopic examination the growth in the pancreas was seen to be a scirrhus. The mediastinal growth was composed of

Digitized by Google

columnar epithelial cells having at first sight somewhat a tubular appearance, but showing no lumen. The columnar cells were imbedded in lymphoid tissue. In parts there were well-formed and extensive tracts of fibrous tissue which had no reticular arrangement, and were probably independent of the new growth. No concentric corpuscles of Hassel were seen.

The scirrhus in the pancreas was regarded as the primary growth, and the mediastinal tumour as a secondary carcinomatous growth involving the bronchial and anterior mediastinal glands.

The points of interest are the unusual site for a new growth in the tail end of the pancreas, and the large size of the secondary growth in the mediastinum, which alone gave rise to any symptoms during life.

The specimen was taken from a man, aged 33 years, who died in St. George's Hospital with symptoms of obstruction of the bronchi, under the care of Dr. Dickinson. *January 20th*, 1891.

---

6. *Melanotic sarcoma, very widely disseminated.*

By John Cumming Mackenzie, M.B., communicated by G. Sims Woodhead, M.D.

The chief interest of this case lies in its pathology. The clinical record, although probably disappointing as an aid to the obscure symptomatology of new growth, emphasises the difficulty in diagnosing the disease in deep-seated organs so imperfectly amenable to examination by our present methods. In the light of the *post-mortem* examination, however, the following record, such as it is, may be made to acquire a value which it did not before possess.

J. Y—, male, aged 75, gardener, admitted to the County Asylum, Morpeth, 26th January, 1885. The medical certificate on which he was admitted states him to be violent from hallucinations of hearing. He says there are men up the chimney talking about him, and he tries violently to dislodge them with the poker. Of recent years he might be called a tramp, with no fixed habits, and living as he best could. His son, a strong able-bodied hypochondriacal melan-

Digitized by Google

choliac, was at the time a patient in this asylum, but is since discharged recovered.

On the day following admission, the patient is noted as quiet and seemingly stupid, probably in part due to his impaired hearing. He gives a fairly good account of himself, and he is not at all excited. He says that he was last night in a coach that jolted terribly, that he heard steam whistles blowing, and that men knocked him on the head. He is of medium height, fairly nourished, but not very muscular. His left eye is the seat of a recent iritis, and he complains of pain in the head and over the right hip and buttock. There are no marks or other signs of injury apparent anywhere. The lungs seem normal, but the heart's action is feeble. Pulse 84 and regular, and temperature 96·8° F.; of the gastro-intestinal function there is no complaint.

The eye was treated with an occasional drop of atropine solution, and on the 2nd February it is noted as improved in appearance and free from pain. He now complains of people tapping on his bedstead during the night to annoy him, and of hearing all sorts of unnatural noises.

February 8th.—The left eye is becoming disorganised, and he can scarcely distinguish light from darkness with it.

14th.—He is up daily, but seems like one suffering from chronic arthritis, with a difficult and halting progression, but would usefully employ himself if he could. Enjoys life in a quiet way, but never speaks unless spoken to.

March 8th.—Much pain in the diseased eye, and vision still impaired.

22nd.—He now expresses no delusions and may be called a harmless dement.

August 11th.—Occasional pain, but constant stiffness in the region of the right hip.

November 5th.—Intense chemosis of the conjunctiva of the lid and globe of the left eye, severe sharp pains, great redness, swelling, and vision entirely destroyed. He is given quinine internally, and the eye is bandaged with a dry compress.

December 3rd.—The eye is free from pain and the chemosis subsided, but the whole surface of the cornea is one large greyish-white opacity, except at the lower zone, where a bluish-black colour shines through. On palpation the globe is firm and hard, but freely moveable in the orbit and apparently not enlarged.

Digitized by Google

August 5th, 1886.—Mentally he is unchanged, appetite fair, but weight two pounds less than in January. There are frequent exacerbations of pain and hyperæmia of the conjunctiva of the affected eye. The pain over right hip continues.

January 5th, 1887.—Weight 4 lbs. less than in August, but appetite continues fair. He is up daily, but too stiff and shaky to move about much.

July 20th.—Weight 139 lbs., 3 lbs. less than in January.

October 7th.—He is resting in bed, and complains of pain and tenderness over the area of the liver, dulness in front, but spreading slightly over the whole abdomen. Appetite poor, and bowels constipated.

January 16th, 1888.—Since date of preceding note, he has been almost constantly in bed, complains still of the tenderness already mentioned, and localising its intensity to the right side of the chest and epigastrium, on which even the weight of the bed-clothes is unbearable. The appetite varies, and there is considerable retching after every meal, and frequently vomiting.

The skin of the face and conjunctivæ are bile-stained. The stools are pale, and he never has a motion without an aperient. Every movement of the body, even the exertion of answering a question, seems to give him pain.

20th.—Since last note he takes whatever is given to him, but vomiting is now invariable. The heart's action is somewhat irregular and very feeble. The skin is cold and clammy, and of a dirty-sallow hue.

22nd.—He died at twenty minutes past ten o'clock last night.

Post-mortem examination.—Body somewhat emaciated. No bed-sores. Lividity very faint. Considerable bile-staining of the conjunctivæ and skin generally, especially that of the face, which is markedly jaundiced. In the deeper layers of the skin, or more probably subcutaneous, there are here and there firm, elevated, circumscribed nodules of a yellowish-white colour as they appear through the skin, but dark-brown or black on section, and varying from the size of a pin's head to that of a large pea, freely moveable, and to the touch apparently lying subjacent to the surface. They are most numerous in the skin of the chest-wall and abdomen, while there are apparently none in the scalp, skin of the face, hands, or right leg, but one about the size of a large pea over the subcutaneous surface of the left tibia, freely moveable, and not at

Digitized by Google

all adherent to the bone. The left eye is shrivelled up and disorganised.

Head.—The scalp is firmly adherent to the skull, which is hard and dense and of a somewhat uniform and apparently normal thickness. Along the line of the longitudinal suture the bone dips about a quarter of an inch crest or ridge-like between the hemispheres. Dura mater thickened and firmly adherent to the bone. Pia mater opaque and also thickened, but strips readily. Brain weighs 48 oz., but about 2 oz. yellow-stained fluid escaped on its removal. Left optic nerve atrophied to almost half the size of the right. On section the brain substance is firm, but the grey matter atrophied and pale. Lateral ventricles contain a trace of yellow-stained fluid. All the vessels are hard, patent, and exceedingly atheromatous. No signs of softening or clot, and the empendyma, to the naked eye, is smooth.

Thorax.—The pericardium contains about a teaspoonful of yellow-stained fluid. It is adherent to the left ventricle near the apex by a loose band of fibrous tissue. Under the endothelial covering of the sac, on its inner surface, there is here and there a firm, flattened, circumscribed greyish-black nodule, larger than a split pea.

Heart weight, 9½ oz. There is a firm, greyish-black nodule about the size of a flattened bean, and a few of smaller size on the outer anterior surface of the right ventricle, and a few pin-head specks on the other surfaces. All the cavities contain partially decolourised clots, the aortic valve is incompetent, and the heart's substance soft and flabby. Left side: There are a few calcareous concretions over the valve segments and commencement of the aorta, and a shiny one the size of a pea near the insertion of the anterior segment of the mitral. There is also considerable atheroma of these parts. There is a black, firm nodule the size of a pea on a papillary muscle, under the endocardium, and many smaller ones scattered throughout this cavity. There is a greyish-black nodule the size of a bean in the posterior wall of the left sinus venosus. Right side: In the cavity of the right ventricle, on its anterior surface, there is a black, firm nodule the size of a hazel-nut, and a few, from the size of pin-points to small shot, scattered throughout this cavity. The papillary muscles in their whole length are sprinkled with small black specks, but the valves are free. There is a focus of larger-sized and numerous smaller ones on the surface of the septal wall,

Digitized by Google

opposite to, and probably when *in situ*, touching the larger mass on the anterior wall.

The surface of the cavity of the right auricle has here and there a black speck the size of a No. 5 shot. Besides these there are black specks embedded in the cardiac muscle. Left lung weighs 16 oz., and is adherent to the chest-wall at the apex. No fluid in the interpleural space. The visceral and costal pleuræ are studded with dirty-white or greyish-black, firm, circumscribed, warty-looking nodules, from the size of a pin-head to that of a large pea. These are sometimes met with in clusters of a few together. On section these are seen everywhere throughout the lung substance. There is seen here and there in the walls of the left pulmonary veins a firm, flattened, greyish-black or dirty-white nodule about the size of an almond.

Right lung weighs 27 oz. It is densely adherent to the chest-wall and consolidated at the base. The pleuræ and lung substance are nodulated somewhat similar to the left.

The peribronchial and mediastinal lymphatic glands are coal black, but not apparently enlarged. Some are indurated, but others on section exude a gelatinous, dark, glairy material. Both surfaces of the diaphragm are studded with bodies as seen in the lungs.

Abdomen.—Liver weighs 129½ oz. It nearly fills the whole of the upper part of the abdomen, overlapping the stomach, and reaching to below the umbilicus.

The gall-bladder contains about 1 oz. of dark viscid bile, but no concretions.

The surface of the liver is nodulated, but smooth. On section it is friable, and presents a coarse, granite appearance, as if made up altogether of firm circumscribed nodules, varying from a greyish-black to a dirty-white, and from the size of a millet-seed to that of a hazel-nut. Towards the periphery of the organ they are of a darker shade. The capsule is not thickened, but its surface, ligaments, wall of the gall-bladder, and common bile-duct have here and there clusters of black, firm, pedunculated, seal-like bodies, from the size of pin-points to that of split-peas.

Pancreas looks ragged and atrophied, and is thickly studded with rounded and flattened greyish-black, solid, circumscribed nodules varying from the size of hazel-nut to that of a pin-point. On section they are cheesy-white, and most numerous and largest in and about the head. They invade and narrow the lumen of the duct.

Digitized by Google

Spleen weighs 8 oz. It is red, soft, and friable. Its capsule is studded here and there with clusters of greyish-white specks, from the size of a No. 7 shot to that of a pin-point.

In the areolar tissue in and surrounding the hilus they are black. There is here and there in its substance a white, firm, fatty-looking, circumscribed nodule, about the size of a cherry, but near the surface, and giving prominence to the lower end of the anterior border, is one the size of a pigeon's egg.

Supra-renal capsules feel hard and gritty, and on section are full of firm, greyish-white bodies, about the size of a No. 5 shot and smaller.

Left kidney weighs 5 oz. On its surface, there is here and there a black pin-pointed speck, and a few black solid nodules the size of small peas attached to the calices. The capsule is not adherent.

Right kidney weighs 5½ oz. It also has a slight sprinkling of the black specks on its surface. On section there is a black nodule the size of a pea in its medullary substance, and a small cyst in the cortex containing syrupy contents. The capsule strips readily.

The entire surface of the abdominal peritoneum is as if it were thickly sprinkled with black, hard, warty-looking nodules, varying in size from a millet-seed to a bean.

In what one might call *cul-de-sac*, such as the pouch of Douglas and iliac fossæ, there are foci more thickly grouped together.

This sprinkling is also seen on the surfaces of the omenta and between their layers. On the mesentery at its junction with the intestines, this sprinkling suddenly pulls up and forms a thickly-set boundary or line, while on the serous layers of the intestines, bladder, and stomach, there is only a speck of the smaller size seen here and there. The mesenteric glands are black and hard, and apparently enlarged.

Bladder contains about 2 oz. of bile-stained urine.

Ureters present nothing abnormal except that a small spiny calculus is impacted in the lumen of the left.

Prostate is exceeding hard, and on section is cram full of greyish-white solid bodies, about the size of a No. 5 shot.

Right testis, the only one examined, has a blackish-grey spot the size of a split pea in its substance.

Thyroid is hard and firm, and the right lobe considerably larger than the left. The surface is nodulated but smooth. On section it seems as if made up of greyish-white nodules, the size of small

Digitized by Google

peas. Near the periphery of the right lobe they have a slaty-grey appearance. The upper part of the left lobe is occupied by a circumscribed, firm, fatty-looking mass. The isthmus is reddish and apparently normal. The lymphatic glands in the neigbourhood of the trachea are black, but apparently not enlarged.

The salivary glands seem normal.

The spinal cord was removed, but beyond a calcareous plate here and there in the pia mater, there is nothing abnormal to the naked eye.

The whole length of the aorta and its branches are as rigid as the trachea, with calcareous impregnation.

The left eye is removed. On section it is a solid blackish-brown mass encapsulated in a firm opaque capsule, resembling the sclerotic, which it probably is in its whole extent. On a level with the entrance of the optic nerve, this capsule sends a prolongation through the globe to its top, marking off a saddle-shaped segment posteriorly, which is less than half the anterior segment and of a darker colour.

The case is one of melanotic sarcoma in sites that include the left eye, skin, lung, pleura, lymphatic glands, heart, pericardium, pulmonary veins, spleen, thyroid gland, pancreas, liver, kidney, supra-renal capsule, peritoneum, intestines, prostate gland, and testis. The joints were not examined.

The morbid histology of the growth consists of large spindles and round cells, with pigment varying from black to golden-brown, while some bits of the growth are without any pigment.

(1). In making a clinical *resumé*, one would be disposed to observe as of interest, among other points, the absence of œdema, or a trace of dropsy or fluid in any of the great cavities of the chest and abdomen, although the organs of these cavities were packed with new growth. The tenderness over the epigastrium and abdomen generally, intensified frequently with severe paroxysms of pain, the nausea and vomiting after meals, the progressive loss of weight, slight icterus or yellowish-tinged skin, and pale stools. The laboured inspiratory effort, especially on even such slight exertion as speech, as if the elasticity or expansion of the chest were diminished and performed with difficulty. The absence of cough, expectoration, or any physical sign of pulmonary disease beyond an absolute, but not a relative, dulness on percussion, and, lastly, the pains and stiffness in the joints.

Digitized by Google

(2). The pathological aspects of the distribution are probably more interesting still.

As far as the history of the case may be relied upon, it is probable that the eye is the primary source, and this view but falls in with the literature on the subject, for the most frequent primary location lies between the skin and the eye. Bearing on the mode and direction of the distribution, therefore, one notes that the great central nervous system was unaffected, that there was no affection of the other eye, and that the severity of the disease in the affected eye subsided, or became quiescent, some time before the death of the patient.

Secondary melanotic sarcomata are frequent in the liver and lungs, but less frequent in the pleura. Melanotic sarcoma of the pericardium is rare, as are also secondary new growths in the spleen (Prof. Greenfield's 'Lectures on Pathology,' Session 1882–1883).

Sarcoma of the kidney is not common, but sarcoma of the intestines is rare (Prof. Hamilton's 'Lectures on Pathology,' Session 1888–89). According to Dr. Coats ('Manual of Pathology'), secondary tumours are rare in the heart, and secondary sarcoma does not occur readily in lymphatic glands, but tumours may penetrate into veins but do not produce tumours in them. Sarcoma of the thyroid gland occurs, but is rare, and I am not sure if it is on record as a melanotic growth. I have not been able to find reference to melanotic growths of the testis or prostate, nor to sarcoma, of any kind, of the supra-renals.

The writer of the article in Von Ziemssen's 'Medicine' says that sarcoma may occur as a secondary growth in the pancreas; but he observes, "Nevertheless I have not been able to find a well-authenticated case of this disease on record." Since this has been written, however, a case of primary sarcoma of the pancreas in a child, aged four, was read by Professor Litten at the meeting of the Berlin Verein für Innere Medicin two years ago—the first case of sarcoma of the pancreas, observes this authority, ever described. But this is probably not so, for at the meeting of the Pathological Society of London in March last year, Dr. Norman Moore, in reading a case of sarcoma of the liver, referred to Sir William Lawrence as having described a case of sarcoma of the liver and pancreas occurring three years after the removal of a similar growth in the eye. If this, therefore, represents the literature on the subject, the

Digitized by Google

case that I have the honour of bringing before you is unique, and even as a sarcoma of the pancreas, I believe, third on record.

I am indebted to Professor Greenfield for making and staining the sections that so beautifully illustrate the case.[1]

April 21*st*, 1891.

[1] In the museum of St. Thomas's Hospital, London, there is preserved portion of a pancreas in which are about half a dozen melanotic tumours, averaging about a third of an inch in chief diameter. The specimen was from a case of melanotic disease of the eye, liver, heart, kidney, and other parts.

Digitized by Google

XI. MISCELLANEOUS COMMUNICATIONS.

1. *On the morphology, cultivation, and toxic products of the tubercle bacillus.*

By Edgar M. Crookshank, M.B.

[With Plate VII, Figs. 1 and 2.]

Morphology of the Tubercle Bacillus.

In 1888, while investigating the transmission of tuberculosis by the milk of tubercular cows, I was led to study the morphology of the tubercle bacillus in the manifestations of tuberculosis in different animals.[1] It is well known that the bacilli in tissue sections of bovine tuberculosis are shorter and less granular than those in human tubercular sputum. On examining milk from tubercular cows my attention was arrested by the appearance of the bacilli. They do not possess the familiar appearance of the bacilli in tissue sections. They are longer and very distinctly granular or beaded, and are thus brought much closer, morphologically, to the bacilli in human sputum. If we take individual bacilli in cow's milk, some are even longer and more regularly beaded than the bacilli in most preparations from a human source. Speaking generally, however, the average length of the human bacilli is greater than the average length of the bacilli in cow's milk, but the longest of the bovine bacilli cannot be distinguished in length from the longest human bacilli. There are, however, exceptional cases, for in some preparations of pus from human lungs the bacilli are remarkable, not only for their thinness, their uniformly beaded character, but more particularly for their extra-

[1] 'Annual Report of the Agricultural Department for the Year 1888;' 'Report on Tubercular Mammitis in Cows, with Experiments relating to the Infectivity of the Milk, and Remarks on the Tubercle Bacillus.'

Digitized by Google

ordinary length. They should be compared with other preparations in which the bacilli, though in human sputum are sometimes much more distinctly rod-shaped, much shorter and thicker, with complete absence of any beaded appearance. In short, neither length nor granularity is a characteristic sufficient to denote any specific difference between human and bovine bacilli. Following up the same line of inquiry I have examined minutely the bacilli in tuberculosis of other animals, such as the horse, pig, and cat; and of birds—the fowl, guinea-fowl, pheasant, and ostrich. Here, again, minute morphological differences can be observed. For example, in many cases in fowls the bacilli are conspicuously short and straight. In the liver and lungs of an ostrich I found packets of short rod-forms, while in other parts of the same sections the bacilli attained a greater length than I had at that time observed in any other tubercular specimen. Many of the long sinuous forms exhibited a peculiar terminal enlargement. There were also short rods with a similar appearance, and free ovoid bodies singly and in groups, which, from their connexion with the bacilli, and their sharply-defined outline in the free state, are very suggestive of spores.

Thus morphological differences are found under different circumstances, and within limits the morphology of the tubercle bacillus varies with its environment.

Tuberculosis is universally recognised as a disease common to man and the lower animals, and associated with the presence of a specific micro-organism—the tubercle bacillus. But the exact relation of bovine to human tuberculosis is a question of vast practical importance, and we must not hastily draw conclusion from the appearance of the bacilli in the two cases.

If calves can be infected with tuberculosis from a human source by inoculation or ingestion experiments, and especially if the effects of administering human and bovine tubercle to calves by those means are found to be the same, such experiments will not only serve to dispel any doubt that may be, from a difference in length of the bacilli, as to the identity of the two affections, but they will strengthen the hands of those who insist upon the necessity of more thorough inspection of dairy cows, and of power to deal with tubercular animals.

These considerations led me to undertake a series of experiments which are still in progress. First of all, I proposed to inoculate

Digitized by Google

sputum from the human subject, in which I had verified the presence of bacilli, and, subsequently, if in this case tuberculosis resulted, to inoculate calves with pure cultivations of the bacillus isolated from human sputum.

Inoculation of a calf with human tubercular sputum.—I obtained sputum containing numerous bacilli, from an advanced case of phthisis. The sputum was shaken up with sterilised salt solution and injected into the peritoneal cavity. A few weeks afterwards the calf shows signs of illness. The animal looked dull, did not feed well, had a slight cough, and showed less inclination to move about than usual. These symptoms gradually increased, and death occurred forty-two days after inoculation. Extensive lesions were discovered at the *post-mortem* examination. The mesentery was adherent to the abdominal wall at the seat of the inoculation and to the rumen; the liver was adherent to the diaphragm. There was extensive tubercular deposit at the seat of inoculation, and an abscess the size of a walnut. Extending over the mesentery from this point there were hundreds of wart-like, fleshy, new growths, some quite irregular in form, others spherical or button-shaped. There were similar deposits on the under surface of the liver, on the spleen, in the gastro-splenic omentum, and on the peritoneal surface of the diaphragm. The spleen was adherent to the rumen, and on dissecting away the adhesions another abscess was opened. On the under surface of the liver was a third abscess, about the size of one's fist, which burrowed in the depth of the liver substance. The kidneys were very firm on section. The lungs were congested and the pleuræ thickened. On microscopical examination extremely minute tubercles were found disseminated throughout the lungs and liver. Tubercle bacilli were found in these organs and in the peritoneal deposits. The pus from the liver abscess contained streptococci. The calf died from pyæmia, a result to be anticipated if sputum be employed for inoculation, but sufficient time had elapsed for pronounced local infection, leading to acute miliary tuberculosis.

This experiment having definitely proved that human tuberculosis could be transmitted to calves, the next step was to isolate the bacillus from human sputum, and to cultivate it on suitable media, and I was thus led to confirm and extend the experiments of Nocard and Roux. These experiments, and the results which followed, I shall proceed to describe at length, leaving the details

Digitized by Google

of experiments on calves, rabbits, guinea-pigs, and frogs with the cultivated bacilli to be described and commented upon on another occasion. I would here only briefly refer to experiments on frogs. According to Metschnikoff's phagocyte theory, there is a battle between the cells and the bacilli. If an animal has an immunity, or recovers from a disease, the cells or phagocytes have been able to gain the upper hand and destroy the invading micro-organisms. If, on the other hand, there is no immunity, the micro-organisms overpower the cells, increase and multiply, and destroy their host. By injecting a few minims of a cultivation of the bacillus in broth into the dorsal lymph sacs of frogs, and by withdrawing some of the lymph by means of a capillary pipette, at intervals of a few hours, and then of weeks, these phenomena can be minutely studied. The lymph cells can be seen to take up one or more tubercle bacilli, and in some cases are completely filled by them.

The question arises whether the cells actually take up and destroy living bacilli, or whether the tubercle bacilli are first devitalised by the *liquor sanguinis*, which in immune animals is an unsuitable medium for their growth.

Cultivation of the Tubercle Bacillus.

Blood serum.—Koch attempted to cultivate the bacillus on nutrient gelatine without success, and concluding that it was necessary to employ a high temperature he substituted sterilised blood serum. The blood serum was prepared by an elaborate process involving enormous expenditure of time and labour, and very few were able to verify his researches. In about ten or fifteen days a growth began to appear and minute dry scales were visible to the naked eye. In liquid blood serum a thin film formed on the surface of the liquid, easily broken by agitation. In neutralised broth there was very little indication of success; a triturated culture was added to the broth, and a granular, sandy, whitish deposit collected at the bottom of the vessel, with indications of an increase in amount. Koch also tried nutrient agar-agar, which did not prove to be at all a favourable medium. Some increase took place, but there was no continuous growth over the inoculated area.

Glycerine agar-agar.—Nocard and Roux were among those who worked at the subject and confirmed Koch's observations. Nocard attempted to get cultures of avian tuberculosis on blood serum to

Digitized by Google

which peptone, salt, and cane sugar had been added. The results were more successful than with ordinary serum. But he encountered a difficulty in the rapid drying of the surface of the medium which rendered the tubes unfit for use. It occurred to Nocard and Roux to obviate this by the addition of a hygroscopic agent, and accordingly they added sterilised glycerine. The result, which far exceeded their expectation, evidently was not solely attributable to the prevention of desiccation. Following up their discovery, and being anxious to find a medium more easily prepared than blood serum, they added 6 to 8 per cent. of glycerine to ordinary nutrient agar-agar. The bacillus grew so abundantly in this mixture that a culture in fifteen days equalled in extent a culture on blood serum which was several weeks old. The bacillus was found to grow abundantly in veal broth, to which glycerine had been added in the proportion of 5 per cent., the bottom of the flask being covered in about three weeks with a flocculent deposit, having some resemblance to anthrax cultivations in liquid media. In beef broth, chicken broth, and in Cohn's liquid, cultures were obtained after the addition of glycerine.

Confirmation and extension of the results obtained by Nocard and Roux.—Through the kindness of M. Roux I had an opportunity the same year (1888) of examining his cultivations at M. Pasteur's laboratory, and I am also indebted to him for a cultivation from which subcultures have been kept up in my laboratory during the past year to the present time. I have another distinct series of cultures originally obtained direct from human tubercular sputum. I propose first to supplement the statements of Nocard and Roux, by a more detailed description of the macroscopical and microscopical appearances of cultivations in different media.

Description of cultivations on glycerine agar-agar.—The cultivations on the sloping surface of obliquely solidified glycerine agar-agar begin to appear in from four to six days as very minute white colonies. These steadily increase in size, and either look moist and smooth, or, even at this early stage, appear dry and crinkled. According to the number of bacilli inoculated, the colonies will either remain isolated or coalesce and form a more or less continuous film. If the nutrient agar-agar has only recently been prepared, there is usually a quantity of liquid present, and the bacillus forms a white coating over the inoculated area and beyond it. The appearances are much more characteristic when this

Digitized by Google

medium is, comparatively speaking, dry. A semi-transparent membranous growth develops, thickens, and assumes a characteristic lichenous appearance (Plate VII, fig. 4). Such a culture, examined with a pocket lens, resembles a model in wax in miniature of the folds of the gastric mucous membrane. In about six weeks to two months the culture has fully developed. In old cultures, especially when the individual colonies remain isolated, the appearance is very characteristic. Some cultures in appearance closely resemble cultivations on blood serum. The consistency of the growth depends upon the character of the soil and the age of the culture. If the medium be moist the growth is moist and viscous, but more often it is distinctly tallowy, and in old and dry cultures scaly and friable.

Cultivations in glycerine broth.—From subcultures on glycerine agar-agar I have obtained luxuriant growths in glycerine broth. In a few days minute flakes are visible, which steadily increase in size and subside to the bottom of the flask, forming in time a very copious deposit. On shaking the flask this deposit, which is extremely tenacious, rises in stringy masses, gives an appearance which appears to be quite characteristic. If the flask is left undisturbed a delicate veil-like film forms over the surface, which can be readily broken up by gentle agitation, forming flakes which gradually sink in the liquid. If undisturbed for several weeks this film increases in thickness, is irregularly fissured, and has more the appearance of masses of tallow floating on the surface. The growth also may be seen to extend up the side of the flask above the liquid. Pasteur or Erlenmeyer flasks can be employed for these cultures: I prefer the former. Solidified egg-albumen added to the glycerine broth seems to increase the amount of growth which clings to the albumen, and waves to and fro in the liquid when the flask is gently shaken. I have also confirmed the observation of Nocard and Roux that subcultures from glycerine agar-agar or from glycerine broth will give cultures in ordinary broth without glycerine. Ordinary broth with egg-albumen and without glycerine will also give a good growth when inoculated from previous subcultures, although the attempt to produce primary cultures in these media has hitherto failed.

Cultivations in glycerine, milk, and other media.—In milk I find there is only a slight increase in the number of bacilli inoculated, but milk with glycerine in the proportion of 5 per cent. forms a

Digitized by Google

more favourable medium. I have also cultivated the bacillus on sterilised urine and glycerine and ordinary nutrient gelatine with 5 per cent. of glycerine.

Examination of cultivations.—To examine the bacilli in these various preparations I prefer to use Neelsen's method, floating the cover-glasses for from five to ten minutes on warm carbolised fuchsine and passing them through diluted sulphuric acid. In some cultures the bacilli are shorter and thicker than is commonly observed in human sputum, and they are for the most part without the beaded appearance. In old cultures on glycerine agar-agar the number of granular or beaded bacilli increases, and there are also a number of peculiar forms. There are bacilli, in some cases two or three times the length of an ordinary bacillus, provided with a club-shaped enlargement at one or both extremities, and in some cases bacilli with lateral branches. I regard these as corresponding with the so-called involution forms, and they are no doubt identical with the bacilli with swollen extremities and the branched forms observed by Nocard and Roux.

In milk the appearance is very striking, many bacilli attaining in old cultures a great length, and all are more uniformly beaded than in any other cultivations. Staining preparations by the method of Gram in all cases exaggerates this appearance.

The important part played by the environment is shown by the morphological differences observed in artificial cultivation under varying conditions, and by the fact that by successive cultivation the bacillus can be educated to grow upon a medium which is unsuitable for obtaining primary cultures.

Impression preparations of the growth of the bacillus on the surface of glycerine agar-agar in capsules show a tendency to the formation of serpentine colonies, composed of bundles of more or less parallel bacilli.

Spore-formation.—In old cultivations true spore-formation can readily be observed both in stained and unstained preparations. In the latter case they are recognised in the form of one or two highly refractive bodies in individual bacilli.

Digitized by Google

Digitized by Google

DESCRIPTION OF PLATE VII.

Figs. 1 and 2 illustrating Dr. Delépine's paper on Psorospermia. (Page 371.)

FIG. 1.—Section through the walls of the psorospermial nodule which was used in the cultivation experiments described in the paper.

FIG. 2.—The same, less highly magnified, to show the papilliferous nature of the growth.

Both specimens were photographed by Mr. Andrew Pringle from specimens prepared by the author. In Fig. 1 the psorospermia appear as dark encapsulated bodies in the midst of the paler epithelium.

Figs. 3 and 4 illustrating Professor Crookshank's paper on the Tubercle bacillus. (Page 330.)

FIG. 3.—Pure cultivation of Tubercle bacillus in glycerine agar-agar,—a subculture from a pure culture in glycerine-milk. Eight weeks old.

FIG. 4.—Pure cultivation in glycerine agar-agar after ten months' growth.

From photographs.

On p. 330 *for* Figs. 1 and 2 *read* Figs. 3 and 4.
On p. 371 *for* Figs. 3 and 4 *read* Figs. 1 and 2.

Digitized by Google

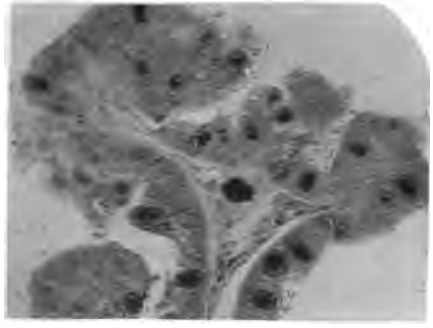

FIG. 1.



FIG. 2.

FIG. 3.

FIG. 4.

DANIELSSON & CO., Photoprint.

Digitized by Google

Digitized by Google

Toxic Products.

In August last Koch[1] announced that after failing with ethereal oils and with metallic substances, such as compounds of cyanogen and gold, to check tuberculosis in animals, he had hit upon a substance which prevented the growth of the bacilli, not only in tube cultivations, but in the body of an animal. On November 14th Koch[2] published a further communication describing the effects upon lupus and other tuberculous processes. It had occurred to me as possible that Koch had been working on the same lines as Wooldridge, Hankin, and Martin. On the other hand, it was equally possible that Koch's researches were in an entirely new field. I was therefore stimulated to investigate the products of the tubercle bacillus in glycerine broth cultures, as in any case the results could not fail to be of interest. I prepared glycerine broth cultures in bulk, and having by December 5th obtained abundant growths of the bacillus, I separated the bacilli from the liquid cultures by filtration. Before, however, describing and demonstrating the methods and the apparatus which I employed and the results which followed, I will venture to give a brief historical sketch of the work which had previously been done in this field of physiological and pathological chemistry.[3]

Ptomaines, toxines, and albumoses.—In 1822 Gaspard and Stick found an intensely poisonous principle in cadaverous extracts; in 1856 Panum discovered a poisonous substance in putrid material; and in 1863 Bergmann and Smiedeberg found a nitrogenous crystallisable substance in putrid beer which they named *sepsin.* Zuelzer and Sonnenschein isolated a venomous nitrogenous body from putrid meat. In 1872 Gautier found that the decomposition of fibrine led to the formation of various complex alkaloidal substances, and in 1875 Dr. B. W. Richardson[4] obtained in pyæmia an alkaloid, *septine.* This subject, however, received most attention from the classical researches of Selmi, the Italian toxicologist.

[1] 'An Address on Bacteriological Research,' International Medical Congress, August, 1890.

[2] "A Further Communication on a Remedy for Tuberculosis," 'Deutsche med. Woch.,' Nov. 14th, 1890.

[3] I would refer the reader interested in this subject to 'Animal Alkaloids or Ptomaines and Leucomaines,' A. M. Brown; 'Ueber Ptomaine,' Brieges; 'Chemical Physiology and Pathology,' Halliburton.

[4] The 'Lancet,' April, 1875.

Digitized by Google

Selmi, in a celebrated poisoning case, demonstrated the presence of an alkaloid as the result of *post-mortem* changes. Similar substances were found in alcohol in which morbid specimens had been preserved. Thus the researches of Gautier and Selmi established the fact that albuminoid material undergoing decomposition leads to the formation of cadaveric alkaloids. These animal alkaloids Selmi named *ptomaines*. To several investigators, but to Nencki and Brieger particularly, we owe the additional knowledge we have obtained of these poisonous animal substances. Brieger, finding the bases derived from the products of putrefaction less poisonous than those obtained from the pathogenic bacteria, suggested the term *toxines* for the latter. Ptomaines have been divided into two classes—those which are non-oxygenous and are liquid and volatile, and those which are oxygenous, solid, and crystallisable. They are for the most part precipitated by the ordinary reagents for alkaloids such as chloride of gold, double iodides of mercury and potassium, picric acid, and tannin. Phospho-molybdic acid precipitates them without exception. They are powerful reducing agents. Ferrocyanide of potassium is converted into ferricyanide in their presence, and the addition of ferric chloride gives the Prussian blue test. Selmi discovered this test, and Brouardel and Boutmy regarded it as absolutely characteristic of ptomaines; but this is not the case. Some vegetable alkaloids, for example, behave in the same way.

As examples of the non-oxygenous ptomaines there are—

Parvoline.—$C_9H_{13}N$, an oily base of an amber colour prepared from putrid mackerel and horse-flesh.

Hydrocollidine.—$C_8H_{13}N$, prepared from the same source. Highly toxic, being compared by Gautier to the venom of the cobra di capello.

Collidine.—$C_8H_{11}N$, obtained from putrid gelatine and pancreas of a bullock, also highly toxic.

Neuridine.—$C_5H_{14}N_2$, prepared from fish, flesh, decaying cheese.

Saprine.—$C_5H_{14}N_2$, isomeric with *neuridine*.

Cadaverine.—$C_5H_{14}N_2$, a third isomeride. Obtained ordinary putrefaction from herring brine, and from cultivations of Koch's and of Finkler's comma bacilli.

Putrescine.—$C_4H_{12}N_2$, from putrefaction. Both *cadaverine and putrescine* are poisonous. They produce choleraic symptoms, hæmorrhages, and necrosis.

Digitized by Google

The oxygenous ptomaines in some cases are also found in healthy tissues—

Neurine.—$C_5H_{13}NO$, occurs in cadaveric putrefaction.

Choline.—$C_5H_5NO_2$, in bile.

Muscarine.—$C_5H_{13}NO_2$, in a poisonous mushroom, *Agaricus muscarius*, and in putrid fish. These are all highly poisonous.

Gadinine.—$C_7H_{16}NO_2$, in putrefying codfish.

Mytilotoxine.—$C_6H_{15}NO_2$, in poisonous mussels.

Typhotoxine.—$C_7H_{17}NO_2$, isolated from pure cultivations of the typhoid fever bacillus.

Tetanine.—$C_{13}H_{22}N_2O_4$, isolated by Brieger in tetanus.

Poisonous alkaloids are of great importance in connection with those cases of meat poisoning produced by sausages, hams, and poultry. Tyrotoxicon is an alkaloid obtained from cheese. But the poisonous substances of most interest to the bacteriologist are those isolated from pure cultivations of pathogenic bacteria, such as cadaverine and putrescine, isolated by Brieger from cultivations of Koch's comma bacillus; typhotoxine and tetanine, and poisons which are not alkaloids—the *albumoses* or *tox-albumins*—poisonous substances allied to the albumose of snake poison. Pasteur[1] suggested that in antirabic inoculations the immunity resulted from the action of a substance secreted by a hitherto undiscovered microbe. Salmon[2] produced immunity from hog cholera by the injection of the filtered culture fluids. Charrin,[3] and later Woodhead and Wood[4] and Blagovestchensky,[5] worked with bacillus pyocyaneus. Roux and Chamberland[6] performed similar experiments with the bacillus of malignant œdema; Roux[7] with symptomatic anthrax; Chantemesse and Widal with the typhoid bacillus. Roux and Yersin worked on the same lines with diphtheria, and Brieger and Fraenkel[8] obtained a tox-albumin from their cultivations. Anrep[9] found an albumose in the medulla of rabid animals, and Babès[10] claims to

[1] 'Comptes Rendus,' tome ci, p. 766, 1885.

[2] 'American Vet. Rev.,' 1886; 'Reports,' Agricultural Department, U.S., 1887.

[3] 'La Maladie Pyocyanique,' 1889.

[4] The 'Lancet,' 1890.

[5] 'Annales de l'Institut Pasteur,' 1890.

[6] Ibid., 1887 and 1888.

[7] Ibid., 1888.

[8] 'Berliner klin. Woch.,' 1890.

[9] Vrach, quoted by 'Brit. Med. Journ.,' 1889.

[10] Quoted by Hankin, 'Brit. Med. Journ.,' July, 1890.

Digitized by Google

have found an albumose in both rabies and glanders. It is not, however, too much to claim for our own countrymen priority in the scientific investigation of the poisons of pathogenic bacteria.

Wooldridge's researches.—In 1887 Wooldridge[1] succeeded in protecting rabbits from anthrax by a new method. A proteid body obtained from the testis and from the thymus gland was used as the culture fluid. This proteid substance was dissolved in dilute alkali and the solution sterilised by repeated boiling. This was inoculated with the anthrax bacillus and kept at 37° C. for two or three days. A small quantity of the filtered culture fluid injected into the circulation in rabbits produced immunity from anthrax. Subcutaneous inoculation of extremely virulent anthrax blood made at the time of the injection of the protecting fluid and subsequent inoculation remained without effect, and Wooldridge concluded that the growth of the anthrax bacillus in special culture fluids gave rise to a substance which, when injected into the organism, protected against an immediate and subsequent attacks.

Hankin's researches.—In 1889 Hankin[2] worked under the guidance of Professor Koch in the Hygienic Institute of Berlin. The acquired tolerance of the effect of ordinary albumoses, and the experiments of Sewall,[3] who produced immunity against lethal doses of the albumose of snake poison by the injection of minute doses, led Hankin to expect that if an albumose developed in anthrax cultures, such anthrax albumose would probably confer immunity from the disease. Such an albumose Hankin succeeded in isolating from culture fluids. It was precipitated by addition of excess of absolute alcohol, well washed in alcohol to free it from ptomaines, filtered, dried, then redissolved and filtered through a Chamberland filter. With this albumose, Hankin succeeded in producing immunity in mice and rabbits.

Martin's researches.—Sidney Martin,[4] working quite independently, grew the anthrax bacilli in a solution of pure alkali albumin made from serum proteids. After ten or fifteen days the organisms were removed by filtration in a Chamberland filter. The filtrate contained *proto-albumose* and *deutero-albumose*, a trace of

[1] 'Transactions of the Royal Society,' xxii, p. 312, received April 16th, 1887; 'Archiv für Anatomie und Physiolog.,' 1888.

[2] 'Brit. Med. Journ.,' Oct. 12th, 1889, and July 12th, 1890.

[3] 'Journ. of Physiology,' 1887.

'Nature,' May 29th, 1890, p. 118.

Digitized by Google

peptone, an *alkaloid*, and small quantities of *leucin* and *tyrosin*. The mixture of albumoses proved poisonous to mice. The anthrax alkaloid produced symptoms and lesions similar to the albumoses, but much more rapidly and severely. Martin concluded that the anthrax bacillus in digesting the alkali albumin formed albumoses and an alkaloid. And he suggested that the alkalinity of the albumoses explained their toxic properties, the alkaloid probably being in a nascent condition in the albumose molecule.

Toxic products of glycerine cultures of the tubercle bacillus.—I will now proceed to describe my own experiments. Having obtained by December 5th several batches of cultures in glycerine broth, the next step was the separation of the bacilli by filtration. I employed for this purpose a simple apparatus constructed for me by Becker. It consists of an exhausting apparatus in which the bell-glass is cylindrical in form. The mouth of the cylinder is plugged with a perforated india-rubber stopper, which tightly grips a porous pot of white porcelain. To prevent putrefaction during the process of filtration I add 5 per cent. solution of carbolic acid in the proportion of 1 per cent. The filtrate is perfectly transparent, alkaline in reaction, and yellowish-brown in colour. As it was probable that any toxic substances were present in very minute quantity, I evaporated down the filtrate in a vacuum over sulphuric acid and at a low temperature. This proved to be a very tedious process, and occupied from December 8th to January 12th. In the meanwhile I prepared additional filtrates in the way I have already described. On January 12th the filtrate was reduced to a brownish viscous residue consisting principally of the glycerine from the original culture fluid. I diluted this viscous residue with ten minims of sterilised water, and injected two minims subcutaneously in a guinea-pig. There was no doubt that I was in possession of a very toxic substance. The effect was almost immediate. The temperature began rapidly to fall, the coat was staring, and the heart's action extremely irregular. This was followed by irregular muscular spasms. There was loss of control over the extremities, and death ensued. The temperature before injection was $99\frac{3}{5}°$; at 1 p.m., 93°; 2 p.m., 94°; 3 p.m., $93\frac{1}{5}°$; 4 p.m., 92°. In a lethal dose in the healthy animal this toxic extract is therefore a powerful hypothermic agent.

Chemical reactions.—The following were the results obtained on chemically testing the original filtrate. Phospho-tungstic acid gave

Digitized by Google

a copious white precipitate. Potassic bismuthic iodide a distinct orange-yellow. Potassic ferricyanide gave after standing a few minutes a beautiful blue (Prussian blue test) on addition of ferric chloride. Iodine in potassic iodide solution gave a precipitate after standing for an hour; more marked after twenty-four hours. The precipitate examined microscopically was composed of boat-shaped and acicular crystals; examined after some hours the crystals were in varied forms of a highly characteristic appearance. There was also under other conditions an amorphous precipitate. Phosphomolybdic acid gave a yellowish precipitate, and a blue colour on the addition of ammonia, which disappears on boiling.

The tubercle bacillus probably produces from proteid substances a complex proteid poison in which, as in anthrax, the alkaloid of tubercle, or *tuberculine*, is in a nascent condition. According to different stages of cultivation, we should therefore expect to find either a complex proteid substance of the nature of an albumose, or this complex substance together with free ptomaine, or the ptomaine alone; the ptomaine being a later product of the splitting up of the proteid substances.

Glycerine infusion of tubercular tissue.—I have also pursued another line of inquiry. I obtained on December 10th masses of tubercular glands from the lungs of a cow suffering from *Perlsucht*. The lungs had been sent to the Royal Veterinary College for examination. These masses of tubercular new growth were cut up, rinsed in distilled water, finely minced, left in ice overnight; the turbid extract obtained by squeezing through a cloth was finally filtered through porcelain. A perfectly clear amber-coloured fluid was obtained. I must defer a detailed account of the experiments with this infusion; but one result of interest, proving that the virus of tubercle is particulate, is that guinea-pigs inoculated with the infusion before filtration contracted tuberculosis; guinea-pigs inoculated with the clear filtrate remained free from tubercle. To ascertain whether there is protection given in the latter cases they have since been inoculated with fresh tubercle, and the result remains to be seen. More recently I have prepared a similar filtrate by another method. Masses of tubercular glands from another case of *Perlsucht*, amounting in weight to about 5 lb., were cut up, finely minced, mixed with 4 oz. of glycerine, and left in ice overnight; 15 oz. of a turbid infusion were obtained. Solution of phenol (5 per cent.) was added in the proportion of 1 in 10.

Digitized by Google

This was filtered through porcelain, and a clear yellowish filtrate obtained. This filtrate gives similar chemical reactions to artificial cultures of the bacillus.

Separation of albumose and ptomaine.—With the co-operation of Mr. Herroun I proceeded to analyse the crude extract and to study the effects of the isolated products both on tubercular and on healthy guinea-pigs. The results which we have so far obtained we have already communicated to the Physiological Society.[1]

February 17th, 1891.

---

2. *Note on tubercular animals under treatment with tuberculin.*

By P. Abraham, M.D., and E. Crookshank, M.B.

Two tubercular guinea-pigs received ten injections in centigramme doses of tuberculin which had been received by Dr. Abraham from Dr. Koch. Similar doses were at the same time administered to a healthy guinea-pig. Two guinea-pigs in the same stage of tuberculosis were carefully examined both macroscopically and microscopically after death as a guide to the condition of the internal organs in the cases selected for treatment. The lymphatic glands were caseous, and contained bacilli. There were deposits in the spleen, which also contained bacilli. The cases selected for treatment were therefore undoubtedly tubercular, without the disease being too far advanced. There were well-marked chains of tubercular glands, but the animals were nevertheless active and well nourished. The first injection caused considerable constitutional disturbance, rise of temperature, tenderness, and great swelling of the diseased glands and redness of the surrounding skin. The second and subsequent injections produced a rise of temperature and tenderness, but no sudden glandular swelling. In one guinea-pig the tubercular glands had steadily increased in size; in the other there had been but little change since the first injection. The temperature reaction was most marked in the former after the fourth injection, when it reached 107⅘° F. in two

[1] Crookshank and Herroun, 'On Two Chemical Properties and Toxic Effects of Two Products of the Tubercle Bacillus in Pure Cultivations.'

Digitized by Google

hours. With the exception of a very slight rise in temperature the healthy guinea-pig was not affected by the injection. So far, these cases showed that in tubercular guinea-pigs Dr. Koch's fluid in centigramme doses produced similar phenomena to those observed in the human tubercular subject. Both the tubercular guinea-pigs died subsequently with well-marked general tuberculosis, one 60 days and the other 98 days after the original inoculation. A cow suspected of being tubercular was injected on two occasions with doses of two and three centigrammes. The temperature, taken hourly, remained normal, but increased cough was observed for some hours afterwards. A further dose of ·5 gramme was followed by a negative result.

February 17th, 1891.

---

3. *Note on media for the cultivation of the bacillus of tubercle.*

By Hugh R. Beevor, communicated by Professor Crookshank.

The cultivations which are exhibited, illustrate to some extent the diversity of media, and the range of temperature in which the tubercle bacillus will grow.

There are cultures on glycerine agar, on potato, and in broth. Those on potato are confirmatory of the observations published in the 'Annales Pasteur,' 1886, which were made by Paulowsky, and his description—the appearance after six weeks of white grains the size of a pin's head—tallies with the appearances visible in these specimens; in some, however, the colour is brown.

Paulowsky further satisfied himself that such a growth could be obtained from tubercle in the animal directly, as well as from former cultivations, as in this case; and that three successive generations on potato in no way diminished the virulence of the organism. Spores were developed as in other media.

It is apparent that potato as a medium allows but a slower and less luxuriant growth than on glycerine agar or than in broth; twenty days to a month pass before the growth is visible to the eye

Digitized by Google

and it never seems to thickly cover the whole surface as it will with glycerine agar. No glycerine was added to the potato.

The cultures on glycerine agar and potato were grown for ten weeks at a temperature of 28° C. (82° F.), and have been at no time exposed to a higher temperature; they have developed more slowly and to a less extent than cultures grown at 37° C. (blood heat).

Of the broth cultures, two show the bacillus of tubercle growing in that medium at an even lower temperature than those on agar; they have stood in my room against an outside wall, twenty feet from the fireplace, since November 21st, and I have no doubt in stating they have not been in a temperature above 60° F., unless for an hour or two midday the temperature rose so high outside. The mean temperature for December was 28° F., and frost very persistent. These two were the only tubes I had in my room.

Other broth cultures show to some extent the resisting power of this bacillus to perchloride of mercury in solution in the broth. 1 in 200,000 but slightly hinders growth; 1 in 50,000 delays it much.

One tube illustrates the growth of the bacillus in the presence of a growth of bacterium termo, which had contaminated the tube.

The difficulty that was originally found in cultivating this bacillus on solid media as agar still remains, for even with glycerine added, which with agar is so necessary for luxuriant growth, as was shown by Nocard and Roux, it sometimes fails.

In broth it is apparent that it grows more rapidly, and is more independent of temperature, which will make this the most convenient medium to many investigators.

I cannot conclude without recording my thanks to Professor Crookshank for his ready assistance in my work, and I would forbear to speculate on the bearing this variety of media and temperature may seem to have on the general habitat of the tubercle bacillus.

January 6th, 1891.

Digitized by Google

4. *Micro-organism of diphtheria with experimental results in animals.*

By Albert Wilson, M.D., Leytonstone.

Diphtheria, according to Dr. Thorne, is increasing, and is the universal enemy of mankind. It attacks the rich and noble as freely as the poor and humble, and it draws no distinction between the strong and the weak. The high mortality caused by diphtheria demands the closest study as to treatment.

The scientific treatment must have as basis a clear and accurate knowledge of the pathology. The first stumbling-block in the pathology of diphtheria is *absence of definition.* There are many cases in which it is difficult to prove, but impossible to deny, that they are diphtheria. To overcome this difficulty we resort to the term "diphtheritic," using it in a self-contradictory sense to mean " not diphtheria," but something like it. The word diphtheritic so commonly used, as, for instance, in scarlet fever throat, corresponds to a counterfeit coin. If a throat is diphtheritic it is true diphtheria, even if in a mild form. If it be not true diphtheria, it i not diphtheritic.

Instead of suggesting a strict definition of diphtheria, I will confine myself strictly to my subject.

Loeffler, Klebs, and others have isolated a bacillus which they consider the cause of this disease. But their inoculation experiments have, so far as I know, not produced definite results. Oertel considered the specific organism as cocci, for he found them in sections of the internal organs.

Klein has, however, superseded all other observers with a series of elaborate experiments, and proves another bacillus than that one of Loeffler and Klebs to be the true diphtheria bacillus. I will call this the *Klein bacillus.* Klein has furnished the Government with a full report of his investigations.

As my results are different, I must briefly recapitulate his research with slight criticism.

In Section A, Klein describes *cover-glass* specimens of diphtheritic membrane, obtaining thereby abundantly his special germ. My

Digitized by Google

experience has been that such membrane contains an uncertain variety of germ, being attached as dead tissue for hours or days in the mouth, with swarms of organisms continually in contact with it. It thus becomes a pabulum for any germs.

Klein washes his membranes in *sterilized salt solution*, which, he says, removes "most of the microbes." I think most bacteriologists will regard this as open to error in isolating pure cultures. Yet by these means Klein states that he has obtained his bacillus "in almost pure cultivation." Klein also states that the foreign organisms "occupy the most superficial layer of the membrane." Surely one must admit that with their rapidity of growth, superficial organisms would penetrate throughout the membrane. *Klein's bacillus* is "constant in the membrane," while Klebs-Lœffler bacillus is inconstant.

In *sections* of membrane and tissue Klein found, with some exceptions, his bacillus "present only in the membrane itself," "chiefly in the superficial layer." This might almost be taken indirectly as *evidence against his bacillus* being the cause of diphtheria. He then made many inoculations in various animals of pure culture of the Klein bacillus. The *general result* was local phlegmon, going on to form a *necrotic tumour* at the seat of inoculation. This "tumour, due to necrosis of the tissue,"—"looking remarkably like the human diphtheritic membrane." But the same might be said of the dead tissue of a carbuncle, and I feel the assumption and the comparison to be wrong.

In many of his fatal cases, he found "fatty degeneration of the cortex of the kidney," and as many of the cats which died of naturally acquired diphtheria had similar kidneys, Klein assumes this as proof of his bacillus being the specific organism. But it is not so, for fatty degeneration of the cortex of the kidney occur in many forms of poisoning, in septicæmia, and in several acute febrile disorders, and is most certainly *not pathognomonic of diphtheria*.

Next Klein produces *corneal ulcer* in the cat by rubbing membrane on an injured cornea, and finds his bacilli in the ulcer. But this is only a case of reaping what he sows, and bears no relation to the main question, for corneal ulcer is not diphtheria. He also inoculated *cows* and gets vesicles on the teats containing his bacilli. But this cannot be considered diphtheria.

Cats supposed to be fed on these cows' milk became ill, and out

Digitized by Google

of fourteen, five died, of which two had membrane in the trachea, containing his bacilli. But it was not proved that there was any connection. The symptoms were coryza, sneezing, coughing, pulmonary trouble, and emaciation.

Klein then experimented on cats and produced pneumonia in them by injecting *his cultures into the trachea*, and finally assumes that in the cat "the probable seat of the local disease is in the lungs and not the fauces." Yet he states that when cats naturally acquire the disease they cough, and get husky, and claw at the throat. I must therefore differ from Klein, that diphtheria in man corresponds to a lung disease in the cat or an udder disease in the cow. As a rule, Klein did not get the common symptoms of diphtheria either in the pharynx or in paralysis. His results, fatty parenchymatous kidney, pneumonia, inflammation or hæmorrhages of the internal organs, and serous membranes, correspond to *blood-poisoning by germs.*

Résumé of objections to Klein's Bacillus diphtheriæ.

1. Because diphtheritic membrane from its situation and exposure is contaminated with a variety of foreign organisms.

2. Because Klein's mode of purifying the membrane is inefficient.

3. Because as a rule the bacillus is not found in the tissues, but confined to the membrane only. "The diphtheritic bacilli do not extend further than the diphtheritic membrane."

4. Because in not one of his inoculation experiments did he produce the symptoms of diphtheria. Either inflammation or membrane in the fauces or paralysis.

5. Because all the symptoms from the inoculation of his bacillus, corresponded with those of ordinary septicæmia, or blood poisoning from germs, namely, pneumonia and hæmorrhages in the internal organs, and serous membranes and, in the latter stages, fatty degeneration of the cortex of the kidney.

6. Because the last symptom he counts as pathognomonic of diphtheria, whereas it occurs in septicæmia as here, also in many acute febrile disorders, and some forms of poisoning.

7. Because his comparison of the necrotic tumour at the seat of inoculation to diphtheritic membrane is far-fetched.

Digitized by Google

8. Because he assumes without any foundation that human diphtheria becomes pneumonia in the cat, and udder disease in the cow.

My own research, during the last few years, in cases of diphtheria, lead me to regard *miccrococci* as the prevailing organisms in severe cases.

My cases were all treated *antiseptically*, thus, to a large extent, excluding foreign organism. I always examined membrane on the first day of its formation, at a later date there was a great variety of organisms.

In progressive cases also, one sees in the surrounding mucous membrane the following changes:

(1) Redness, swelling, and even œdema.

(2) A thin grey or milky-white exudation.

(3) Membrane formation.

It is to this *thin grey exudation*, preceding the membrane, that I wish to call very special attention; it is specially evident in the malignant cases, requiring the closest watching and treatment. It is not alluded to in books or writings.

The reason of this is probably that, for want of antiseptics, the mucous membrane is not clean, and therefore this condition cannot be seen.

With a view to discover and prove the organism of diphtheria, I performed the following experiments and inoculations.

Dr. Enraght, who is associated with me in practice, assisted me conjointly throughout, watching every detail, and corroborating every observation.

I selected a severe case of diphtheria in a boy aged 10, and removed some *membrane* on the third day. With this I inoculated *six tubes* of sterilized gelatine.

The results were two tubes remained clear and free from germs, due to the antiseptic action on the membrane of the drug employed. Four tubes yielded a mixed growth of cocci, baccilli, and threads.

From a *plate cultivation*, I got three kinds of organism. Two forms of micrococci, different sizes and growths. One bacillus, which rapidly *liquefies gelatine*, evolving a chrome green colour. Doubtless these microbes dissolve the membrane; I have not found a description of it, and will call it, *pro tem.*, the *Liquefying Bacillus*.

Digitized by Google

Grown in parsnip infusion, it forms a brown scum, with bubbles of gas underneath, with an absence of green coloration.

I both fed pigeons and *inoculated* them with each of the following four cultures:

(1) The liquefying bacillus.

(2) The larger micrococci.

(3) The smaller micrococci.

(4) The mixed culture of bacilli, thready and cocci.

No visible effect resulted with the first three, and therefore I concluded that the above organisms are innocuous.

The pigeon injected with the mixed culture died emaciated on the ninth day, but with no paresis or throat symptoms. Therefore its death was not associated with diphtheria.

Having failed to obtain a specific organism in the membrane, I next examined the *thin grey exudation* already described.

At the bedside, with delicate forceps, sterilized by heat, I pinched the thin grey layer without removing a visible portion, and inoculated a tube of sterilized gelatine.

(The following day this area was *covered with membrane*).

The throat was cleaned with lactic acid and boracic acid hourly previous to my inoculation.

Kept at 60° F. for six days, *the forceps track* showed turbidity, with small colonies like the ova of pediculi, but smaller. The surface of the gelatine was funnel-shaped at the puncture, the upper part turbid and liquid, with a small orange-coloured deposit.

Microscopic examination showed an absolutely *pure culture of very small cocci* (about $\frac{1}{25000}$th of an inch diameter). They were mostly in pairs, but also in beads and gloca masses.

Incubated for thirty-six hours at 90° F. the gelatine became turbid throughout.

From this tube I made subcultures. With the original culture I inoculated two pigeons.

(All pigeons used were strong, healthy birds, mostly cocks. I selected pigeons knowing that they were prone to diphtheria).

Exp. 5.—Inoculated a pigeon with 20 minims of the *original culture.* It was paralysed in the legs and semi-paralysed in the wings in eight or nine hours, supporting itself on the beak and wings. But it slowly improved after a day.

On the third day a yellow membrane was attached to the right pharynx, which bled on attempting to remove it.

Digitized by Google

On the fifth day the membrane nearly disappeared. Nine days after it was killed because there remained loss of co-ordinating power.

Exp. 6.—Another pigeon *similarly treated* became ill the same day.

In two days the pharynx was covered with membrane which extended to the larynx, and the animal died of dyspnœa between the third and fourth day. Paralysis set in on the second day.

The cocci were found in the blood, and also in the membrane of the throat, together with bacilli and other microbes.

Exp. 7.—A pigeon was inoculated with a mixed culture of No. 6 membrane. The bird was poorly some days, but no membrane in the throat. It had, however, a putrid affection of the gullet.

The inference from the experiments where throat disease and paralysis occurred is that the cocci injected are the real diphtheritic germs. Hence I would call them, *pro tem.*, the *Diphthero-cocci.*

At first I thought the rapid paralysis was due entirely to the absorption of the effete product of the cocci in the gelatine, what might conveniently be called the diphtherin. This I afterwards disproved.

Experiments with the *subcultures* incubated at 90° F. showed *attenuation of the cocci.*

Exp. 8.—A pigeon was inoculated with 20 minims of the secondary culture. In two to three days there were ulcers on the pharynx, with a yellow deposit or membrane.

There was also leg weakness, so that it could not perch. It was well in a week.

Exp. 9.—A pigeon was inoculated with the same quantity of a parsnip infusion, containing a similar secondary culture. The effect was *nil.*

The vegetable infusion was not proper pabulum for the diphthero-cocci.

Experiments were made with a subculture grown for thirty days, at 60° F., with a view to testing *diphtheria as a constitutional or a local disease.*

Exp. 10.—A pigeon was inoculated with 20 minims of the subculture. In two to three days the throat became red, with small white patches. There was leg weakness. In a week it was well.

Exp. 11.—A pigeon was *scratched in the pharynx* and the subculture rubbed on. Slight yellow membrane found on the scratches on

Digitized by Google

the second day but disappeared in a day or two. There was no leg weakness, *and no constitutional effect.* (To be referred to later.)

Exp. 12.—A pigeon was *both scratched and inoculated* as in the last two. On the second day there were distinct small patches of membrane with ulceration. There was also inability to perch. It was well in a week.

The *inference* of the last five experiments is:

(1) Diphthero-cocci in subcultures may become *attenuated* producing only slight sore throat and general weakness.

(2) Diphtheria is more probably *a constitutional* disease than a local.

I made a second series of experiments from a very *malignant case of diphtheria.*

On the *first day* of the little girl's illness, when the membrane was forming in small patches on one tonsil, I inoculated a tube of gelatine by means of a sterilized wire, with which I punctured a small patch.

In eight days at 60° F. *the characteristic appearance occurred in the gelatine.* The minute colonies, the funnel-shaped depression in the gelatine, the slow and turbid liquefaction, with an orange coloured deposit.

It was a *pure cultivation* of the same small cocci. After two days in the incubator at 90° F. I made the following inoculations.

Exp. 13.—A pigeon, injected 20 minims of the culture. Death in eight or nine hours.

Exp. 14.—A pigeon, injection 6 to 7 minims. In ten hours it was paralysed, could not stand or fly. Died in about twenty hours. Diphthero-cocci in the blood. No reliable throat symptoms as died in the night.

Exp. 15.—A pigeon was inoculated with *the washings of the syringe,* less than one minim.

Next day ill, will not feed. Helpless in twenty-four hours, lying on one side.

Whitish *membrane* all over the pharynx, which extended to the larynx. Died in about thirty-six hours.

Exp. 16, was performed to see if the rapid death and paralysis were due to the effete poison of the cocci, *the diphtherin.* Therefore 12 minims of the original culture sterilized by heat were injected. The bird never had any apparent ill effects.

The *inference* must be that the *large dose of virulent cocci* in the

Digitized by Google

blood killed before local throat symptoms could manifest themselves, as in the case of "suppressed scarlet fever." Yet we know that the poison of diphtheria is very depressing, affecting powerfully the spinal cord and medulla. Apparently nature has the power of *eliminating the diphtherin without the cocci.* But when cocci are also present manufacturing fresh supplies of diphtherin in the blood, then the animal dies of the poison.

A third series of inoculations were made with a *pure culture of diphthero-cocci,* obtained from exudation and ulceration of the soft palate on the *ninth day* of the disease in the last case.

Exp. 17.—A pigeon, 20 minims of the above culture injected. In ten hours the animal was quite paralysed, and died in eighteen to twenty hours. The throat was dubious.

Exp. 18.—A pigeon, *half a minim injected.* In two days, red ulceration with *yellow deposit* on the surface occurred round the glottis and on the pharynx. On the third day a thin white membrane came off the palate, leaving an ulcer behind. The bird was ill, but not paralysed. It got well in a few days.

Inference.—As the case progressed the *diphthero-cocci* got *slightly attenuated.* I made a *subculture* of these active germs, but unfortunately it got *impure;* bacilli resembling the *Bacillus subtilis* appeared, yet I *inoculated two pigeons.*

Exp. 19.—The pigeon used in Experiment 11, where local throat inoculation of the diphthero-cocci had been ineffectual five days before, was inoculated with 20 minims. The next day there was paralysis of the legs and paresis of the wings and yellow membrane in the pharynx. On the second day it died.

This was a *complicated experiment.* Was the virus in the subculture of cocci, or in the foreign bacillus, or was it the double dose of cocci in the same bird, calling the local throat inoculation into renewed vigour?

To test the impure subculture, I similarly inoculated another pigeon.

Exp. 20.—The following day it was semi-paralysed. The throat was dubious. On the second day it began to recover, and was quite well in four or five days.

Time forbids that I should describe *a further series* in which five mild cases occurred in one family, and in three of which I got the *typical cocci,* and choosing the most abundant crop, obtained by inoculation, throat ulcers with yellow exudation in a pigeon.

Digitized by Google

Exp. 21.—Having *proved the coccus* to cause both membranous and ulcerated sore-throat, and also paralysis, I next studied the influence of chemicals on its growth. It grows best in neutral, or slightly alkaline gelatine. Acids are injurious to its growth.

The following substances *prevented the growth of the diphthero-cocci* in sterilised gelatine:

Boracic acid	2 per cent.
Salicylate of soda (useless if weaker)	5 „
Hydrargyri Perchloridum	1 to 5000
Carbolic acid	1 to 400
Creolin (Jeyes)	1 in 400
Tinctura Eucalypticus	2 per cent.
Hydrogen peroxide (20 vols.)	2 „
Sodæ Bicarb.	10 „
Benzoic acid	1 „
Antipyrin	5 „
Quinine	10 „
Resorcin	1 to 400
Iodine	1 to 500
Liq. Ferri Perchlor. fort.	2 per cent.
Hydrochloric acid (sp. gr. 1·16)	5 „
Lactic acid (sp. gr. 1·21)	1 „
Zinc chlor.	½ „ 1 to 200
Nitric acid, B.P.	2 „

The following substances were *useless* in arresting the growth of the diphthero-cocci:

Chlorate of potash (saturated aqueous solution)	10 per cent.
Liquor Potass. permanganate	20 „
Salicylate of soda	2 „
Jeyes	1 in 2000
Chloride of lime	2 per cent.
Sulphurous acid	5 „
Hydrochloric acid (1·16)	1 „
Liq. Ferri dial.	10 „
Quinine	5 „
Sulphite of soda	10 „
Hyposulphite of soda	5 „
Sulphocarbolate of soda	20 „
Pot. Iodid.	15 „
Iodine	1 in 1000
Acid. Phosph. dil.	10 per cent.
Sodæ Bicarb.	5 „

Digitized by Google

From this, one sees the *absolute inefficiency of chlorate of potash* and *permanganate of potash*, so much used at present; also the uncertainty of sulphurous acid from its volatility. Also *sulpho-carbolate of soda very inefficient.*

From the fact that dialysed iron is inert, and that 5 per cent. of hydrochloric acid is fatal to the cocci, one must infer that the *benefit of tinct. ferri perchlor.* in diphtheria arises *from the hydrochloric* acid by its local action.

On the other hand, there are *many non-irritating, yet potent antiseptics*, proved by experiment, and also I may say by the bedside; especially boracic acid, hydrochloric and lactic acids, and salicylate of soda.

My experiments were carried on in two houses. There was a cat in each house. *Both cats fell ill* with laryngitis, cough, choking and clawing at the throat, also great debility and paresis. One recovered spontaneously, the other by the use of salicylate of soda. On the other hand, most of *the dead pigeons were given to another cat*, which was unaffected. But here the acidity of the stomach might destroy the germs.

There are many *interesting questions* opened up for discussion:

Is diphtheria a *local or a constitutional* disease?

I think the experiments point to a constitutional disease, primarily, of which the local manifestation is the throat affection.

How does the poison enter the system?

Is it by sowing germs on an inflamed tonsil, or by inhalation of germs into the lungs?

Is it by infected food coming in contact with the tonsils?

Can infected food act through the stomach?

Finally, *what is diphtheria?*

Are the sympathetic sore throats and the ulcerated throats, caught from a palpably true case, also diphtheria?

Are they due to attenuated germs?

What is the relationship then of mild diphtheria to the Infectious Disease Notification Act?

I should not fulfil the purpose of my licence unless I laid stress on the *practical results* of the experiments.

First: It establishes *diphtheria as a constitutional disease.* Hence the importance of *internal remedies*, such as the salicylate early in the disease to act on the germs in the blood. Yet by experience, many, and I myself, have succeeded by local treatment only, but it

Digitized by Google

is with difficulty in severe cases. Therefore both means demand attention.

Second: As to *local treatment*, let us banish chlorate and permanganate of potash for ever.

If we use with frequency watery solutions of the acids, and stronger glycerine preparations of the non-irritating drugs, we cannot fail to succeed.

I have found the steam carbolic spray of value in laryngitis even after the formation of membrane, and lately have used small injections of pilocarpine, one twenty-fifth of a grain, with great success in loosening and bringing away membrane from the larynx.

Pilocarpine also is of value in eliminating the diphtherin from the system, and thus preventing both the cardiac depression and nerve paralysis. *May 5th*, 1891.

Digitized by Google

Table of Inoculation of Diphthero-cocci, &c., into Pigeons, with the Result.

No. of experiment.	Material for inoculation.	Early observations and progress.	Final result.	Inference of experiment.
1	3 pigeons fed with Bacillus liquefaciens viride	In drinking water and bread soaked in cultures	No effect	The liquefying Bacillus harmless by the mouth.
2	2 pigeons fed with Bacilli from diphtheritic membrane	Ditto	No effect	The Bacilli of diphtheritic membrane harmless by the mouth.
3	Inoculation with pure culture of Bacillus liquefaciens viride	—	No effect	The liquefying Bacillus harmless by inoculation.
4	Inoculation with large micrococci from membrane	—	No effect	The micrococci of diphtheritic membrane inert by inoculation.
5	Inoculation with small micrococci from membrane	—	No effect	Ditto.
6	Mixed cocci Bacilli (Löffler's) filaments	Very poorly in about 4 or 5 days	No throat affection; weak, emaciated; died 9th day	The Bacilli of diphtheritic membrane kill by systemic disease.
7	Diphthero-cocci from grey exudation	Paralysis and white patches of membrane on throat in 2 days	Membrane extends to larynx; dyspnœa, paralysis; death on 4th day (diphthero-cocci in the blood)	Diphthero-cocci cause death by diphtheria proper and paralysis.
8	Ditto	Paralysis in 6 hours; in 2 days yellow membrane in throat	After membrane ulceration slowly healed; loss of co-ordinating power remained; killed about 9th day	Diphthero-cocci cause diphtheria proper, paralysis, loss of co-ordination.
9	Subculture of the above diphthero-cocci	In 3 days raw ulcers on throat; weak on legs	10 days after, snuffles and weak on legs	Attenuated diphthero-cocci produce sore throat and paresis.
10	Same subculture, but in vegetable infusion	No effect	No effect	Diphthero-cocci grown in vegetable infusion instead of gelatine absolutely inert.
11	Same subculture in gelatine inoculated	Weak on legs, and throat slightly ulcerated	Well in 3 or 4 days	Same as in Exp. 9.
12	Same subculture in gelatine not inoculated; scratched on throat	Where scratched slight patches next day; ulcerated throat for 1 day	Well in 4 or 5 days	Local infection in throat of diphthero-cocci produce no membrane nor constitutional weakness.

Digitized by Google

No. of experiment.	Material for inoculation.	Early observations and progress.	Final result.	Inference of experiment.
13	Same subculture in gelatine inoculated, and also scratched on throat	In 2 days leg weakness; in 3 to 4 days yellow membrane on scratches	Well in 5 or 6 days	Attenuated diphthero-cocci act feebly if both locally and constitutionally.
14	Impure culture attenuated cocci in pigeon 12	Next day completely paralysed; on second day membrane in throat	Died in about 48 hours	Impure or mixed culture of attenuated cocci fatal, when same pure cocci inert.
15	Impure culture from throat of bird 7	In 2 to 3 days leg weakness; putrid throat affection	Snuffles, no true membrane; recovered in 8 or 10 days	Illustrates some connection between throat and throat.
16	Diphthero-cocci from malignant case, 20 minims	Died in 6 to 9 hours paralysed	No time for throat symptoms	Rapid poisoning of nerve centres from diphthero-cocci.
17	Diphthero-cocci from malignant case, 7 minims	Died in less than 21 hours	No time for throat symptoms	Ditto, corresponds to suppressed scarlatina malignans.
18	Diphthero-cocci from malignant case, less than 1 minim	Thick grey exudation and membrane in 24 hours	Died in 36 hours paralysed	Acute diphtheria proper and paralysis from diphthero-cocci.
19	Impure subculture same as Exp. 14, 20 minims.	Leg weakness next day; throat dubious	Well in 3 days	Attenuation of diphthero-cocci by subculture.
20	Diphthero-cocci obtained on 9th day from same case, 20 minims	In 12 hours paralysis	In 24 hours death	Diphthero-cocci become attenuated as the case progresses, and small dose not fatal.
21	The above, 1 minim only	In 2 days yellow membrane round glottis	Recovered in 4 or 5 days	
22	Diphthero-cocci same as Exp. 16, 17, and 18. Gelatine sterilized by heat, 12 minims inoculated	No effect	No effect	The diphthero-cocci being killed, the diphtherin *per se* is inert, unless decomposed by heat.
23	Diphthero-cocci from a 3rd case, milder	In 2 days membrane on throat; no leg weakness	Well in 4 days	Diphthero-cocci from mild case of diphtheria are attenuated.
24	Cat fed on all the dead pigeons and nothing else for 5 days	No effect	No effect	Though cats subject to diphtheria by inhalation, yet by the stomach probably incapable of infection.

(When not stated otherwise, 15—20 minims of culture in neutral gelatine were inoculated over the pectoral muscles.)

Digitized by Google

ADDENDA.

The *clinical aspect of diphtheria* is so interwoven with its pathology that I wish to make a few observations on this subject.

I would *define* a typical case of diphtheria as a specific inflammation of the tonsils and fauces, with sloughing exudation and ulceration, followed by prostration, and in severe cases by paralysis of certain nerves. The disease is due to micro-organisms.

I conclude that diphtheria must be classed as a true *constitutional fever*, having observed that cases both mild and severe begin with chilliness or rigors, and subnormal temperature; and in the second stage there is a varying rise of temperature.

In the first stage, which varies from twelve to thirty-six hours, there is usually great pain in the tonsil or submaxillary glands, but no pain in swallowing, thus differing from quinsy. There may be no alteration in the tonsil beyond increased redness. It is usually as the temperature rises that the exudation appears on the tonsil.

The temperature may vary from 100° F. to 104° F., and usually subsides from the third to seventh day; but it is no guide as to the severity of the case, not even in fatal cases.

The pulse is, however, of use to indicate the effect the disease has on the constitution. In severe cases, while the temperature remains normal, the pulse may keep up to 120 or 130, with feeble impulse and marked dicrotism.

Among the *constitutional effects* of diphtheria, the general debility, the anæmia, the weakness of cardiac muscle, and the *albuminuria*, are such as might attend any exhausting fever; whereas the paralysis of various nerves, and the loss of co-ordinating power in walking, are results *peculiar to diphtheria*.

The *local symptoms* appear in the following order:

Pain, either in one or both tonsils, and in the lymphatic glands.

Redness of the affected tonsils, spreading to the mucous membrane.

Tenderness of the neck outside.

Grey or yellow slough or membrane, commencing on the tonsil in small patches. The membrane consists of fibrine, leucocytes, epithelium. It contains micro-organisms, some of which may be associated with the disease, but most certainly more gain access from the external world.

Digitized by Google

Swelling and œdema of the adjacent mucous membrane as the disease spreads.

A milky or *grey transparent exudation* forms on the swollen mucous membrane, and passes on to form fresh membrane or slough.

In a few cases I have watched this thin exudation on the tonsil *precede the membrane*, and I attach the highest importance to this early exudation as being *the only true hunting-ground for the organism of diphtheria*.

I have seen this primary exudation form like a veil on the swollen, but unbroken, uvula and soft palate, in a case where one tonsil only was affected, and that was healing, but local painting with boracic was refused. In this case, treated with carbolic spray, the germs could not enter from without. Clearly it was a constitutional disease, and the morbid material of the blood manifested itself locally in this exudation as much as the rash in scarlatina.

Almost as rapidly as the exudation appeared on the soft palate, it also occurred in the larynx, such being indicated by hoarseness, cough, and aphonia, &c. The child had many struggles for breath, but died comfortably in five days, due probably to the depressing action of the diphtherin. I mention this as many state that death is from asphyxia, and with a struggle.

The later stages are separation of the membrane, with or without hæmorrhage, ulceration, and granulation.

One is obliged to recognise at least three types of diphtheria.

(1) *Very mild or sympathetic throats.*—These are often contracted from severe cases. There is the febrile state, with pain and redness of the tonsil. They are *diphtheritic* in the true sense, and capable of giving a severe attack to another person. In April last I had marked proof of this:

A had well-marked diphtheria; B, attending to her, developed a "sympathetic" throat, without any apparent ulceration or exudation, but feverish (TC. 102); C had an interview with B, and was not otherwise exposed to infection, and in four days developed well-marked diphtheria.

(2) *Mild type*, with all the symptoms well marked, but recovering in some cases spontaneously, or, with treatment, in a day or two.

(3) *Severe type* of many grades: cases in which, with active and constant measures, the cases only yield in ten to fourteen days, in

Digitized by Google

some cases invading not only the nares, but also the larynx or trachea.

These cases are commonly fatal. In old times most of them were fatal. But it is the treatment of these which I wish to emphasize, believing that a fatal result ought to be only as rare as in typhoid or scarlatina.

I have noticed in epidemics, where the early cases were severe, that the later cases became mild. Similarly, I have frequently observed mild cases caught from contact with severe or very severe cases. The converse I have observed more rarely.

I was much struck in the last case quoted in my paper, where diphthero-cocci obtained on the first day were most fatal to pigeons; those obtained on the ninth day of the disease were much attenuated. This is a matter of great importance in searching for the specific organism, for observers might get *pure cultures of attenuated and inert diphthero-cocci;* hence the importance of selecting malignant cases, and examining at the onset of the disease.

I also found my *subcultures always became attenuated,* which corresponds to the usual clinical facts.

It is a strong argument against Loeffler's bacillus, that it is almost always fatal, and frequently takes two to three weeks. Such is quite different from the clinical facts of diphtheria, where the organism is either rapidly fatal, or in many cases so attenuated as to be practically harmless.

The treatment of diphtheria.—The *chief treatment should be local;* but in very severe cases, though local means will end successfully, I can testify that internal remedies greatly facilitate recovery.

For years I never gave a drop of medicine, and without a fatal result. But after further study of the clinical aspects, and after scientific confirmation from my experiments on the pigeons, I am bound to regard diphtheria as a *constitutional disease,* and, if so, it demands *internal remedies,* as salicylate of soda, resorcin, quinine, and so on.

In *local treatment* two things are essential. First, to select a *reliable and non-irritating antiseptic.* Second, to make sure of reaching the seat of the disease sufficiently, frequently, and efficiently.

I would recommend for all mild cases spraying frequently with 1 to 2 per cent. of lactic acid, or 5 per cent. of hydrochloric acid, or 2 per cent. of carbolic acid (?), or 1 per cent of resorcin, or 25

Digitized by Google

per cent. of sulphurous acid (?), or 1 to 3000 of perchloride of mercury, occasionally spraying out the nares.

Medicine need not be given in mild cases. The spray should be used *hourly* at first. Chlorate of potash and permanganate of potash to be carefully avoided. Perchloride of iron is useful only on account of the hydrochloric acid. In severe forms, and in children who cannot be sprayed, to paint the throat with glycerine preparation every two or three hours—10 per cent. salicylate of soda in glycerine; saturated solution of boracic acid in glycerine.

On account of its affinity for water, glycerine rapidly penetrates the mucous membrane, carrying with it the antiseptic.

The *treatment recommended by Loeffler*, in 'Deutsche medicinische Wochenschrift' for March 5th, 1891, seems to me *exceptionally harsh and irritating*. He recommends gargles of corrosive sublimate, 1 to 1000; 3 per cent. of carbolic acid, dissolved in 30 per cent. of alcohol; also alcohol and oil of turpentine, to each of which is added 2 per cent. carbolic acid. Also concentrated watery solutions of creasote. These irritating drugs savour very much of the early days of antiseptics, when pure carbolic acid, with putty, were used as surgical dressings.

Some of the above (*e.g.* turpentine) are almost caustic in their action.

As a result of using the more efficient and less irritating drugs, I have found almost every case, however severe, yield to treatment.

In my early days, especially when I have contemplated tracheotomy, but failed to obtain permission, by persevering with measures already described the cases have gradually recovered.

So impressed have I been on this subject, that I am tempted to feel that if a case can be saved it is *possible without tracheotomy*.

I attribute death in two of my cases of tracheotomy to diphtherin poisoning, as *post-mortem* showed all the membrane had been removed from the trachea, larynx, and even fauces.

I strongly urge the carbolic spray or other antiseptic inhalation, iodoform insufflation, and small doses of pilocarpine hypodermically, as soon as the disease invades the larynx.

In *searching for the specific organism*, the condition of the mouth, the fauces especially, and the membrane are of the utmost importance.

In all my cases, I have examined throats which had been *efficiently cleansed* with one or other of the above antiseptics. In

Digitized by Google

this way foreign organisms were to a large extent excluded, and the results must be very different from those obtained in the manner which past observers investigated. While different observers have obtained different results, I cannot too strongly advocate *the pure or aseptic method of investigation.* I also consider that all experiments based on the examination of dead membrane are wrong.

Among further errors of observation, I would refer to the 'Annals de la Policlinique de Paris,' May, 1891. M. H. Giblet finds the *Staphylococcus pyogenes albus* in false membrane, and adds it to "the list of micro-organisms capable of producing false membrane"!!!

Welch and Abbott (in the 'Bull. of Hospital,' ii, 11) state that "every postulate necessary to prove that the specific cause of producing diphtheria is the Klebs-Loeffler bacillus has been fulfilled." Yet in *no one case has this bacillus, on inoculation, produced diphtheria.* Take their own experiments: "Guinea-pigs inoculated with their cultures die in one to five days of *systemic* disease, the bacilli only being found at the point of inoculation," and *no throat symptoms.*

"Rabbits inoculated survive five to twenty days, developing as a rule paralysis," but *no throat symptoms.* But "streptococci were also found in most cases in the diphtheritic membrane."

Loeffler found his own bacilli would develop in eight hours on gelatine. If this be so, how can we rely on membrane which has been twenty hours or even longer in the mouth, which swarms with many varieties of germs?

Though inoculations of the Klebs-Loeffler or any other bacilli may cause death, yet death is not *diphtheria,* and up to the present these experiments with pure cultures of cocci are the only ones in which *membranous sore throat and paralysis have followed inoculation in a distant part of the body.*

Digitized by Google

5. *Hæmatoporphyrin in the urine.*

By S. Monckton Copeman, M.A., M.D.

No apology is, I think, needed for the subject I introduce, imperfect as are the results which have been obtained, since the study of the different pigments which may occur in the urine in various pathological conditions is one concerning which comparatively little is known.

It seemed, then, that what I have to demonstrate might be of interest to some, as being a record of the presence of a hitherto undescribed pigment in the urine, and as directing attention to the likelihood of its occurrence in other cases in which it might be possible to work out the significance of its appearance more fully than has been possible in the present instances.

At present I only know personally of three instances in which this pigment has been found and isolated, the urine from each of which has been examined by Dr. MacMunn and myself. The first two cases were under the care of Dr. Ranking, of Tunbridge Wells, who sent specimens of the urine to Dr. Bristowe, who in turn handed them over to me for investigation. Concerning the third case I will say nothing, as it will probably be published by Dr. MacMunn.

Recently, however, Dr. Vaughan Harley published in the 'British Medical Journal' two cases of abnormal pigment in the urine, of which he gives spectroscopic charts, but the nature of which he failed to determine. From the perusal of his paper it would appear that the pigment he found was really identical with that present in the specimens I have to show, namely, hæmatoporphyrin.

Clinical details may, perhaps, be out of place here, but seeing that the symptoms in all four cases are so exactly similar, it will be well, perhaps, briefly to refer to them.

All four were women, ranging in age from twenty-seven to fifty-four, of whom two were married and two single. Three were markedly thin and emaciated, the fourth anæmic, but not especially emaciated Of the two who were married, the symptoms came on in one within five weeks of her having entered into that state. All four were intensely neurotic, dementia being present in one, and in two there was uterine trouble, while all complained of abdominal and

Digitized by Google

occasionally lumbar pain. In all there had been habitual constipation, often attended with a sense of pressure in the head, one complaining also of photophobia. All came under observation in a stage of extreme prostration, with from time to time inability to move the limbs, although no true paralysis could be detected. In two the symptoms were ushered in with an attack of gastric catarrh, accompanied by retching, and, occasionally, actual vomiting. Nothing abnormal could be found in the state of the heart and lungs in any of the cases, although in two a hæmic murmur was present, and the temperature was normal throughout in all. The skin was for the most part bathed in cold perspiration. Dysuria, and to a certain extent suppression of urine, was a prominent feature, while the small amount that was excreted, averaging about 12 oz. per diem, with occasional ischuria for twenty-four hours, possessed the remarkable characters to which attention must presently be drawn, there being, however, at the same time no trace of albumen, sugar, or bile. Finally, of the four cases, three died collapsed and comatose, while one has recovered, and is now apparently in her usual state of health.[1] Unfortunately, no necropsy could be obtained in any of the fatal cases, so that it is impossible to be absolutely certain that no organic disease was present.

In the first two recorded cases, the fact that both women lived in the same house made me somewhat naturally think that they had perhaps been poisoned in some way, and coal-gas suggested itself as a possibility. I have since heard, however, that they did not sleep in the same room, that they were not related to one another, and that no evidence pointing to the likelihood of poisoning having taken place is forthcoming, the wall-papers having been examined among other things, but with a negative result only.

For the purpose of a sufficient examination of the specimens, it is necessary to have recourse to the use of the spectroscope, and the charts shown[2] (Fig. 20) will give some idea of the appearances presented. The maps are drawn from the examination of the urine from the non-fatal case, but the specimens obtained from the second case, which had a fatal termination, were found to contain almost, if not altogether, the same pigment as the others. The maps, which show

[1] All had been treated with hypnotics of various kinds, chiefly sulphonal and chloral.

[2] Enlarged from drawings kindly made for me by Dr. MacMunn, to whom I am also indebted for the wave-length measurements appended.

Digitized by Google

FIG. 20.

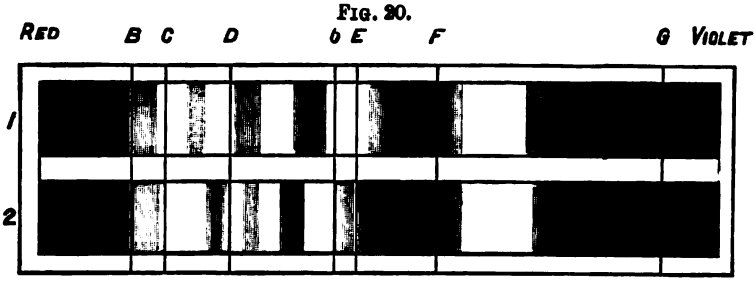

1 = Urine itself. The spectrum of neutral hæmatoporphyrin.

2 = Urine with hydric sulphate, *i.e.* acid hæmatoporphyrin. [After Dr. C. A. MacMunn.] The letters B—G indicate the position of the various Fraunhofer lines as seen in the solar spectrum.

the position of the various bands in their exact relation to the various Fraunhofer lines, are supposed to represent the result of the gradual dilution of the urine, or the examination of different thicknesses, as all the bands are not visible at the same time.

The port wine coloured fluid gave a four or five banded spectrum with the chemical spectroscope, practically unchanged by NH_4,HO or NH_4,HS, while the addition of dilute H_2SO_4 changed it into the spectrum of acid hæmatoporphyrin.

(1) The fluid examined without the addition of any reagent gave a spectrum showing absorption bands, which give the following wave-length measurement:

1st band (?)	λ 653—633 ?	
2nd band	λ 619—605	
3rd band	λ 585—569	
Darker part	λ 583—571	
4th band	λ 549—532	more diluted.
Darker part	λ 547—535	more diluted.
5th band	λ 577—479	more diluted.

(2) With NH_4,HO a slight turbidity was produced. After filtration the third band of (1) was feebler, and the violet end of the spectrum more distinct, while the band in the extreme red was more doubtful.

1st band (if present)	?	
2nd band	λ 619—605	
3rd band	λ 591 or 589—573	
No darker part perceptible.		
4th band	λ 553·5—533·5	more diluted.
5th band	λ 517—494	more diluted.

Digitized by Google

(3) With $ZnCl_2+NH_4,HO$ no distinct fluorescence could be perceived.

1st and 2nd bands . .	?
3rd band . . .	λ 589—571
4th band . . .	λ 555—535
5th band . . .	λ 518·5—494

(4) With H_2SO_4 the fluid became of a darker purple-red colour and the spectrum changed.

1st band . . .	λ 599—590 or 589
Shading . . .	λ 581—569 ?
2nd band . . .	λ 560·5 or 559—544
3rd, a broad ill-defined shading between the green and blue, its darker part perhaps .	λ 520—477
or more diluted . .	λ 501 or 502—483

In the urine of the fatal case the addition of $ZnCl_2$ and NH_4,HO caused a slight shifting of two of the bands, but the fluid showed no fluorescence, thus showing that no urobilin was present, while a slight green fluorescence was noted in the urine of the non-fatal case. The band at F, however, did not shift with these reagents, so that the pigment had not reached the stage of uro-hæmatoporphyrin. The bands do not exactly correspond with those usually assigned to hæmatoporphyrin, so far as it is possible to judge from comparing spectra of alcoholic and aqueous solutions of the respective pigments; Dr. MacMunn has, however, no doubt that the pigment present is a form of hæmatoporphyrin which has been slightly less metabolised than any of the reduction products described by him.[1]

Hæmatoporphyrin, as I need hardly state, is in reality identical with iron-free hæmatin or hæmatoidin, which is frequently found in the brain, spleen, and other organs after the partial absorption of effusions of blood. It is also supposed to be identical with bilirubin, which again is doubtless derived from the colouring matter of the blood; and its appearance in the urine may be due to an unusual disintegration of blood-corpuscles, by which a quantity of hæmoglobin has been set free. The reason why hæmatoporphyrin should have appeared in the urine instead of hæmoglobin, as

[1] 'Journal of Physiology,' vol. x, Nos. 1 and 2.

Digitized by Google

usually occurs in ordinary cases of hæmoglobinuria, is possibly to be explained on the supposition that such hæmolysis was a more gradual process than in the better known affection, lasting, however, for a much longer time than in the usual paroxysm of hæmoglobinuria. In this latter disease, as a matter of fact, we often find that the pigment has suffered a downward change to a greater or less degree, since, as I have shown elsewhere, either hæmoglobin, methæmoglobin, or acid hæmatin may be found in the urine according to the severity of the paroxysm, and the time during which exposure to cold has taken place. From acid hæmatin it is but an easy step to acid hæmatoporphyrin.

For distinguishing these various bodies from one another, the chief dependence must be placed on spectroscopic examination, combined with the simultaneous use of various chemical reagents; but, seeing that it is not every clinical worker who possesses a spectroscope, or, even if so, who would be likely to carry it to the bedside of a patient, it may be worth while briefly to state the manner in which the presence of hæmatoporphyrin in urine may be diagnosed from that of free hæmoglobin, which would give to the excretion a somewhat similar colour.

In the first place the guaiacum reaction affords a very delicate test for the presence of hæmoglobin and methæmoglobin, while hæmatoporphyrin gives no such blue coloration. I am of course aware that this test is not an altogether reliable one, even for blood pigment, as, under some circumstances, pus and milk will give a similar reaction. Still the fact that a urine which appears to contain a blood-colouring matter gives absolutely no result when the test is applied, shows at once that it is not to hæmoglobin that the unusual colour is due.

Then, again, a solution of caustic potash causes no precipitate when added to the fluid, while, if hæmoglobin were present, a brownish-red flocculent precipitate would at once appear.

Heller's test, also, which consists in floating some of the urine on to the surface of nitric acid, yields only a negative result, showing that no albumen is present. No precipitate occurs on boiling, and further, saturation with magnesium sulphate gives no precipitate of globulin. I should, however, state that one specimen, when first sent to me, apparently did contain a small quantity of globulin.

The evidence obtained from the use of such simple tests as I have mentioned would naturally lead one to make further careful

Digitized by Google

examination with a view to the recognition of the abnormal pigment present.

All the specimens of urine were strongly acid, and possessed an odour resembling that of acetone. Another curious point was that decomposition was markedly retarded, some of the specimens showing no evidence of putrefactive change after having remained in my laboratory for months. On standing, crystals of uric acid were deposited, and the percentage of urea was considerably above the normal, a thick ring of crystals of nitrate of urea being formed on floating the urine on nitric acid. This may, however, be accounted for by the small *quantity* of urine passed in the twenty-four hours.

One of the specimens from the non-fatal case was distilled. The distillate was perfectly clear and colourless, and had a still more marked smell than the urine itself. On the application of Chautard's test, consisting in the addition of an aqueous solution of magenta decolourised by sulphurous acid gas to the distillate, a barely perceptible coloration was obtained, but with acetone itself only a faint purple developed. Tested for acetic acid with ferric chloride, no reaction was obtained.

Since the pigment present is undoubtedly derived from the colouring matter of the blood, it is perhaps strange that there should be no evidence in the urine of the presence of the proteid molecule of hæmoglobin from which it had in the first instance been split off. We know that in mild paroxysms, in a person the subject of hæmoglobinuria, proteids which I have shown to consist largely of globulin may alone appear in the urine, the system being capable of dealing with the small amount of pigment which must be at the same time discharged into the blood, as is evidenced by the simultaneous destruction of corpuscles taking place. In an allied affection, pernicious anæmia, on the contrary, although considerable hæmolysis may be caused, there is no discharge of proteids in the urine, although urobilin, either normal or pathological, is usually present in excess.

Dr. William Hunter, following other observers, has shown that in this disease, unlike what obtains in hæmoglobinuria, the destruction of corpuscles takes place in the portal instead of the systemic circulation; and thus the fact that the constituents of the broken-down corpuscles are dealt with by the liver before they reach the kidneys accounts for the different state of the urine in the two affections

Digitized by Google

It is further believed that such destruction in the portal system is due to the absorption of poisonous products, possibly ptomaines from the alimentary canal.

Now it will be remembered that in all the cases I have mentioned habitual constipation was complained of in every instance; so that may it not be that we have here to deal with an affection somewhat allied to pernicious anæmia in nature, though more rapid in its onset and subsequent course? Although I throw out this suggestion it would of course be absurd to insist too strongly on it, since in none of the cases were any observations made on the number of corpuscles or the amount of hæmoglobin present in the blood.

In connection with this hypothesis I ought to state that Dr. Hunter found in a case of pernicious anæmia a considerable amount of pathological urobilin in the urine at certain periods of the disease. Seeing that this body is practically identical with stercobilin, he considered that this observation supported the theory of absorption from the intestinal tract, and states—though apparently from this one observation—that the presence of this body in the urine is of the utmost diagnostic importance.

I have found the same pigment present in five cases of pernicious anæmia, one of which is at present in the wards of St. Thomas's Hospital; but in a number of other cases of the same disease none could ever be detected, although there was an increased amount of normal urobilin in the urine—observations which have been confirmed by Dr. Mott in cases investigated by him.

Now, just as normal urobilin is apparently a reduction product of pathological urobilin, so is this latter of hæmatoporphyrin; so that if the two former pigments are usually found in considerable amount in pernicious anæmia, it is not perhaps altogether a matter of surprise that the more unusual pigment hæmatoporphyrin should be met with in an apparently allied disease.

Hoppe-Seyler has shown that these apparent reduction products are, however, often formed in the body by what are really a series of oxidative changes; so that, viewed in the light of this theory, hæmatoporphyrin is a less *oxidised* body than urobilin, and consequently its appearance would indicate a greater interference with the normal body metabolism even than pathological urobilin. This would, again, fit in with the more rapid course witnessed in the cases which I have endeavoured to review.

Digitized by Google

In conclusión, I may perhaps be again permitted to state that my only excuse for bringing before this Society the results of so imperfect an investigation is to call the attention of other observers to the appearance of this peculiar pigment in the urine, further cases of which will doubtless shortly be recorded now that the subject has been brought to their notice. *January 20th*, 1891.

---

6. *Cultivation of psorospermia (a preliminary communication).*

By Sheridan Delépine, M.B.Edin.

[With Plate VII, figs. 3, and 4; and Plate VIII.]

Bodies which resemble closely several forms of gregarinæ or psorospermia have been described during the last fifty years by numerous observers as occurring in various organs in man. I need only refer by name to those observers to show that, notwithstanding the comparative rarity of their observation, they must be received as indicating the possibility of the infection of man by these parasites. They have been seen or described by *Gubler* (1858). *Virchow*, *Dressler*, *Sömmering*, *Sattler*, *Silcock*, in the liver; *Kjellberg*, *Eimer*, *Rivolta*, *Grassi*, in the intestine and fæces during life; *Lindemann*, *Knoch* on the hair and in several internal organs; *Künstler* and *Pitres* in the pleura; *Hadden*, *Cobbold*, *Eve*, in the kidney and ureters; *Robin*, *Lebert*, *Lindemann*, *Bollinger*, *Darier*, *Wickham*, *Hutchinson*, *jun.*, *Bowlby*, in the skin, specially in molluscum fibrosum and Paget's disease of the nipple. Even admitting a certain number of erroneous statements, in presence of such a series of observations there can be little doubt as to the occasional presence of psorospermia in human tissues. It would, therefore, be unwise to reject without inquiry the suggestion which has been made by several observers that psorospermia had an important share in the production of certain lesions, such as Paget's disease of the nipple or epitheliomata. I must own that for years I, like many others, have been struck with the appearance of certain large bodies occupying or not the central parts of cell nests, and often present in epitheliomata. I had generally considered those

Digitized by Google

large round or oval bodies as the results of some degeneration of the cells; but when the possibility of the presence of psorospermia in epithelial tumours was suggested, it seemed to me that this hypothesis might possibly be correct. I have for the last two years observed a large number of epitheliomatous tumours of external and internal organs, in which such bodies were present, and have found that, although there was a remarkable resemblance between them and undoubted psorospermia, they entirely failed to respond to any of the chemical tests which I have found to give definite reactions with certain forms observed in the rabbit's liver. I have also failed to find any of the developmental forms which can so easily be seen side by side in the rabbit's liver and intestine. The tumours in which I have noticed the presence of the psorospermoid bodies were—1. Several epitheliomata of the lips and tongue. 2. Two epitheliomata of the œsophagus. 3. A primary carcinoma of the bile-ducts and liver. 4. Epitheliomata of the skin. 5. An epithelioma of the vagina. 6. Two epitheliomata of the vulva.[1]

In all these cases I have seen forms which seemed entirely similar to some varieties of psorospermia; yet, for the reasons I have already given, in none did I feel justified in recording them as evidences of the existence of psorospermia in epithelial growths. On the other hand, I had observed absolutely similar lesions in parts where the presence of psorospermia seemed entirely out of the question, and the existence of degenerative processes was equally evident.

In presence of such a state of things I thought that it would be desirable to find whether one could easily, by cultivation, obtain changes which might be used partly for diagnostic and partly for inoculation purposes. Kauffmann had already, in 1847, succeeded in cultivating psorosperms in water, or rather he had observed that the contents of the capsules divided into four spores when placed in water. On repeating this experiment I was surprised to find that this phenomenon was observable only in a small proportion of the parasites obtained directly from the liver of a rabbit. In fact, when pure water was used the changes consisted only in a swelling of the capsule, which became gradually very transparent and almost invisible, whilst the protoplasmic contents assumed the appearance

[1] See communication made at the International Congress of Hygiene and Demography, 'Brit. Med. Journ.,' 1891, ii, p. 362.

Digitized by Google

of a large, very granular amœboid mass, with sometimes an indistinct nucleus. Such masses seemed to become more and more coarsely granular or vacuolated, until they broke down into clumps of granular *débris*. The few oviform bodies in which subdivision of the contents occurred, according to the description given by Kauffmann, did not seem to undergo any further change.

As the psorosperms in which these indications of division occurred were in the midst of other organisms which were breaking down, I suspected that those in which evidences of division had occurred were living on the substance of their decaying neighbours.

This first experiment indicated clearly that water is not a very suitable material for cultivating psorosperms.

I then attempted to cultivate psorosperms in interlamellar films,[1] so as to be able to follow the changes occurring in individual organisms kept in various media. Psorosperms taken from a single psorospermic nodule (which had become cystic by accumulation of serum in the lumen of the diseased and obstructed bile-duct) were placed in bile, in exuded serum, in glycerine, and nutrient gelatine, and kept at a temperature of about 20° Centigrade. In less than a week the majority of the psorosperms placed in serum showed complete or partial subdivision of their protoplasma into four or more round or oval bodies, similar to those described by Kauffmann.[2] Many of those kept on nutrient gelatine showed the same changes, but the process was not quite so advanced, nor did it affect quite so large a number of psorosperms as in the serum cultivations. The parasites kept in bile did not seem either to decay or to show any tendency to multiplication. The protoplasmic contents which, on removal from the liver, occupied, in most cases, the whole capsule, generally contracted rapidly so as to form, in the middle or at one end of the capsule, an oval or spherical body, generally full of highly refracting granules of rather large size. In fact, they had taken the form which attracted specially Hake's attention.

In the serous fluid taken from the nodule which had been selected for the purposes of inoculation there were, in addition to the ordinary encapsulated form, numerous naked parasites. These varied much in size, but were all smaller than the encapsulated form. They looked like gelatinous and homogeneous masses of

[1] See 'Lancet,' June, 1891.

[2] Note the absence of toxic properties of the serum in this case.

Digitized by Google

protoplasm, had a kind of yellowish colour, and some were evidently endowed with amœboid motion.

The same body was also found in the stomach and intestine, but in these organs the smaller varieties were predominant; whilst in the bile-ducts all the stages between the small, hardly defined jelly-like mass, and the large oval bodies with or without a nucleus or large granules, could also be found abundantly. The largest naked forms were of about the same size as the smallest encapsulated ones.

These naked forms kept well for weeks in bile, but I was not able to satisfy myself that any had become encapsulated. This may, however, come from my having been unfortunate in the selection of the individuals I was specially watching day by day; for, looking at the cultivations as a whole, I am under the impression that the total number of encapsulated psorosperms had augmented before the end of the month.

The same phenomenon seemed to occur in serum, but here again I was not able to watch the actual passage from the naked into the encapsulated form.

In the nutrient gelatine I soon lost sight of the naked gregarinæ.

The changes occurring in the encapsulated oviform bodies kept in serum, glycerine, and nutrient gelatine were mainly the following:

1. The contents contracted, sometimes showing distinct alterations of shape.

2. The granules or some internal network became in some arranged equatorially, so as to leave two clear poles; this was, however, distinct only in a few cases.

3. The protoplasmic mass divided into two oval or irregular bodies, capable of amœboid motion.

4. Then each of these subdivided into two again, and as this did not always occur at the same time, there were often three oval or round or irregular protoplasmic bodies free within the capsule. The capsule itself became larger, probably owing to accumulation of fluid within its cavity. At this stage one part of the protoplasma of the daughter-cells was often quite homogeneous and transparent, while the other part was finely granular. Small round bodies, strongly refractive, were generally visible in the granular part of the protoplasm.

5. When four daughter-cells or spores were present within the

Digitized by Google

mother-cell or cyst, they generally assumed for a short time a regular oval form, and they looked like diminutive oviform psorosperms. They seemed to have a thin capsule, but I have not been able to see it. They were almost entirely composed of a clear translucent elongated body folded upon itself, and often containing the round refractive bodies alluded to above. In some cases they seemed really to contain a folded or hooked body, resembling to a certain extent the *falciform corpuscles* of Eimer, Schneider, and other observers; *but this was only a transient appearance.*

6. These four bodies sometimes subdivided still further, so that the original capsule contained five, six, and even more small rounded bodies, which generally had a bright globule in their midst, and looked very much like small lymph-corpuscles.

7. The next change was, however, rendered manifest by a great alteration in shape, the four or more daughter-corpuscles becoming elongated and exhibiting slow amœboid motion, taking in turn vermiform, pyriform, and round shapes, and moving from one place of the capsule into the other. Whilst these changes were taking place the vermiform bodies occasionally became twisted together or seemed to coalesce, so that at times the cyst looked as if it contained only one thick spiral or wavy filament. There were in these amœboid bodies generally two of the bright bodies alluded to above.

8. At the same time bodies similar to these small bright round bodies became abundant in the nutrient material surrounding the psorosperms. They were at first smaller than red blood-corpuscles. They were often attached to the capsule, as if just passing through it; it was not very uncommon to find one at each pole of the capsule. I have, however, been unable to watch their actual escape.

9. At the end of three weeks many of the small bright corpuscles which had thus apparently become free showed distinct proof of multiplication, being often in pairs as shown in the plate. These were of the same size as, and resembled closely, some of the small bodies found in the stomach and intestine.

One of the most remarkable features of this process of reproduction, as observed under artificial circumstances, is the apparent possibility of the various stages described occurring indifferently after division of the mother-cell into two, three, four, five, six, and perhaps more daughter-cells.

Digitized by Google

By drawing the small bodies at intervals with the camera lucida I have been able to satisfy myself of their alteration of shape and of their movements from one place to another, so that I am certain that they are not the result of a degeneration process and of a breaking down of the protoplasma.

The accompanying sketches (Fig. 20, and Pl. VIII), all drawn to the same scale and copied from accurate drawings taken with the camera lucida, show the most important forms which I have observed and alluded to above.

I have so far failed to discover anything like any of these stages in the tumours I have examined. I feel, therefore, very sceptical as to the nature of the psorospermial bodies I have seen in them, and which are quite similar to those observed in Paget's disease of the nipple, as I have been able to ascertain by the examination of the specimens of Mr. Bowlby and Mr. Hutchinson, jun.

FIG. 21.

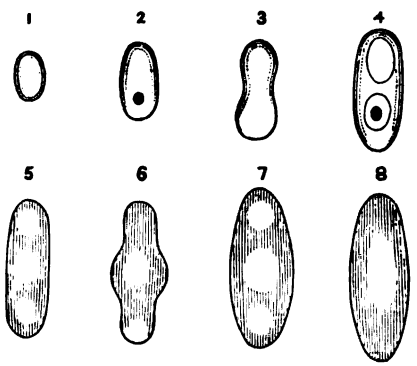

Young psorospermia found in the stomach of rabbits. 1, 2, 3, 4, 5, 6. Forms which seem to lead to 7, 8, but the nature of which is only surmised by analogy. 7, 8. Typical young psorosperms.

I think, however, it would be injudicious to speak positively before numerous attempts have been made to cultivate the suspicious cells found so abundantly in Paget's disease of the nipple and some epithelial tumours. By publishing a simple method capable of yielding satisfactory results in the case of true psoro-

Digitized by Google

Digitized by Google

DESCRIPTION OF PLATE VIII.

To illustrate Dr. Delépine's paper on the Development of Psorospermia. (Page 371.)

(All the figures were drawn by the author with the camera lucida from fresh specimens obtained from the stomach, duodenum, large intestine, gall-bladder, bile-ducts, or cultivations; they have all been reduced to the same scale = × 1000. The first eight figures, representing chiefly the forms found in the stomach, are in the text.)

FIGS. 9—14.—Forms found in the duodenum, bile-ducts, and gall-bladder (and also in other parts).

FIGS. 9—11.—Naked forms, apparently motionless, found chiefly in bile.

FIG. 12, 13.—Very common forms, both in the intestine and in the liver.

FIG. 14.—Form generally observed after the psorosperms have been allowed to stand on the slide, probably the result of contraction of the protoplasm.

FIGS. 15—19.—Forms observed in cultivations during the first few days (within the first week).

Fig. 15.—Protoplasm contracted within the capsule and showing differentiated parts, the arrangements of which suggests karyokinesis.

FIGS. 16, 17, 19.—Division of the protoplasmic contents within the capsule, each amœboid mass thus produced is endowed with amœboid motion.

FIG. 18.—Appearance observed several times, and possibly indicating some kind of conjugation.

FIGS. 20—29.—Forms observed in cultivations during the second week. (Many of these were already visible during the first week, and in many cases did not alter rapidly after the second week.)

FIG. 20.—Young amœboid germs in a state of active amœboid motion.

FIGS. 21, 22.—Capsules containing young psorspermia or pseudo-navicellæ, in some of which the *falciform or sickle-shaped* body is distinct. Of all the stages this is the one which remains evident longest.

FIGS. 23—26.—Further changes occurring in cultivations within the capsules, but which probably, under ordinary circumstances, would have occurred after liberation of the germs.

FIG. 27.—Germs showing distinct amœboid motion. Forms observed in cultivation during the second, third, and fourth weeks.

FIG. 28.—A few of the forms observed early.

FIG. 29.—Forms found abundantly by the end of the first month in the nutrient material about the capsules. The passage of these bodies through the capsules was not observed.

Digitized by Google

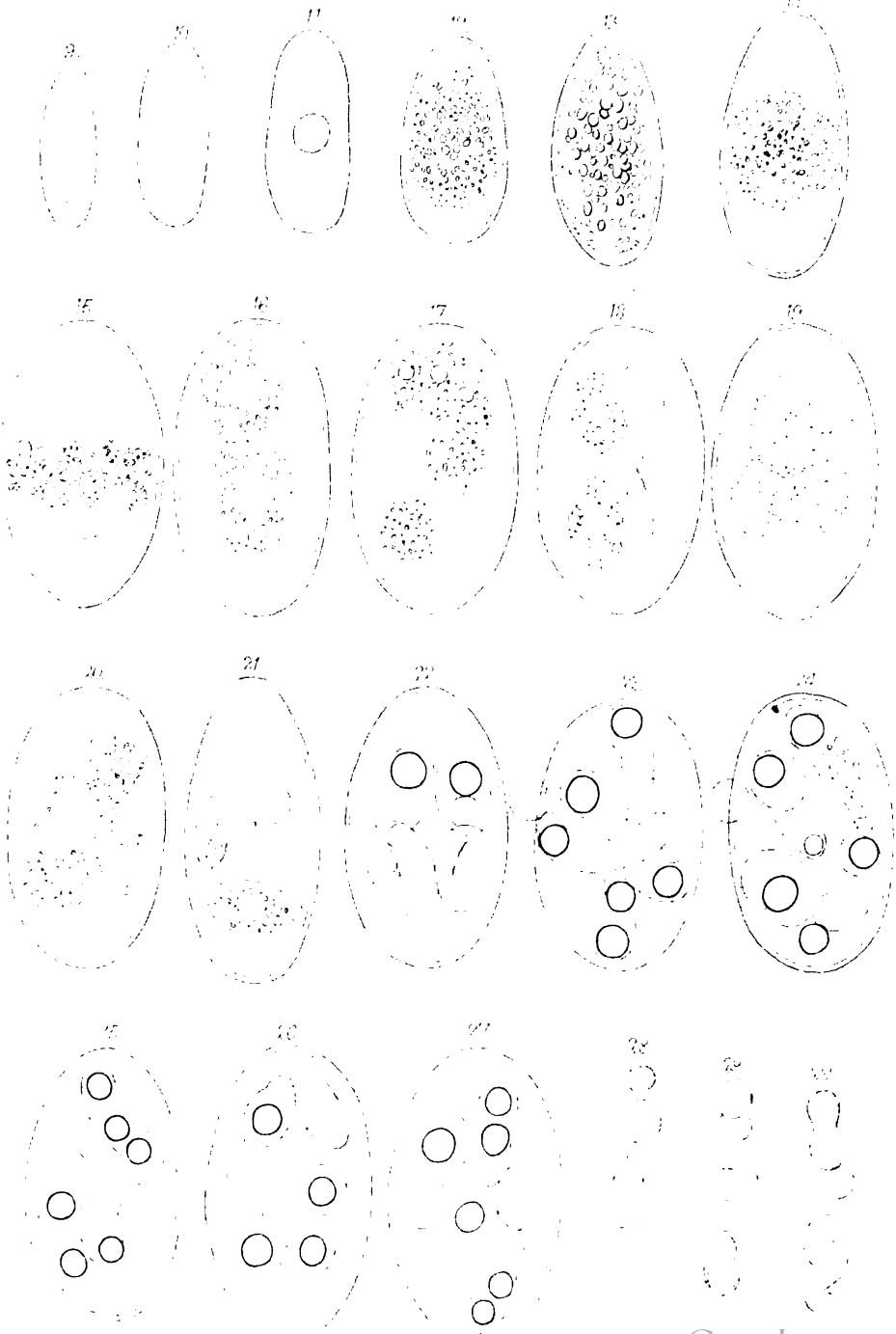

Digitized by Google

Digitized by Google

spermia, I hope to encourage others to try cultivation experiments in all cases where the presence of psorospermia is suspected; and I trust that in this way a sufficient amount of information may be obtained to allow of a definitive settlement of this question. *May 23rd*, 1891.

Note.—I have purposely avoided to allude here to the meaning of the changes I have described, and to their bearings upon the modes of propagation and infection. I would refer those who take an interest in the question to my previous paper in the Pathological 'Transactions,' where the opinions of the most competent observers are discussed, with some bibliographical references.

---

7. *Inoculation experiments with psorospermia.*[1]

By Samuel G. Shattock and Charles A. Ballance.

Although the results of the following experiments are negative we have thought it worth while to record them, in order that others who take up the same inquiry may be led, perhaps, to modify the methods adopted, or to experiment either with other forms of psorospermia, or upon other classes of animals than those used by ourselves.

Our experiments were undertaken with the view of seeing whether any, and if so what, lesions could be produced by the inoculation of psorospermial material; and this we were led to do in consequence of Darier's statement that Paget's disease of the nipple is a form of psorospermosis, and of that author's views as to the relation of psorospermia to carcinoma. The investigations of Darier and of Wickham in Paris, and J. Hutchinson, jun., in London, on Paget's disease of the nipple, although highly suggestive, require extension before this disease can be held to be a form of psorospermosis; and

[1] Towards the expenses of this research a grant was made by the Scientific Grants Committee of the British Medical Association.

Digitized by Google

much more so is this true before carcinoma can be regarded as due to the same parasite.

In this, as in other cases, the four requirements laid down by Koch must be fulfilled, or at least more than the first (the demonstration of a microbe in the blood, juices or tissues) must be forthcoming, especially, too, when the demonstration of the first itself is not convincing or beyond criticism.

It will of course in future be the object of every observer, into whose hands a case of Paget's disease may fall, to endeavour to carry on a culture from the infected epithelium, and from this to reproduce the disease, either in the human subject or in one of the lower animals. And this is still more imperatively demanded, since the issue is so much larger and more important, when it is alleged that carcinoma is due to psorospermial infection.

Not to discuss, however, mere probabilities or the theoretical questions involved, we will recount our experiments. These consisted in taking the psorospermial material from the livers of rabbits just killed, and with this inoculating (under chloroform) the inner surface of the ears of rabbits, dogs, and monkeys. Rabbits we chose especially, since they offered the best chance of receiving infection. The liver of almost every rabbit presents one or more psorospermial nodules at its surface or in its substance, in which an abundance of the organisms admits of easy demonstration; and although general infection does not, under ordinary circumstances, arise in the rabbit, still the localised growth of the parasite proves the animal to be its ready host. In addition we threw large quantities of psorospermial material into two dogs by intra-venous injection, but without inducing any disease of the lungs or other viscera, although the animals were allowed to live five or six months after the experiments.

We experimented with four rabbits.

May, 1890, at the Brown Institution, we selected a healthy, well-nourished rabbit; the right ear was scored freely on the inner aspect after shaving and washing, and into the incisions were rubbed the cheesy or pultaceous contents of many of the psorospermial nodules in the livers of rabbits recently killed. The livers of a series of recently killed rabbits were removed and placed in the incubator; from these certain were selected, the psorospermial nodules incised and the material picked out and transferred to the ear. No dressing was applied. Four weeks

Digitized by Google

afterwards there were fine white lines of cicatricial tissue marking the incisions made by the lancet, and two small, hemispherical, firm elevations, the larger with a smooth shining surface; there was no obvious increase in redness except by transmitted light. A week later the opposite ear of the same animal was vaccinated in a similar way. The ear became covered with a dry scab, which separated within a fortnight, exposing an irregularly raised and red surface. The small eminences, before noticed on the opposite ear, had not increased in size. The swellings of both ears persisted *in statu quo* until the animal was killed six months later, no ulceration having occurred in either. On dividing the ears it could be seen by the naked eye that the swellings were due to the presence of projecting processes of firm white cartilage, continuous with the broad lamella which lies in the pinna, and this was confirmed by microscropic examination. The swellings were due to nothing but reparative hyperplasia of the injured cartilage, which had been scored or even divided in the scarification, and no psorospermia or their traces were present. The epidermis was completely continuous, and presented the normal characters.

With two other rabbits we performed a similar experiment, and with like results; one was kept for six months, the other for three.

In a fourth rabbit we made a long valvular incision on the inner side of the left ear, and into this inserted the psorospermial material. The wound healed by scabbing. Four weeks later there was a raised line in the course of the incision, with adherent blood-scab. Three weeks after this, in the lower half of the incision, projecting between the edges of the skin, which had quite healed, was a somewhat prominent ridge 1 mm. in breadth, of a faint pink colour, and quite smooth, though here and there raised in small eminences. The animal was killed a month later, the parts having remained *in statu quo*. A section showed the linear ridge to be due to a reparative hyperplasia occurring from one edge of the incision in the cartilage, the divided surfaces of which had undergone some lateral displacement. The epidermis was continued over the cicatricial tissue, which was itself devoid of papillæ.

In October, 1890, we vaccinated both the ears in two monkeys, adopting the method of scarification, and that also of long valvular incisions. Seven months afterwards there was no sign of the experiments in the ears of either. We have also practised similar

Digitized by Google

experiments in the dog; at the end of six months no signs of infection were to be seen; the wounds healed by scabbing. On one occasion also we injected subcutaneously 60 minims of distilled water, which had been boiled and allowed to cool, and in which were suspended the contents of several psorospermial capsules. No inflammation ensued, and six months afterwards no trace of the experiment was discoverable on *post-mortem* examination.

Upon two dogs we experimented by intra-venous injection. Psorospermial material suspended in sterilised water or salt solution was thrown into the internal jugular vein in considerable quantities through a glass pipette. No immediate symptoms resulted, both animals remaining quite well till they were killed five and six months later. *Post-mortem* examination showed all the organs to be healthy; a very careful inspection was made of the lungs, but they presented no induration or other signs of embolism.

In May, 1890, we commenced some experiments also on the artificial culture of psorospermia taken from the livers of recently killed rabbits; the material was transferred from the nodules to the surface of glycerine agar on the platinum loop. After six months' incubation at 37° C. no change in size or appearance of the transferred particles had occurred; the tubes remained quite free of other growth. We found the same in regard to nutrient gelatine kept at the ordinary room temperature. In broth cultures made in the same way and incubated we have not observed any increase in the transferred material, although the fluid has remained quite clear and free of other microbes. After five months' incubation the broth had remained quite clear; microscopic examination of the sediments, showed no psorospermial bodies.

As the fluid most like that in which the organisms naturally thrive, we prepared tubes of rabbit blood serum by discontinuous sterilisation, using the medium in the fluid state and inoculating as before noticed. After eleven months' continuous incubation the microscopic examination of the sediment showed in large numbers psorospermial bodies of the forms commonly met with in the rabbit's liver. Although it was clear that the organisms had remained alive, we have not as yet observed any certain evidence of their multiplication. The forms presenting themselves were those in which the centre of the psorospermial body consisted of a sharply circumscribed mass of highly refractive granules, those in

Digitized by Google

which the contents of the capsule were throughout granular; and some in which the refracting substance took the form of large wedge-shaped, closely apposed blocks. In other instances the granules, although not filling the capsule, were not gathered into a regularly spherical central aggregate. The double nature of the capsule was oftentimes very distinct; that is to say, there was present an outer layer which had dehisced or split in different directions, exposing an inner, which formed a sharp limitary membrane to the contents of the capsule. There were present also many free granules, some of considerable size, like those within the capsules from some of which they had evidently escaped.

May 19*th*, 1891.

---

8. *On the non-contagiousness of cancer.*

By Walter K. Sibley, M.B.Cantab.

The words infection and contagion are terms which, though of daily occurrence, are often so loosely used, that it will be better to briefly state how they are employed in this communication. An element is common to both—namely, germs: in infection the germs are capable of transmission by floating in the air, or through the medium of fomites; but in contagion they are inseparable from the animal products thrown off from the diseased part—that is to say, they are only capable of transmission by direct contact. The classification is artificial, but the distinction is convenient. It has never been held that cancer is infectious in the way above understood by the term, but some observers have maintained that it is contagious, and apparently for this reason; namely, that where two surfaces are in contact, a primary cancer on the one surface is sometimes followed by a secondary cancer on the corresponding position. The regions where this has taken place are the lips, vocal cords, the labia of the female external genital organs, and the opposite surfaces of the urinary bladder, &c. In the abdominal cavity it would sometimes appear that pieces of a primary growth may drop off and take root on other

Digitized by Google

regions of the peritoneum, but these cases are very problematical. Some observers even believe in the spread by contagion from one person to another, and quote in support some cases of malignant disease of the os uteri and of the penis.

Now it is well known that the seat of a primary carcinoma is often determined by chronic irritation. This is well seen in the lips, by pipes with rough mouth-pieces, or by nails or other foreign bodies frequently held there; of the scrotum from irritation of soot, probably with rough clothes; in the intestine by cancer mostly occurring at those sites where there are constrictions or flexures; in the gall-bladder by the presence of stone. It also appears that stones in the gall-bladder may be the determining cause of primary carcinoma in the head of the pancreas, for in a very large proportion of these cases gall-stones have been found in the gall-bladder. So also in the urinary bladder from stone or urinary deposit, one observer believing that even residual urine is a sufficient cause.

In addition to these examples taken from the human subject, in a paper read before this Society last session it was shown how psorosperms in the bile-ducts of the rabbit's liver caused by their irritation a multiplication not only of the epithelium, but also of the bile-ducts themselves, giving rise to small adenomatous tumours.

The occurrence of a secondary growth opposite a primary one, as quoted above, must be due either to direct contagion or to constant irritation. But it was seen that chronic irritation often determined the seat of the primary growth. Hence it is far more likely that the chronic irritation by, and not the contagion from, the primary growth is the cause of the secondary lesion. The seat of the primary growth is no doubt often determined by local injury; still more might it be expected that the seat of a secondary deposit may be determined by the same cause. For instance, the presence of an epitheliomatous ulcer on one lip might itself be sufficient mechanical irritation to the region of the other lip, in constant contact with it, to cause the development of a secondary growth there, not through any special or specific contagious property of the carcinomatous growth itself, but simply because of the irritation produced by its presence.

The following case which I recently saw, throws some light on this question. A man with an epitheliomatous ulcer around the

Digitized by Google

base of an isolated, prominent, lower molar tooth, had a small ulcer of the same nature on the inside of the cheek, with a considerable extent of apparently quite healthy mucous membrane intervening. This second ulcer did not come in contact with the primary one, but rested against the crown of the same tooth. It would appear, then, that the seat of the primary ulcer was determined by the carious tooth, and the seat of the secondary one by the tooth also, and not by the primary growth.

In the case just described, it would seem that the seat of the primary growth had been determined by the presence of a prominent partially carious tooth, in a subject with a very strong predisposition to cancer. A second ulcer is determined a few weeks later by the irritation of the crown of the same tooth against the buccal mucous membrane. Had the second ulcer occurred on a slightly lower level, it would have appeared to have arisen from contact with the primary one; but when I first saw the patient this was clearly not the case, the ulcerated surfaces not even coming in contact with the movements of mastication.

Were it possible for direct contagion to occur, we might expect that carcinomatous growths could be transplanted into the lower animals, but all experiments in this direction have so far not given very positive results. Most of the recorded cases of the inoculation of cancer elements into lower animals show purely negative results (Dupuytren, Valentin, J. Vogel, Virchow).

Quite recently a long series of experiments of this nature were communicated to the Royal Society by Messrs. Ballance and Shattock.[1] These experiments were of the character of transplantations rather than of inoculations, and as a result of them the authors state, "So far all the experiments have yielded negative results."

The first man to publish a positive result of experiments of inoculation was B. Langenbeck,[2] who was supposed to have produced multiple cancer tumours in the lungs of a dog by the injection of some fresh cancer juice from a tumour of the arm of a man into the blood-vessels of the dog.

After him, Follin and Lebert[3] stated that fourteen days after the injection of the juices from a breast cancer into the jugular

[1] 'Proceedings of the Royal Society,' vol. xlviii.

[2] Schmidt's 'Jahrbucher,' Bd. xxv, s. 99.

[3] Lebert, 'Traité pratique des malades cancereuses,' Paris, 1851, p. 136.

Digitized by Google

vein of a dog, they found a certain number of distinct cancer formations in the heart and liver.

So, again, Hanau[1] of Zurich states that he transferred squamous carcinoma from one rat to another, the inoculated animal dying within three months of the disease.

Of Langenbeck's observations Virchow writes as follows:[2]—"I have myself examined the microscopical specimens of the case of lung tumour. They have more the appearances of that form of spontaneous cancer I have myself found in dogs, than that of the cancer elements as found in man."

On the other hand, it would appear that sarcomata have been successfully inoculated; as, for instance, the case of C. O. Weber,[3] who injected into the veins of the thigh of a dog the elements from a medullary sarcoma of the upper jaw of a man. Fourteen days afterwards he found a large tumour of the nature of a medullary sarcoma at the seat of inoculation.

More than one observer has claimed to have discovered a germ or bacillus of cancer. The most generally recognised experiments were those of Scheuerlen, of Berlin, who in 1887 read a paper before the Medical Society of Berlin describing his so-called bacillus of cancer, which he had produced by artificial cultures, and which grew very plentifully on potato; and Francke is stated to have corroborated this. Subsequently, among others, Baumgarten showed that the bacilli in question were the result of contamination, and in fact were the ordinary potato bacilli. More recently Kubasoff, of Moscow, has asserted that a bacillus can be cultivated on coagulated blood-serum which will produce tumours in rabbits and cats after inoculation. We must, however, wait for the confirmation of these experiments.

To sum up, I believe that secondary growths sometimes occur started by primary ones, not through any contagiousness of the latter, but merely from the mechanical irritation these cause.

To quote from Mr. Jonathan Hutchinson, "Cancer is not due to the introduction of any special material from without into the system; there is nothing specific in its nature, it is simply a modification of what occurs in chronic inflammation. Cancer occurs

[1] 'Centralblatt für Chirurgie,' No. 42.

[2] Virchow's 'Krankhafte Geschwulsche,' Bd. i, s. 87.

[3] Weber, 'Chirurgische Erfahrungen u. Untersuchungen,' Berlin, 1859, s. 289.

Digitized by Google

in old people or in an organ which has become old; for instance, the mammary gland in the female grows old before the rest of the body. In senility chronic inflammation with overgrowth of tissue is very common, and as a variety of this cancer also frequently occurs. It sometimes happens that in very old people all the stages between chronic inflammation and cancer may be seen in the same individual, so that it is not always easy to say which processes are inflammatory and which cancerous."

Literature.

Follin and Lebert.—'Traité pratique des maladies cancereuses,' Paris, 1851, p. 136.

Weber.—'Chirurgische Erfahrungen und Untersuchungen,' Berlin, 1859, s. 289.

Langenbeck.—'Schmidt's Jahrbucher,' Bd. xxv, s. 99.

Virchow's 'Krankhafte Geschwulschen,' Bd. i, s. 87.

Scheuerlen.—'Berlin. klin. Wochen.,' 1887, s. 935.

Hahn.—'Berlin. klin. Wochen.,' 1888.

Senger.—"Studien zur Aetiologie des Carcinoms" ('Berlin. klin. Wochen.,' 1888).

Senn.—"Surgical Relations of Micro-organisms" ('Trans. of the American Surgical Assoc.,' 1888, vol. vi).

Wehr.—'Trans. of the 18th Congress of German Surgeons,' Berlin, 1889: "Weitere Mittheilungen über die positiven Ergebnisse der Carcinomüberimpfungen von Hund auf Hund."

Platon I. Kubasoff.—'Proceed. of the 3rd General Meeting of Medical Men at St. Petersburg,' 1889, No. 44.

Darier.—'Progrès Médical,' vol. xvi, 1889.

Hanau.—'Centralblatt für Chirurgie,' No. 42.

Ballance and Shattock.—'Proceed. of the Royal Soc.,' vol. xlviii, 1890.

Digitized by Google

9. *A case of leprosy, with remarks on the nature of the lesions found in the lungs.*

By Sheridan Delépine, M.B.Edin., and Ch. Slater, M.B.Cantab.

GENERAL SUMMARY.

PAGE

I. Preliminary remarks 386
II. History of the case 387
III. Post-mortem examination 389
A. Skin—macroscopic and microscopic examination . . 389
B. Bones and articulations 395
C. Pharynx, larynx, and trachea 395
D. Lungs and pleuræ 397
E. Heart and pericardium 401
F. Gastro-intestinal canal and peritoneum . . . 401
G. Liver 402
H. Spleen 403
I. Genito-urinary organs 404
K. Supra-renal bodies 404
L. Thyroid body 404
M. Lymphatic ganglia 404
N. Nerves 405
IV. Discussion of the case 406
A. General remarks: ætiological, clinical, and anatomical . 406
B. Nature of the lung lesions 408
α. Evidence of various observers . . . 409
β. Statistics 410
γ. Our own observations 412
1. Value of various criteria . . . 412
2. Distribution of the *Bacillus lepræ* . . 415
3. Variability of the characters of the *Bacillus lepræ* . 418
4. Nature of leprous lesions . . . 420
V. General conclusions 420
VI. Bibliographical appendix 422

I. Preliminary Remarks.

The case forming the subject of this communication came under the care of Dr. Cavafy at St. George's Hospital in August, 1888. While the patient was in the wards we examined on

Digitized by Google

several occasions many of his cutaneous lesions for the purpose of discovering bacilli, and if possible of cultivating these organisms. On the death of the patient one of us had opportunity to remove portions of various organs. Dr. Cavafy, knowing that we had taken some interest in the case, very kindly gave us permission to make what use we thought fit of the material thus obtained, and also of the notes which had been collected whilst the patient was under treatment. In this paper we do not wish to give an exhaustive account of all our observations, or to repeat what has already been well described in former cases, as this would render the communication unwieldy. We therefore confine ourselves here to a general survey of the lesions, of the distribution of the bacilli in the various organs, and especially to a consideration of the pulmonary lesions. For some time before his death the patient had suffered from symptoms similar to those of rapidly advancing phthisis, and the question arose whether this was due to an extension of the leprous process to the lungs or to a superadded tuberculosis; a question we did not feel able to resolve by an examination of the sputa. This question was naturally pursued in the examination of the *post-mortem* material.

II. History of the Case.

The following is a short *résumé* of the case, based on the patient's statements and the notes taken in hospital.

J. R—, aged 24, admitted into St. George's Hospital on August 25th, 1888. He was born in India, on the Coromandel Coast, of English parents. His family seems to have been free from tubercular taint. When still a baby he was taken to St. Thomas's Mount, in Madras Presidency, and remained there until he was seven years old, when he went to England.

Nine years later, when aged sixteen, he returned to India, and was quartered at Bellary, in Madras. Lepers are said to be common there.

Five months after his return he noticed swellings in both cheeks, which remained for six weeks and then disappeared. Swellings then appeared on the front of both thighs, which were painful and prevented walking. During this period, which dates from March, 1880, he suffered from continued fever, and was in hospital from March to August of that year.

Digitized by Google

He then spent two years in the hills, during which time no fresh swellings appeared, while the sites of the old ones became pigmented.

He was then sent back to Bellary, and again suffered from continued fever for three months.

In 1884—four years after the first outbreak—swellings appeared on the back and legs.

In 1885 the voice was noticed as altered.

In 1886 the first phalangeal joints enlarged, and he was in hospital for laryngeal catarrh. During this time "lumps" developed rapidly—sometimes in a few hours; and the diagnosis of leprosy was, according to the patient, first made.

In 1887 he was discharged, and there was very little change in his condition until shortly before his admission, when he began to suffer from cough and night sweats.

On his admission in August, 1888, he had a typical leonine aspect, with hairless face, thickened subcutaneous tissue of brow, nose, and cheeks, and large and pendulous ears. The nasal bridge was also depressed. The skin was smooth and of a sallow colour. The trunk was covered with discrete tubercles, both superficial and deep. There was a scab on the right elbow, and a scaly patch over the left, while numerous tubercles and maculæ were situated on the extensor surfaces of the upper arms. The skin over the back of wrists and hands was thickened, reddened, and scaly. The first phalanges were enlarged, and the nails convex and split longitudinally in the middle line. There were also tubercles on the thighs, together with scars of an old ulcer on each ham. Over the ankles and lower part of the legs there were several small ulcers with raised edges, covered with feeble granulations which exuded a moderate amount of pus.

Two or three small anæsthetic patches were noted on the anterior surfaces of the arms.

At the time of his admission the signs of pulmonary disease were extremely slight.

During September and October, 1888, several attempts were made by us, independently and together, to cultivate the *Bacillus leprræ*.

The patient improved somewhat in hospital until he left in the winter of 1888. He then seems to have suffered severely from privation and cold, and, after a short time at St. Thomas's Hospital,

Digitized by Google

returned on May 29th, 1889, to St. George's Hospital, suffering from extensive lung disease. After some time a pneumothorax developed, and the patient died on July 13th.

During the second period of the patient's stay in the hospital the sputum was examined on many occasions by both of us, and always found to contain bacilli.

These bacilli varied considerably in number. At times they were extremely abundant, and often formed clumps of a size seldom seen in ordinary tuberculosis. It was also common to find them grouped in small epithelial-looking cells—an appearance which, though met with occasionally in tuberculosis, is by no means frequent.

III. Post-mortem Examination.

The body was very thin, and had an offensive smell differing from that of simple putrefaction.

A. *Skin: macroscopic appearances.*

The skin was generally, but unevenly, darker than normal, dirty and rough-looking. The hair was very thin all over the body and almost entirely absent from the face, there being no eyebrows, eyelashes, or hair on the lips and chin.

The *face* presented, in typical form, the usual appearances associated with tubercular leprosy. The ears were much deformed and nodulated, and the lobule enlarged and pendulous. The border of the right helix was ulcerated for about one inch of its extent. The bridge of the nose was depressed.

On the *trunk* there were numerous maculæ and tubercles, and some leucodermic patches. The most marked maculæ were in the left hypochondriac region; and while some of them were uniformly brown all over, others had become white in the centre and had a thin pigmented zone at their margin. Many of these maculæ were evidently over very flat and indistinct tubercles, while others were apparently true maculæ. The white centre of some of the pigmented patches was distinctly depressed.

On the *limbs* the skin was pigmented, dry, scaly, uneven, and dirty-looking as elsewhere, but in addition presented numerous destructive lesions in the shape of ulcers and fissures. Amongst

Digitized by Google

the most noticeable was a small ulcer on one of the knuckles of the left little finger, and fissures at the level of the phalangeal articulations. There was also a marked shrivelled leucodermic patch, surrounded by a zone of pigmentation, over the second phalanx of the left little finger.

There were pigmented scars about the legs and ankles, and among these were two very evident ones about 2 inches in diameter over the shin of each leg. There were also four smaller ulcers over the right trochanter, which seemed to correspond each to a single tubercle whose central part had become necrosed. The largest of these ulcers was oval, and measured about $\frac{3}{4}$ inch in diameter, the others being smaller. Owing to their occurring in the centre of a nodule their edge was raised, but it was not clear whether there was any true inflammatory thickening. These ulcers had a very regular round or oval shape, with a very abrupt border and a bottom comparatively smooth, and occupied by a layer of granular *débris*. The skin around was distinctly pigmented.

Several specimens of skin were taken for microscopical examination. They were selected for the purpose of following the various steps of the processes leading to the lesions just described, and included—

1. Skin of the back of the wrist, slightly pigmented, dry, and scaly-looking, with small granular swellings, difficult to see but easy to feel, and not presenting typical leprous tubercles or very marked thickening.

2. Skin of abdomen with a leucodermic patch in the centre of a very slightly raised pigmented patch (macula ?).

3. Skin of ulnar side of last phalangeal joint of left little finger with a fissure.

4. Skin over first phalangeal joint of little finger with a very small ulcer which had begun in a fissure, and was covered with a scab.

5. Ulcer of ear, which was apparently spreading. (This is the only ulcer examined in whose discharge bacilli were at all abundant.)

6. Ulcerated tubercles over the great trochanter.

It will be evident from this list of lesions that the various parts of the skin were most unequally affected. The most marked lesions were observed in the head, arms, and legs. The skin of the trunk was less affected than that of the extremities, and the proximal segments of these less than the distal.

Digitized by Google

Microscopic examination.—The slightly nodulated skin of the back of the wrist can be taken as a type, to which the skin of the other parts of the body may be compared.

The *epidermis* is uneven in thickness, being generally thinner over the slight nodules, and thicker in the intervening shallow furrows. Some of the cells of the rete Malpighii are swollen or even vacuolated, and there is, generally speaking, an increase of pigmentation of the deep cells. This increase is most conspicuous sometimes at the sides, sometimes over the centres of the nodules. The opening of the sweat-glands is generally obliterated.

The *cutis vera* is considerably altered. The superficial papillæ are flattened, especially over the nodules, while the whole membrane presents an unusually homogeneous appearance. It is uneven in thickness, and presents at intervals nodular projections which correspond with those felt by the finger during life. All through the corium, but especially in the midst of the swellings, a large number of angular bodies are found; some of these are evidently cells with nuclei, others are of doubtful nature. These cells form flattened fusiform tracts between bundles of fibrous tissue, and look like small epithelioid cells. Under a high power they have a granular appearance, are very translucent, and seem swollen. With logwood and eosin they stain faintly, sometimes staining more with one and sometimes with the other of these dyes. Many are vacuolated, and have at least one comparatively large rounded clear space in their centre. Among these small cell-groups, other large, generally oval, though sometimes round and almost cylindrical bodies can be seen. Most of these large oval bodies (leprous cells) are vacuolated, while many have a very large central vacuole, looking much like the lumen of a duct or vessel. This is itself surrounded by a thick granular wall, in which smaller rounded vacuoles are found. These bodies stain faintly with logwood and eosin, and are stained pink with picro-carmine. After the action of this last stain they are seen to contain bundles of short fibrils, which have sometimes a very definite arrangement. At the periphery of such masses there is sometimes a group of nuclei, but generally the oval masses are separated from the walls of the cavities containing them by a clear space, and seem to be quite loose in that cavity. In the deeper layers of the skin these masses, large and small, seem often to be grouped round the atrophied sweat-glands. This almost complete atrophy of the sweat-glands gives

Digitized by Google

to the deep layers of the skin a peculiar homogeneous appearance. Here and there long angular spaces are found, filled with degenerated cells and fatty granules. These spaces are surrounded by fibrous walls, and seem to have been vessels.

The *fatty subcutaneous tissue* is affected much in the same way but less than the cutis.

After staining such sections with carbolised or anilinised fuchsin for from 15 minutes to 24 hours, and decolourising with sulphuric or nitric acid, a prodigious number of bacilli having all the characters of those of leprosy are brought out. These bacilli are most abundant in the cutis vera, and especially in the deeper parts of that structure. They are also pretty abundant in the subcutaneous tissue among the fat lobules. They are found as usual either free between cells, or in the epithelioid cells described as forming long tracts, or in the large vacuolated cells or masses which are the so-called leprous cells. They also form small clumps in the superficial portions of the cutis. Some of the small masses are spindle-shaped, like ordinary fixed connective-tissue corpuscles, while others are round but generally smaller than leucocytes. Large masses of these bacilli are also found in the large degenerated tracts which are seen in the deeper parts of the skin in some places.

These bacilli differ much in appearance. The free ones and those which are contained in small cells are, generally speaking, short and straight, and stain readily, but are comparatively easy to decolourise. They are very distinct, owing to the parts surrounding them being easily decolourised or taking well the counter-stain. In the leprous cells the bacilli are longer, more beaded, and grouped in fasciculi which have often a very distinct arrangement in relation to the vacuoles. The substance separating these bacilli is difficult to decolourise, and the bacilli themselves seem to stain of a deeper colour than the short discrete ones, and they are also much more difficult to decolourise.

Many of these large leprous cells evidently occupy the lumen of lymphatic vessels which they distend, but some undoubtedly originate in the midst of the tracts of smaller epithelioid cells, some of which, either by coalescence or by growth of the bacilli, gradually become larger. Even in the lympathic vessels the bacilli seem at the beginning to grow in the endothelial cells. The nucleus of cells in which numerous bacilli are found stains badly or not at all, and appears in many cases as a vacuole on the surface of which the

Digitized by Google

bacilli are grouped. When the bacilli are very few it is, however, sometimes possible to see them in one part of the protoplasma of a cell which is still distinctly nucleated. In some cases such a cell has several nuclei at the periphery of a large mass of vacuolated protolasma, in which a few groups of bacilli are visible also. These cells are really giant-cells.

A few small groups of bacilli or individual bacilli are found in the walls of blood-vessels, chiefly in those of the veins and capillaries; they can be seen distinctly to grow on the endothelial lining. As has been previously noticed, the cuticle seems to be almost always free from bacilli, even over those parts where these come quite near to the deepest layers of the rete Malpighii. There are, however, a few exceptions to this rule.

The skin of the wrist, which has just been described, contained a number of tubercles which, for leprosy, were small, being scarcely larger than ordinary tubercles. It was in these tubercles that the leprous cells were the most abundant.

The skin of the abdomen, in the region of a leucodermic patch with a pigmented somewhat raised border, showed very similar but less extensive lesions. The epidermis corresponding to the depressed pale centre was very thin and contained but little pigment, while the border of the patch was thicker and deeply pigmented.

The pigment was situated in the deep cells of the rete Malpighii, and had all the appearances of melanin.

The true skin is less altered here than in the last part described, but is a little thicker than normal. The sweat-glands are less altered than in the other regions examined, but are generally surrounded by tracts of small cells containing many bacilli. Many of these are also in leprous cells. The leprous cells are less abundant in this region than on the back of the wrist.

Skin with a fissure (little finger).—The fissure after section is found not to extend deeper than the horny layer of the epidermis, which is thickened and lamellated in that region. Immediately under that fissure there is a large mass of leprous cells and of bacilli, free or in epithelioid cells. The bacilli come in contact with the epithelial cells of the rete Malpighii, but do not seem to penetrate into them. The papillæ are flattened in that region, but on both sides and at a very short distance from the fissure the papillæ are large again, and the rete Malpighii hypertrophied and much pigmented.

Digitized by Google

Skin with a small ulcer covered with a scab (little finger).—The cuticle is destroyed over a very narrow area; on both sides of the small fissure-like ulcer the epidermis is thickened and pigmented. The bottom of the ulcer is formed by a little granulation tissue, covered with very little granular *débris* and a scab. Bacilli are extremely abundant both under the ulcer and around it; but although they come quite near the epidermis in the neighbourhood of the lesion, yet *no free bacilli are found in the granulation tissues nor in the scab.* A few leprous cells are near the bottom of the ulcer, but are certainly small and very few compared with those found in the adjacent corresponding parts. No *leprous cell is found among the products accumulated on the surface of the small wound.* The subcutaneous tissue, tendons, and periosteum, as well as the bones covered by the skin just described, all contain a large number of bacilli. The cutis is much congested, and the walls of the distended capillaries are literally covered with the parasite. The walls of the veins contain groups of bacilli, and some of these are even seen in the endothelium lining the lumen of the vessel. Some arteries have their intima thickened, and have also bacilli in the other layers of their wall.

The skin of the ear shows very much the same lesions, but much exaggerated in intensity. The accumulation of bacilli, both discrete and in leprous cells, is extraordinary; and these bacilli, both free and in cells, are also pretty abundant in the granulation tissue forming, and in the pus or exudation covering the bottom of the ulcer. A few bacilli are also found penetrating into the epithelial sheath of hair follicles and the outer strata of sebaceous glands. This has also been noted previously by Babes.

The skin over the trochanter with rounded excavated ulcers, apparently following necrotic softening of tubercles. The epidermis covering the border of these ulcers overlapped slightly the edge of the lesion, and the bottom of the ulcer was covered with granular *débris*, among which were a few masses of micrococci, but no *Bacillus lepræ.* The bacilli were, however, pretty abundant not far below the surface, and distributed in the usual way in the true skin and subcutaneous tissue. Some of the arteries were almost entirely obliterated by endoarteritis, and had in their walls many bacilli; these were, as in other places, most abundant in the perivascular lymphatics. Many of the veins of that region were filled with coagulated blood, or simply a network of fibrin.

Digitized by Google

B. *Bones, articulations, &c.*

The two most noticeable features at the autopsy were the depression of the ridge of the nose, and the looseness of the phalangeal joints.

The only bones and joints taken for *microscopical investigation* were those of the fingers.

In a section including a phalangeal joint it is found that there is distinct osteomyelitis, leading to the enlargement of a number of Haversian spaces, and to the accumulation within them of very vascular cellular tissue, in the midst of which are numerous large fat-cells, and large oval and round vacuolated cells, which look like other leprous cells, except that the bacilli which they contain are more granular-looking, and less densely packed than in ordinary leprous cells. The bacilli are found extending as far as the cartilage, but do not penetrate into that tissue.

The *periosteum*, the *fibro intra-articular disc*, the *ligaments*, all contain bacilli, but neither the cavity of the joint itself nor the articular cartilages contain any bacilli. The tendons of the long flexors and extensors also contain a few, but very few, small groups of bacilli, which seem to be in tendon corpuscles.

C. *Pharynx, larynx, and trachea: macroscopic examination.*

The mucous membrane of the pharynx and larynx was much affected, and the lesions found in that membrane were very similar to those found in the skin.

The epiglottis was unevenly thickened, irregular in outline, and thick. Its mucous membrane was rough, and presented superficial erosions or ulcers, especially on its posterior aspect, and below the cushion. Here the ulceration extended between the anterior extremity of the vocal cord, in the region of the central fossa, down into the larynx. The false and true vocal cords were also much thickened, as well as the mucous membrane covering the arytænoid cartilages. All these parts had a rough, or granular, somewhat eroded look, with the exception of the true vocal cords, which had retained part of their natural smoothness.

The mucous membrane of the lower part of the larynx and of the trachea was irregularly thickened, and showed numerous shallow ulcerations or erosions,

Digitized by Google

Microscopically, the epithelium is found shed from the surface of the mucous membrane almost everywhere, except at the level of the true vocal cords. Below the vocal cords these superficial layers of the mucosa are infiltrated with small cells and partly necrosed. The mucous glands are much altered. Their epithelial cells are generally in a state of disintegration, except those of the ducts, which have in many places multiplied and are very clear. The mucous and submucous layers are infiltrated with groups of epithelioid cells like the corresponding part of the skin; but these small cells are, generally speaking, less numerous; whilst large multinucleated masses of protoplasm resembling closely giant-cells, but much vacuolated, are, on the contrary, more abundant than in the skin.

The thyro-arytænoideus muscle is in a state of interstitial myositis, with considerable atrophy of some of its fibres. Some of the small nerves are in a corresponding state of interstitial inflammation.

Bacilli are extremely abundant just beneath the surface of the true vocal cord, where they are found both discrete and in leprous cells. They are less abundant above and below the cord, where the mucous membrane is denuded. A few bacilli penetrate into the epithelial strata, but whether they are in epithelial cells or between them is extremely difficult to ascertain. Some seem to be in small wandering corpuscles; but as nuclei are extremely seldom evident in the small rounded masses to which we allude, it is difficult to affirm that they are actually what we suppose them to be. A few bacilli are undoubtedly free in the ducts of some mucous glands. A few bacilli, isolated or in clumps, are also found among the granular products covering the ulcerated membrane of the larynx. The great bulk of the bacilli is, however, found, as in the skin, at some distance from the surface, and apparently in the lymphatics surrounding blood-vessels, glands, and nerves, and also in the connective-tissue corpuscles or lymphatic spaces of ordinary fibrous connective tissue.

The laryngeal muscles are also invaded by the parasite, which is mostly located in large cells situated in the endomysium separating the muscular fibres; in some instances, however, the bacilli have passed through the sarcolemma, and seem to form colonies, either in the muscle corpuscles or between the sarcolemma and the muscular fibre, which in such cases is much altered. These bacilli are very short and thick, many almost oval and worm-

Digitized by Google

like; they, however, give the typical reaction of the *Bacilli lepræ.* The bacilli found in the larynx are, generally speaking, very short and thick.

D. *Lungs and pleuræ.*

Pleuræ.—There were dense fibrous adhesions over the greater part of the upper lobe of the left and of the right lungs. These adhesions were more extensive on the left than on the right side. Both pleuræ, but more specially the left, contained an excess of serous fluid. The visceral layer was, generally speaking, thickened, more opaque, less even and shiny than normal, even in those parts where there were no adhesions.

Lungs.—They weighed together 4 lbs. The right one was heavy, and did not collapse on the pleura being opened. The lower lobe of the left one had retained part of its elasticity. The right lung was in a general state of intense congestion and induration; the lower lobe was œdematous. All through the organ there were small, pale, creamy yellow patches, some hardly larger than a millet seed, but many, especially near the apices of the upper and lower lobes, very much larger. These cheesy-looking patches had often a distinct arborescent arrangement, and seemed to be occupying the lumen of small or large bronchi. At the upper part of the lower lobe, and also at the apex of the right lung, there were cavities filled with soft caseiform products which communicated with bronchi. One of these cavities was almost cylindrical, measuring over 1½ inches, and seemed to be a bronchus with degenerated walls.

The upper lobe of the left lung was almost entirely replaced by a large cavity full of curdy-looking blood-stained fluid, containing a large number of small cheesy-looking masses. This cavity was surrounded by dense fibroid lung tissue, undistinguishable in some places from the thickened pleura. Septa of the same nature subdivided the large cavity into compartments. Both the walls and septa were covered with thick cheesy-looking matter, and contained in their depth cheesy-looking nodules. The walls were also deeply congested.

The lower part of the upper lobe, which was not entirely destroyed, was consolidated, and contained a very large number of large cheesy nodules.

The lower lobe was beset with pretty large cheesy-looking tubercles or broncho-pneumonic patches, between which the parenchyma was congested and indurated.

Digitized by Google

There was no evidence, either in the right or in the left lung or pleura, of anything resembling a miliary tubercle. The general characters were those of a very extensive cheesy broncho-pneumonia, such as is observed in cases of tuberculosis of the lungs beginning in the bronchi or peribronchial tissues.

This impression was entirely confirmed by *the microscopical examination*. The least affected bronchi were in a state of acute inflammation, with shedding of their columnar epithelium and filling up of their lumen with purulent-looking exudation, the epithelial cells being shed so rapidly as to form in rare cases continuous masses in the midst of the small-cell exudation which distends their lumen. The mucosa and adventitious coats of such bronchi are infiltrated also, and contain a large number of epithelioid cells. The neighbouring alveoli are also distended, sometimes with almost nothing but large epithelioid cells, very transparent and vesicular-looking, sometimes by blood or coagulated lymph more or less altered.

In somewhat more diseased bronchi the walls are still visible, as well as some degenerated tracts of epithelial cells; but the lumen, which is now irregular and not very distinct, is occupied mainly by breaking-down cells and fatty *débris*. The infiltrated alveoli are numerous, and their contents either undergo the same changes as those of the bronchi, or else the congested alveolar walls become thicker, owing to the accumulation of cells and congestion of their vessels. The epithelioid cells occupying the alveoli form continuous epithelial-looking masses without undergoing degeneration. In such regions the appearance is not unlike that of an adenomatous mass. The cells, although staining pretty well, have a distinct tendency to coalesce. In none of the lesions described so far is it generally possible to discover any bacillus staining like that of tuberculosis or leprosy. Small clumps of cocci, staining badly with methylene blue and sometimes with hæmatoxylin as also some slender bacilli staining with methylene blue, were thought to be present in some of the bronchi, but this did not seem to be the rule.

Larger tracts of degenerated cellular products, having relations to surrounding parts similar to those just described as connected with bronchi, correspond to the larger cheesy masses which were so distinct at the *post-mortem* examination. In the midst of such patches it is often possible to distinguish some remains of a canal

Digitized by Google

surrounded by more or less distinct meshes, and these appearances doubtless indicate the previous existence of a bronchus and of the alveoli surrounding it. At the periphery of such masses there is usually a zone of badly formed granulation tissue, and in or outside that zone most of the alveoli are distended with epithelioid cells, many of which seem to have coalesced to form giant-cells, which in some cases are of prodigious size. A few smaller giant-cells are undoubtedly formed in lymphatic vessels, and look more like those generally observed in miliary tubercles. As a rule, however, the giant-cells are not surrounded by any fibrous tissue, dense or loose, but either lie distinctly in a cavity or are surrounded by more or less distinct epithelioid cells, distending some cavity which in many cases is clearly an alveolus. Nearly all these giant-cells contain a large amount of carbon particles: a few appear to contain some bacilli, staining blue.

All the parts surrounding these large cheesy patches are intensely congested, the vessels looking at least as large and as numerous as in advanced cardiac congestion. In many places this is accompanied by hæmorrhages or by exudation of coagulable lymph into the few alveoli which are not yet filled up. It is in the centre of these large cheesy patches that bacilli can be found abundantly, and sometimes form large bushy masses (*bacilles en broussaille*).

These bacilli are extremely variable in characters. In some places they are short and thick, straight or curved, and in other places long, slender, and beaded, or not. They, however, in the most advanced lesions have most unmistakably the same staining reactions as the *Bacillus lepræ* found in the most typical lesions of the skin and other organs. In addition to these, however, there are often associated organisms, staining more or less distinctly with methylene blue, sometimes coccoid, sometimes bacillary in character.

Bacilli giving the typical reaction with fuchsin are generally found abundantly in the centre of the lesions. There is often a distinct zone of blue organisms in the region intermediate between the central colony and the granulation tissue limiting the lesion. We merely mention the fact as being of possible importance, but do not wish to discuss it more fully here.

When these masses have reached the size of a large pea they begin to soften in the centre, and when this happens, the red bacilli become so abundant as to form an almost pure cultivation,

Digitized by Google

if it were not for the presence of the blue cocci and bacilli to which we have just alluded, and of which a few clumps are found here and there. The cheesy-looking material, which has been described as covering the walls of the large cavity in the left lung and forming the small masses floating in the blood-stained fluid, was found immediately after the *post-mortem* to be, practically speaking, composed of nothing but bacilli, staining extremely readily, and resisting decolorisation as well as the bacilli found in the skin.

The other lesions found in both lungs were connected with the pleura and interstitial tissue.

The serous and the subserous layers of the pleura were considerably thickened nearly all over the left lung, much less so on the right side.

The serous layer was also in part covered with a fibrous exudation. The thickening is mainly due to the formation of a very hyaline, rather cellular, and very vascular fibrous tissue. Giant-cells are pretty abundant in the pleura, and seem to be in the lymphatic vessels, as all transitions can be seen between long tracts of nuclei, in a cylindrical homogeneous mass occupying the position of a lymphatic vessel, between parallel blood-vessels, and the usual form of giant-cells. None of these giant-cells seem to form the centre, or to enter into the formation of any neoplastic-looking lesion; and the tissues immediately surrounding them do not differ from those wherein giant-cells are found.

In the subserous layer of the pleura swollen epithelioid cells are found, and sometimes lymphatics with ordinary lymph-corpuscles.

On the surface of the serous layer, bacilli, free, or in a few cases distinctly enclosed in small epithelioid cells, are found in moderate amount; most of these are short and thick, but some are long and slender.

The interlobular and interalveolar septa, when they are not involved in the lesions already described, are intensely congested and infiltrated with epithelioid cells, so that they are often undistinguishable from the contents of the alveoli.

Many of them are distinctly thickened through increase of fibrous tissue, which is, generally speaking, very homogeneous-looking and very translucent; this is specially noticeable under the thickened pleura.

Digitized by Google

E. *Heart and pericardium.*

The heart was small, and weighed 7 oz.; it was contracted, and felt very firm; its cavities contained a few small pale clots, and were apparently normal; there were no valvular lesions. The pericardium contained a slight excess of greenish-yellow serum.

F. *Gastro-intestinal canal and peritoneum.*

There was no trace of peritonitis. The serous coat of the intestine and stomach was smooth, and looked healthy. The mucous membrane seemed quite healthy as far as the lower part of the ileum. The lowest part (twelve inches) of the *ileum* was congested. There were also in that region numerous small nodules closely resembling swollen solitary glands. Peyer's patches were not specially affected.

The cæcum, *the ascending* and *transverse* parts of the colon were much ulcerated. Sixteen large ulcers were counted at the time of the *post-mortem*, but numerous small ulcers and swellings were also observed. The distribution of the large ulcers was as follows:

Three were found two inches beyond the ileo-cæcal valve; one large compound one, evidently resulting from the coalescence of smaller ones, 4 inches beyond the ileo-cæcal valve; six medium-sized ulcers, 16 inches beyond the ileo-cæcal valve; six medium-sized ulcers, 28 inches beyond the ileo-cæcal valve.

Of these ulcers, those which seemed not to have been produced by the coalescence of a number of small ones measured from $\frac{1}{8}$ to $\frac{1}{2}$ inch in diameter or a little more.

They were mostly round or oval, and they all seemed to have begun in small nodular swellings similar to those found in the small intestine. Owing to these the smallest ulcers were raised above the level of the mucous membrane, and when a little larger they had a raised but soft border, not undermined. The bottom was generally not very rough, and often quite smooth. Some of the larger ulcers had, however, some distinct granular or tubercular-looking nodules near their border. The intestinal walls were not much thinner than normal at the level of the ulcer, the ulceration apparently not extending much beyond the mucosa, the muscular coat never being exposed or even affected. The serous coat seemed also free from disease.

Digitized by Google

Microscopically.—The lesions seem to be chiefly due to a large accumulation of small round-cells in the mucous membrane of the intestine. These cells do not extend very far into the submucosa; they at first occupy the spaces between the Lieberkühn's follicles, of which they cause wide separation and rapid atrophy. In the lesions which have not yet ulcerated it is difficult to find any bacillus. In the ulcerated ones bacilli are found abundantly among the granulation cells and the granular *débris* forming the bottom of the ulcer. These bacilli are much more easily decolourised than those found in the skin, but they do not differ from the discrete ones in form or general appearance.

Among the cells surrounding the ulcer there are some giant-cells which, as in the laryngeal lesions, seem in many cases to have originated in lymphatic vessels. These cells do not seem to form part of any granuloma resembling a miliary tubercle. The blood and lymphatic vessels in the neighbourhood of the lesions were searched for bacilli without any positive result.

G. *Liver.*

This organ weighed 52 oz., and was unaltered in shape, rather pale, and very firm. Its surface was smooth. The capsule seemed more opaque than normal, and presented a fine mottling, which on section of the organ was seen to correspond to a general increase of stroma, and gave to the organ a most typical appearance. Small dots and lines, resembling much the trabeculæ of the spleen, and giving to the surface of section a shreddy appearance, were distributed evenly all through the organ. The dots were smaller than miliary tubercles.

Microscopically.—The liver is found to be in a state of advanced and very general interstitial hepatitis. Glisson's capsule is generally increased, and presents nodular swellings of fibrous tissue, in which a great number of large and small vacuolated cells are found around the blood-vessels and between the bile-ducts. The bile-ducts seem increased in numbers, and are very conspicuous; some are obstructed by shed epithelial cells. These lesions are very similar to those of biliary cirrhosis, but the fibrous tissue is different in appearance, owing to the large number of vacuolated cells looking much like fat-cells. The hepatic cells are either in a state of proliferation, or are infiltrated with fat; many are much atrophied.

Digitized by Google

Bacilli are found in the vacuolated cells of Glisson's capsule, more especially around the blood-vessels, and evidently situated in lympathic spaces. They are also pretty often found between the liver-cells in the midst of the lobules, where they seem to be within or sometimes outside the blood capillaries. Bacilli are also found all through the thickness of the walls of even pretty large portal veins, surrounded by large masses of bacilli; the same is not true of the branches of the hepatic artery. The bacilli are generally short, very granular, do not stain so readily or so deeply as those of the skin, nor do they retain the stain so well; they have also by keeping lost their affinity for carbolised and anilinised fuchsin to some extent. (This loss has not been noticed yet in the skin.)

H. *Spleen.*

This organ was enlarged, weighed 12 oz., and was flabby but not softened. Its appearance was very similar to that of the liver; a number of small whitish shreds or granules were found disseminated uniformly all through the pulp. These whitish bodies had a fibrous, shreddy appearance. The largest among them was smaller than even small miliary tubercles. The organ felt somewhat nodulated, but with the exception of a small cheesy nodule measuring about $\frac{1}{12}$ inch in diameter no distinct nodule could be seen with the naked eye.

Microscopically.—There is a general increase of stroma. The trabeculæ and many of the arteries have at their sides masses of large vesicular-looking cells, resembling the small leprous cells found in other organs. There are numerous patches of necrosed tissue, not exactly cheesy-looking, but almost entirely structureless, and composed of granular and hyaline products. Around these patches numerous giant-cells are found. Some of these giant-cells are formed in some of the sinuses or lymphatic spaces of the pulp. Some of the sinuses are lined with a layer of epithelioid cells, giving to certain parts of the organ a glandular appearance. Many of the arteries are much sclerosed, and are almost entirely obliterated by their intima.

Bacilli are found abundantly around the trabeculæ and the arteries, and some of the Malpighian bodies have groups of them in their centre around the artery. (Most Malpighian bodies are, however, indistinct.)

Digitized by Google

Bacilli, free or in vacuolated cells, are also found forming small groups in the midst of the pulp.

The cheesy masses do not contain bacilli, but some of the giant-cells surrounding them (and having to them the same relations as the pulmonary giant-cells have to the corresponding cheesy nodules) contain a few bacilli, some even containing small colonies, and resemble leprous cells. This seems, however, to be accidental, as the giant-cells appear to be specially connected with the cheesy nodules, and not with the lesions containing the typical groups of bacilli. In the spleen, as in the liver, the bacilli are rather short and granular; they stain well, but slower than those of the skin.

I. *Genito-urinary organs.*

The *kidneys* weighed together 9 oz. Their capsule stripped off easily; the cortex was pale, the boundary layer congested. The *urinary passages* and *bladder* were healthy-looking.

Microscopically.—The convoluted tubules were found to be in a state of cloudy swelling at places, and of catarrhal desquamation in others. There was congestion. No bacilli could be found in the parts which were examined.

(*Testicle.*—The examination of that organ was accidentally omitted.)

K. *Supra-renal bodies.*

They seemed to the naked eye to be healthy. On microscopical examination it was found that there was much atrophy of their cortical epithelium, and proportional increase of the interstitial fibrous tissue. No bacillus could be discovered.

L. *Thyroid body.*

This organ was small and apparently normal. On microscopical examination it was found that all the alveoli contained a large amount of colloid matter. The interstitial tissue was normal in amount. No bacillus could be discovered.

M. *Lymphatic ganglia.*

The lymphatic ganglia were swollen and altered in colour in various parts of the body. The cubital ganglion at the bend of

Digitized by Google

the elbow, the lymphatic glands at the root of the neck, in the posterior mediastinum and around the bronchi, and also some of the mesenteric glands were swollen. The ganglia which seemed most affected were the cubital and the cervical glands. The cubital ganglion measured nearly 1 inch in length and ⅜ inch in width. It was firm, brownish grey in colour, and seemed to be in a state of chronic inflammatory induration. The glands at the root of the neck were much softer, congested, mottled, and they were generally arranged in pretty large clusters. There were numerous small rounded whitish nodules, generally smaller than miliary tubercles, all through the substance of these glands.

Microscopically.—The cubital ganglion is found to be in a state of chronic interstitial inflammation, as indicated by the presence of much fibrous tissue, chiefly in the central parts of the gland, but also in the capsule. Very few patches of typical lymphoid cells can be found, and no distinct follicle can be discovered.

The blood-vessels are much congested. Numerous oval, elongated and branched spaces are found, chiefly under the capsule, which look like dilated lymphatic channels, corresponding to the sinuses of the organ. In these cavities large vacuolated bodies, resembling closely the leprous cells of the skin, are found. Some are of very considerable size. Many show a large central vacuole and several peripheral ones. In some of these vacuoles a body staining more or less distinctly like a nucleus is sometimes visible. In some cases a layer of protoplasma containing nuclei forms a crescentric margin on one side of these vacuolated bodies. The lymphoid cells are, in other parts of the ganglion, replaced by swollen, translucent, vesicular, epithelioid cells.

An immense number of bacilli are found all through the organ. In the large leprous cells they are so abundant that it is difficult to differentiate them. They are, however, quite clear and discrete in the small epithelioid cells. They have in the ganglion the same relations to cells and lymphatic spaces as in other parts of the body, but if anything they are more abundant.

N. *Nerves.*

Many of the cords entering into the formation of the *brachial, lumbar*, and *sacral* plexuses were examined, and seemed to the naked eye to be healthy. The *ulnar nerves* could, however, be

Digitized by Google

clearly felt through the skin to be much thickened in the region of the inner condyle of the humerus, and they were, therefore, examined. Several other peripheral nerves must have been affected, but they were not dissected out.

The *right ulnar nerve* was swollen and indurated over a length of about half an inch in the region just indicated; it was not, however, discoloured in the least, nor was it adherent to any of the surrounding tissues.

The *left ulnar nerve* was much more thickened, the swelling measuring at least one inch in length. The nerve was also much discoloured by congestion in that region. It looked healthy above and below the swelling.

Microscopically.—The lesions were clearly those of chronic interstitial neuritis, with considerable inflammatory changes in some of the nerve-fibres, and considerable atrophy of others. The fibres were, however, very unequally affected.

Bacilli were found abundantly in all the parts where lymphatic vessels or spaces could be present. In some cases the bacilli seemed to have penetrated into the nerve-fibres themselves. It was, however, found difficult to decolourise entirely the myelin sheath without decolourising a great proportion of the bacilli, and it is possible that the network of neuro-keratin may have in some places simulated bacilli.

IV. Discussion of the Case.

A. *General remarks.*

This case presents features of interest in the history of the disease.

The patient was born of English parents in India, and presented no symptoms of disease until the age of sixteen, when, a few months after returning to India, from which he had been absent in England for nine years, he became rapidly leprous. It is noticeable that he returned to a district where leprosy was common, and that he suffered from well-marked fever during the appearance of the lesions which probably indicated the onset of the disease. It may be noticed that these lesions, as Hutchinson has remarked in many cases, were symmetrical. It is also evident from the history that the appearance of the cutaneous lesions was accompanied by fever.

Digitized by Google

The case also afforded us an opportunity to make some observations during life. We both attempted to demonstrate bacilli in the *blood* and *lymph*, obtained by compression of non-ulcerated tubercles, according to the methods recommended by some observers. Although a very large number of preparations were examined we failed to find any bacilli in the fluids thus obtained from lesions which, after death, were found to be absolutely crowded with bacilli.[1] The same reagents were used for demonstration both before and after death. We conclude, therefore, that, notwithstanding the positive results obtained by these methods by other observers in other cases, it is advisable, in order to demonstrate the bacilli, to remove a small portion of skin. The smallest portion of skin removed from a part where there is any indication of a lesion will suffice. We do not, of course, pretend that bacilli cannot be demonstrated in the blood, lymph, or serum of leprous lesions, but only that their presence is certainly not constant. Beaven Rake, in his examinations of various materials, and especially the juice squeezed or scraped from fresh tubercles, was able to demonstrate the bacillus in 33 per cent. of the cases examined. We inoculated all the usual nutrient media with the fluids just mentioned. Whenever the lesions were not ulcerated we obtained no growths whatever. With ulcerated lesions we obtained simply the usual organisms found in open wounds. These results are not surprising in the light of what has just been said about the absence of bacilli and the results of *post-mortem* examination. When the disease presents the characters recorded here, blood, lymph, and serum do not afford suitable materials for inoculation experiments. In this we agree with the general experience. We do not wish to attract special attention to the mode of origin of the various lesions, although many of the histological features are very suggestive; neither will we attempt to discuss the mode of spread of the bacilli. It is to a discussion as to the nature and relations of the pulmonary lesions that we wish to confine ourselves, and more especially to the inquiry whether the lungs were in a state of tubercular or leprous phthisis.

[1] We are informed by Dr. Payne that while the patient was at St. Thomas's Hospital similar attempts to demonstrate the bacillus in blood and serum were equally unsuccessful.

Digitized by Google

B. *Nature of the lung lesions.*

a. Evidence of various observers.—The great frequency with which leprosy ends fatally, owing to the lungs being affected by pneumonia or phthisis, has struck all who have had to deal with the disease. As to the nature of this special pneumonia or phthisis, the older observers express no doubts, but regard it as ordinary broncho-pneumonia on the one hand, or tubercular phthisis on the other. The lesions of the intestine also, which are associated with the dysenteric diarrhœa so frequently found in fatally ending leprosy, were similarly considered as due to some associated disease, such as tuberculosis or dysentery, and not to leprosy.

Danielssen and Boek consider the lungs of lepers as almost always free from infection, though they admit that the bronchi and bronchial glands are attacked by the disease. The pleuræ, too, are frequently affected by what they admit is leprosy, but the underlying lung is usually found healthy. According to these observers, then, there are present leprotic lesions of the bronchi, bronchial glands, and pleuræ, while the parenchyma of the lung escapes. Similarly they admit a leprous affection of the mesentery and mesenteric glands, though apparently they except the intestinal lesions.[1]

Leloir, while commenting on the large number of lepers who are phthisical or scrofulous, or of phthisical or scrofulous families, considers that the lungs are almost always free from leprosy. In only two cases has he found bacilli in the lungs. One of these he describes as tubercle, and the other as broncho-pneumonia.

Hansen, from 100 *post-mortems*, concludes that there was no case in which the lungs, intestines, serous membranes, or kidneys were affected by leprosy. He regards all the affections of these organs or membranes as tubercular.

Neisser, Virchow, and Köbner also regard lung leprosy as doubtful. On the other hand, from his observation in Hawaii, Arning came to the conclusion that the pneumonia and phthisis of lepers must be regarded as integral parts of the original disease, and as truly leprous as the affections of the skin.

Bonome also in two cases of leprosy, from one of which Uffreduzzi's cultures were made, considered that the lung affections were true leprosy. This latter observer bases his opinion on the characters of

[1] Danielssen and Boek, English translation, p. 212, &c.

Digitized by Google

the lesions and of the bacilli so far as regards the staining reactions and distribution, but did not make any inoculation experiments. In his cases the lesions of the larynx and trachea were practically similar to those we have described above.

The bronchial glands were affected in the same way also. The bronchial mucosa was infiltrated with small cells and covered with slimy exudation. There was a general state of broncho-pneumonia, and of "peribronchitic induration." In all this our case agrees with his. He, however, describes the pleuræ as thin and transparent, and the lungs as small, pigmented, hard, and nodulated. In the present case the lungs were undoubtedly indurated, nodulated, and pigmented, but they were large. We also agree in great part with him as to the distribution of the bacilli and as to their character. He found them chiefly in the bronchial secretion, but also in the small-celled infiltration of interalveolar septa, where we, on the contrary, found them extremely seldom. (It is true that on fresh sections, stained immediately after the *post-mortem* examination, one of us saw around vessels contained in interlobular septa quite typical clumps of bacilli identical with leprous cells in other parts of the body; the stain of these sections has, however, faded, and no other section has been obtained showing the same appearance since, so that we do not insist on this.) Bonome also describes thick masses of bacilli in the hyaline zone. These masses correspond probably with those which we have ourselves observed in the midst of the decayed bronchial products, which are very hyaline, and surrounded by granulation tissue containing giant-cells. The bacilli are described as shorter and thicker than the *Bacillus tuberculosis*.

Perhaps the most valuable contribution to the subject is a posthumous paper by Damaschino describing two *post-mortem* examinations of lepers. In one of these cases the lungs seemed to be really affected with tuberculosis.

Histologically at least the lesions were similar to those of chronic tuberculosis, and it is interesting to note that in that case the skin contained also distinct giant-cells in the midst of leprous nodules. There was also more or less extensive ulcerations of the mucous membrane of the intestine.

In the other case the *lungs* were heavy and large. There were pleural adhesions, and cavities varying in size from that of a pea to that of a walnut. The lungs contained a number of typical

Digitized by Google

tubercles, giant-cells, caseous masses, and a considerable number of bacilli, short, felted, and absolutely similar to those of the liver and spleen (which organs were typically leprotic). There were also a few isolated or clumped bacilli, which from their length and thinness seemed to be tubercular bacilli. Inoculations in series demonstrated the existence of tubercular bacilli in the lungs, but Damaschino thought nevertheless that the main cause of the lung lesions was leprosy. Commenting on the case, Damaschino says that inoculation proves conclusively the existence of a pulmonary tuberculosis, whose bacilli are lost in the midst of leprous bacilli. It is interesting to note that in this case there was distinct sub-peritoneal tuberculosis of the intestine. In our case, on the contrary, there was no evidence of anything like a tubercle anywhere in the intestine, and the peritoneal coat was perfectly smooth everywhere.

There is obviously considerable difference of opinion as to the nature of the pulmonary lesions in leprosy, and the weight of the opinion is, it must be confessed, adverse to the existence of leprous phthisis. It must, however, be remembered that some of the facts are susceptible of a different interpretation.

Statistics do not prove much, but such as exist seem to show a connection between phthisis and leprosy greater than would be expected if they were merely intercurrent independent diseases.

β. *Statistics.*—The figures available for determination of the percentage number of deaths from phthisis in lepers is not very large, but they all point to the extreme frequency of the disease. Hillis, in British Guiana, says that in tubercular leprosy, deaths from lung complications, including phthisis, amount to 17 per cent. of the total deaths. The percentage of deaths among the general population of British Guiana from phthisis is 7·1 per cent.

In the leper hospital at Kakaako, in Hawaii, the percentage of deaths due to what is variously registered as phthisis, consumption, and tuberculosis, amounts to 21·8 per cent. The percentage of deaths from phthisis to deaths from other diseases in the district of Rona, which includes Honolulu, and with which the death-rate of Kakaako may be compared, is from 11·2 per cent. to 12·5 per cent.

In the carefully kept Hospital Reports of the Trinidad Asylum, compiled by Beaven Rake, the percentage of deaths recorded as due to phthisis, and total deaths for the years 1885 to 1889, are—

Digitized by Google

	Total deaths.	Phthisis.	Per cent.
1885	28	7	25
1886	21 (in only 11 cases cause recorded)	3	27·6
1887	30	7	25
1888	16	6	37·5
1889	16	3	12·5

In 5 years total deaths . 111
Deaths from phthisis . 26 = 23·4 per cent.
Excluding 10 unrecorded . = 25·7 „

It is instructive to compare the number dying of phthisis with the number suffering from phthisis in the hospital.

	Deaths from phthisis.	Recorded as phthisical.	Total lepers.
1885	7	9	173
1886	3 (10 unrecorded)	7	168
1887	7	6	236
1888	6	6	167
1889	3	10	225

It would seem, then, that the phthisis is rapid and extremely fatal. In the present case the patient is recorded as presenting no definite physical signs of consumption at the end of August, 1888, though he had had cough and night sweats for a few weeks; but by May, 1889, and indeed earlier, he had signs of advanced phthisis, and died in July, 1889, with pneumothorax.

Turning to the intestinal lesions, it is seen that diarrhœa, asssociated or not with ulceration of the intestine, is also the cause of many deaths in cases of leprosy. Thus Hillis gives the percentage of deaths from diarrhœa in cases of tubercular leprosy as 10 per cent., and in anæsthetic leprosy at as much as 36 per cent. In the latter variety of the disease it takes the form of a mucous enteritis.

In the Kakaako Hospital, again, diarrhœa caused 6·2 per cent. of the total deaths. The statistics of the Trinidad Asylum show that diarrhœa was a common intercurrent affection.

Digitized by Google

Date.		Total cases.		Percentage who suffered from some form of diarrhœa.
1885	...	173	...	10·9
1886	...	168	...	13·6
1887	...	236	...	12·2
1888	...	167	...	21
1889	...	225	...	17·7

It is to be noticed that in all the *post-mortems* recorded above ulceration of the intestine was present.

Though, as stated above, the weight of opinion is against the idea of leprosy affecting the lungs, still the facts above related show that it is admitted—

1. That lung affections are very common indeed in leprosy (18 per cent.—21·8 per cent.—25·7 per cent.), and that ulceration of the intestine and diarrhœa is also extremely frequent.

2. That though the lungs are said to be affected by tuberculosis, it is admitted that the pleuræ, bronchi, and bronchial glands are the seat of leprotic lesions.

3. That while the skin and internal organs are admittedly leprous, the lungs are affected by a different disease.

4. That finally the lungs may be the seat of tuberculosis though crowded with the parasite of leprosy.

It certainly seems remarkable that the lungs should possess such a curious immunity from leprosy, and alone of all the organs escape, when at the same time they are affected so often by a disease which, in the character of the lesions produced and the micro-parasite found, so closely resembles leprosy.

γ. *Our own observations.*—In order to elucidate, if possible, this question we undertook a series of investigations, which had for objects the study of—

1. The value of the various criteria which are used to differentiate the bacilli of tubercle and leprosy.

2. The distribution of the *Bacillus lepræ* in the tissues of various organs.

3. The effects which the place of growth has on the characters of the bacillus.

4. The nature of the lesions.

1st. *Value of various criteria.*—While all observers agree as to the close resemblance in size and shape betweeen the two bacilli, yet the measurements given are not always in accord with this

Digitized by Google

statement. This is scarcely surprising if the extreme variability of the *Bacillus tuberculosis* as it occurs in sputa, in culture, and in internal organs is remembered. Flügge and others give for *Bacillus lepræ* measurements nearly double those given by Koch for *B. tuberculosis*, while Bonome and Damaschino speak of the former bacilli as shorter and thicker than the latter. Similarly with regard to shape, the general opinion is that *B. lepræ* is more uniform and more rectilinear, but Baumgarten failed to establish any decided differences; and while Neisser regards the pointed extremities of *B. lepræ* as characteristic, Bordone Uffreduzzi draws attention to the terminal swellings of the same bacillus.

There is a conflict of opinion as to the motility or non-motility of the *B. lepræ*. Both bacilli are described as possessing a gelatinous envelope (*B. lepræ*—Neisser, Unna, Lutz, Babes; *B. tuberculosis*—Koch, Lutz, Unna).

With regard to staining reactions, also, the similarity between the two bacilli is much more striking than the differences; and a comparison of the various opinions expressed by investigators leads to the conclusion that, contrary to the original idea, any stain which will give results with the *B. lepræ* will also stain the *B. tuberculosis*. Successive authors have drawn up lists of differential stains, which usually show that some will stain *B. lepræ* while leaving *B. tuberculosis* unstained. The statements of one observer are, however, almost always traversed by the positive statements of another; and whatever may be the cause of these discrepancies, it is obvious that such contradictions entirely deprive of weight any opinion as to the nature of the bacilli based on these grounds. Both the *B. lepræ* and the *B. tuberculosis* are stated by one or more investigators to be stained by concentrated watery, or dilute alcoholic solutions of fuchsin, safranin, gentian violet (and its varieties), methyl violet, dahlia, malachite green, and methyl green. With regard to methylene blue, the statements are flatly contradictory. Babes recommends it to stain *B. lepræ*; Baumgarten says that neither watery nor alcoholic solutions of this dye stain either bacillus; and Wesener, while agreeing with Baumgarten, adds that dilute alcoholic alkaline solutions stain both *B. tuberculosis* and *B. lepræ*.

The discrepancies arise in part, undoubtedly, from the varying properties of the stains used; but sufficient weight does not appear to have been allowed, though the cause is recognised, to the variations of the bacilli in different cases. Our own experiments lead us

Digitized by Google

to the opinion that the staining reaction varies not only in different cases, but in the various organs of the same case.

Another source of discrepancy may arise also, in that it is by no means easy to decide, when using such stains as Löffler's blue, simple methylene blue, or even Bismarck brown, whether the bacilli in sections are stained or not. The leprous cells are mapped out by the stains, and traversed by faint granular lines which seem to correspond with the bacilli seen in sections stained by more suitable dyes, but it would be impossible to recognise individual bacilli. Alkaline methylene blue, however, in some cases, and notably the affected nerves, stained individual bacilli well and strongly.

The *B. lepræ* is also stated to be more rapidly coloured and less rapidly decolourised than *B. tuberculosis*. The most definite statements are those of Baumgarten, who has arranged a differential method which, though probably useful, cannot be relied upon in diagnosis of the two bacilli. According to him, dilute alcoholic fuchsin (5—6 drops in small watch-glass of water) stains *B. lepræ* (in sections) in 12—15 min., so as to resist ½ min. in acid alcohol (absolute alcohol $10+HNO_3$ 1). *B. tuberculosis* under these circumstances remains unstained. On cover-glasses 5—6 min. is the time necessary to stain *lepræ*.

We find that by Baumgarten's method several varieties of fuchsin unmistakably stain the *B. tuberculosis* as well as the *B. lepræ;* and, indeed, we found that so short a time as six minutes was sufficient, in cold concentrated watery rubin, fuchsin, or magenta, to definitely stain the *B. tuberculosis* in tissues. It is admitted that different samples of stain vary much in their properties. It must be understood that it is not denied that if sections of tubercle and leprosy are stained thus rapidly, a much larger number of bacilli will be seen in the leprosy sections than in those of tuberculosis. This, however, depends not upon the different staining reaction of the two bacilli, but upon the fact that the bacilli are present in so much greater numbers in leprosy. It is a distinction based really on the number of bacilli present, and not on any essential difference in the reactions of the two bacilli. Besides these methods of Baumgarten, there is one suggested by Lustgarten, based on rapidity of decolorisation by hypochlorite of sodium; and methods by Voltolini, Unna, and Lutz, based on the production of a streptococcus-like form, in the first case in

Digitized by Google

B. tuberculosis, and in the second in *B. lepræ*. In many organs, however, the non-bacillary form is chiefly found in any method of staining.

The picture presented by leprosy sections stained with fuchsin by these rapid methods, compared with that obtained by prolonged staining, is very suggestive. In the latter case the most striking objects are the large red leprous cells visible with a low power. In the former case these cells are no longer conspicuous, and, indeed, usually present, on examination with a high power, one or two red bacilli only in a mass of material stained with the counter-stain. A very large proportion, however, of the bacilli found either between the cells or in the small epithelioid cells are stained well. This would seem to indicate that the bacilli in the two situations are in very different conditions.

It is obvious, then, that, so far as the size, shape, and staining properties of individual bacilli are concerned, it is impossible to distinguish between the *Bacillus tuberculosis* and the bacillus of leprosy by any of the criteria proposed.

2nd. *Distribution of the* Bacillus lepræ.—Generally speaking, the most uniformly affected part of the body was the skin. The mucous membrane of the mouth, pharynx, and larynx was involved very much in the same way. Bacilli were extremely abundant in these parts. Many terminal nerves and some nerve-trunks were affected as deeply as the skin; but, if one may trust a naked-eye examination, none, or at any rate few, of the large cords forming the various great plexuses of spinal nerves showed any leprotic lesions.

Some lymphatic glands also contained a prodigious number of bacilli, but in others the bacillus could not be found, although the ganglia were much diseased. The bacilli were also very abundant in the Haversian canals and spaces, and in the marrow of the phalanges, which were the only bones examined microscopically.

In this connection it may be remembered that Uffreduzzi's cultivation was made from the marrow of bones, and that, referring to this culture, Kaurin states that he has never observed bacilli in bone marrow.

The organisms were also present in the liver and spleen, but less abundant in these organs than in the skin. Certain organs —the kidneys, the supra-renal bodies, and the thyroid—seemed entirely free from them. The mucous membrane of the stomach

Digitized by Google

and small intestine, as well as that of the bladder, seemed also to be quite free from disease.

In many lymphatic spaces and blood-vessels the endothelial cells contained a large number of bacilli. In some cases these cells seemed to coalesce, and give rise to the large leprous cells with central lumen to which we have alluded in several places. Babes has also described bacilli in the endothelium of blood-vessels.

If, instead of taking the distribution of the bacilli in organs, we consider the relation to tissues, a number of interesting facts are brought out. The tissue most affected is undoubtedly the ordinary *loose or areolar fibrous connective tissue; then the lymphoid tissue.* In the areolar connective tissue the bacilli are almost without exception either apparently free in lymph spaces or vessels, or, what is more common, embedded in small epithelioid cells, accumulated in lymphoid spaces, or in large masses generally described under the name of leprous cells. Fixed connective-tissue corpuscles, apparently compressed between fibrous bundles, are also affected, but when this is evident the bacilli are few and the lesions slight. In the *lymphatic tissue* the bacilli have pretty much the same relations. Many small, round, lymphoid cells or leucocytes are also distinctly affected. The *adipose tissue* of the subcutaneous layers, and of the marrow of bone, is much affected. *Dense fibrous tissues,* such as tendons, are very little involved; what looks like a tendon-corpuscle here and there contains a few bacilli; the same may be said of bone-corpuscles.

Hyaline, fibro-, and *elastic cartilages* remain perfectly free from bacilli, even when surrounded by them in all directions. It is, therefore, evident that the connective tissues are, with the exception of the densest forms, much affected, and that the number of bacilli is very nearly proportionate to the size of the lymphatic spaces in which they are lodged.

The *epithelial tissues* are, generally speaking, free from bacilli. Here and there a few bacilli, however, penetrate into the deep layers of the rete Malpighii of hair follicles and of sebaceous glands. They may even pass towards the surface of the skin with the sebaceous secretion: a few have been found in the acini and ducts of mucous glands. They, however, do not thrive in epithelial cells, and no large colony has been found in any epithelial tissue.

Monastersky and Neisser affirm that the epithelial layers do not contain bacilli; and in this they are confirmed by Cornil and Suchard; but subsequent observers—amongst them Thin and

Digitized by Google

Babes—have described them in epithelial structures, and chiefly in those mentioned as showing them this case.

The sweat-glands are free according to Babes, Unna, and Touton. We also were unable to detect any bacilli in their epithelium, but were struck with the extraordinary accumulation of bacilli around most of them, or rather in the fibrous tissue which so frequently almost entirely replaces them.

In *nerves* they are found abundantly in the lymphatic spaces and connective-tissue corpuscles, and in some cases they seem to have penetrated into and grown in the myeline sheath.

In *non-striped muscles*, such as those entering in the sheath of arteries, bacilli may be found pretty abundantly in small round masses and in small groups of two or three; they seem, however, to lie generally between the fibres.

In *striped muscles* they are found pretty abundantly in the endomysium and perimysium, and in some instances a few have penetrated into the muscular fibre itself.

Generally speaking, therefore, the bacilli seem to grow well only in the lymphatic spaces of loose or moderately loose connective tissues, whether these tissues form continuous tracks as in the skin, or enter into the formation of organs such as nerves, muscles, or glands.

There is, however, a feature worth noticing. Wherever the connective tissues become exposed by shedding of the epithelium covering it and ulceration, the bacilli seem to disappear entirely or in part; they do not at least respond any more to the ordinary tests. It is only when they seem to be multiplying with great rapidity, or when the ulcerative process is very active, that bacilli are found in the superficial products; but even then they are much less abundant than in the corresponding parts which have not ulcerated.

The number of bacilli found in various organs or lesions is, therefore, not only determined by the functions and relations of the organ, but also by the form of connective tissue entering into its composition, and probably also—at least so far as demonstration is concerned—by the amount of shelter from the air afforded by superficial layers of epithelium.

In respect to exposure to air, the lung parenchyma is comparable to the skin or a mucous membrane deprived of its epithelium, and therefore, on this supposition, the bacilli should not be easily demonstrable by the usual methods.

Digitized by Google

When large cheesy masses are found in the lungs the central portion of them is far removed from the contact of the air, and here we find large masses of bacilli.

The mucous membrane of the air-passages, which is comparable to intact skin, is also one of the places where bacilli are generally easily shown.

We mention the *apparent effect* of exposure to air for the purpose of generalising the facts which we have observed in the skin and mucous membrane, where, by ulceration, the epithelium had been removed. In those places bacilli, which were extremely abundant in the tissues immediately surrounding the lesion, were not to be demonstrated, except occasionally in small number, by the ordinary methods. We have no proof whatever that this is due to the action of air, but this seemed to be the only general connecting relation between the parts where bacilli could not be brought out by staining, although one would have expected them to be abundant.

3rd. *Variability of the characters of the bacilli according to their distribution in the body.*—This variability was really the first thing which attracted the attention of one of us to the very unsatisfactory state of our knowledge of the characters of the *Bacillus lepræ.*

(1) The discrete bacilli, or those contained in small epithelioid or lymphatic cells, differ in characters from those contained in the so-called leprous cells as follows:

Discrete bacilli.	*Bacilli in leprous cells.*
1. Are generally short, though distinctly bacillary.	1. Generally very long, and pretty often beaded.
2. Stain quickly.	2. Stain more slowly.
3. When well stained are comparatively easily decolourised.	3. When well stained retain stain vigorously.
4. Take a brighter and somewhat more transparent colour with fuchsin.	4. Take a deeper and more opaque stain.
5. Are much more clearly defined, owing to the surrounding substance not staining or being decolourised.	5. The interbacillary substance stains deeply, and is difficult to decolourise.
6. Prolonged steeping in acid alcohol renders them more refractory to staining (bone).	6. Prolonged steeping does not prevent staining to any serious extent.

(2) On the day of the *post-mortem* examination numerous fresh

Digitized by Google

sections were cut and left in cold fuchsin for five minutes, fifteen minutes, two or three hours, twenty-four hours, and forty-eight hours. In the case of nearly all the organs examined the first trial (five minutes) gave very unsatisfactory results or none. The second (fifteen minutes) gave invariably good results with the skin. The third experiment (two to three hours) gave good results with the skin, nerves, and lymphatic glands, but imperfect with the liver, spleen, lungs, and intestine, specially with the last two organs. The fourth and fifth trials gave good results with every organ. These experiments were made in summer at a temperature of about 18° to 20° Centigrade.

The bacilli contained in various organs can, therefore, be said to vary in their reaction to staining reagents. The following table gives a summary of the results obtained on various occasions.

They stain rapidly and well, and are not easily decolourised in the Skin. Mucous membrane of larynx. Nerve. Lymphatic gland.	They stain more slowly and are more easily decolourised in the Liver. Spleen. Intestine. Bone? (bones had been decalcified).	They stain well in the fresh tissues, but lose this property to some extent when kept in absolute alcohol in the Liver. Spleen. Intestine. In the liver and spleen they still stain well after two years, but they have lost their distinct bacillary form, and look very beaded.

(3) Their appearance varies in the different organs.

They are long, or at least very distinctly bacillary in the Skin. Mucous membrane of larynx. Nerve. Lymphatic gland.	They are shorter or more generally beaded or granular in the Liver. Spleen. Bone. Muscle (almost like cocci; they are also very thick, and stain extremely deeply).

From these very general statements it is evident that but little value can be attached to the characters of the bacilli in determin-

Digitized by Google

ing whether a lesion is tubercular or leprotic. No serious objection on this ground can, therefore, be raised against our regarding the bacilli in the lung as being quite as likely to be leprous as tubercular.

4th. *Nature of the lesions.*—There can be no doubt as to the existence in this case of extensive broncho-pneumonia, combined with an interstitial pneumonia of a peculiar type, owing to the presence of an unusual number of epithelioid cells in the interstitial tissue. It is also evident that no true miliary tubercle nor even a typical cheesy tubercle can be found anywhere. The giant-cells found at the periphery of some of the cheesy-looking masses, resulting from the necrosis of pneumonic products, have not the usual characters presented by those found in tuberculosis. They have connections very similar to those of giant-cells found in the larynx and the spleen, both of which organs present most typical leprotic lesions.

The lesions have the same characters as those observed in other organs, such as the skin for instance. These lesions consist of congestions, accumulations of peculiar translucent vesicular-looking epithelioid cells in the lymphatic spaces, necrosis of tracts of tissues, degeneration of all the epithelial structures, which become surrounded or undermined by leprotic cells; consecutive fibrous induration, and atrophy. Such lesions are certainly found in cases of ordinary tuberculosis, but they rarely if ever attain the general characters observable in this case, and they are generally combined with more typical lesions.

If such lesions were found in a case of undoubted tuberculosis, one would feel inclined to consider the case as one of tubercular cheesy pneumonia presenting unusual features.

Under such circumstances, is it wise to insist upon the tubercular nature of the pulmonary lesions? No; unless one were prepared to consider leprosy as a peculiar variety of tuberculosis, a view which is perhaps not so unlikely to be true as one might fancy at first.

V. General Conclusions.

From all this we conclude—

1st. That the *tests* proposed by various writers for distinguishing the *Bacillus lepræ* from the tubercular one are insufficient.

2nd. That the *characters* of undoubted *Bacilli lepræ* are so

Digitized by Google

variable that there are as great differences between two extreme forms of this organism as between what are considered by authors to be typical bacilli of tuberculosis and leprosy.

We do not feel therefore justified nor inclined to decide whether the bacilli found in this case were tubercular or leprous on such grounds.

3rd. That the *distribution* of the bacilli revealable by usual staining methods is such that organs like the lungs would, if affected with leprosy, present lesions differing from those occurring in other organs, and that the free access of air seems to be against the bacillus retaining the characters under which we know it.

4th. That the *lesions of the lungs* are more closely allied to those of the other leprous organs than to those of ordinary tuberculosis; and that in presence of the abundance of the bacillus of leprosy in nearly every part of the body, and indeed in the air-passages and pleura, it is somewhat illogical to try to find another cause for the existence of these lesions.

The only test which can be of use in determining this question finally is inoculation; and if the results already obtained by Damaschino should be obtained in all cases in which the lungs are affected thus, it would be well to reconsider the whole question, as to whether leprosy may not be some very modified form of tuberculosis *which, when virulent enough to involve certain organs, such as the lung,* tends to revert to the form with which we are best acquainted. In favour of such a view, we would simply urge the following points, without, however, wishing to pledge ourselves to such a conclusion.

1st. The characters of the bacillus and its staining reactions.

2nd. The nature of some of the lesions.

3rd. The frequency of phthisis and scrofula in leprous patients (over 25 per cent.) or in their antecedents.

4th. The difficulty of obtaining any result from inoculation with the most typical and advanced leprotic lesions.

5th. The success of inoculation with products obtained from organs less typically and frequently affected, such as the lungs.

6th. In cases of successful inoculation the production of a disease which is generally tuberculous, or indistinguishable from tuberculosis.

To prove the correctness of this supposition, it would be necessary

Digitized by Google

to discover cases in such stages, or under such conditions, that the bacilli obtained from various parts of the body were capable of producing tuberculosis by direct inoculation or after cultivation. Until it has been proved that it is possible to reproduce leprosy by the inoculation of the *Bacillus lepræ* we think there is not more evidence in favour of the view that the lesions of the lungs are not leprous because they give rise to tuberculosis, than in support of the one that leprous lesions are the results of a *modified form of tuberculosis which tends to return to the normal type in the lungs.*

May 23rd, 1891.

VI. Bibliographical Appendix.

1. *Arning.*—'Virch. Archiv,' Bd. xcvii. 'Report on Leprosy to Board of Health,' Honolulu, 1886. 'Journal of Leprosy Committee.'

2. *Babes.*—'Les Bacteries,' 2nd edition, p. 484. 'Acad. des Sciences,' 1883, p. 1246. 'Archiv. de Physiologie,' 1883.

3. *Baumgarten.*—'Lehrbuch der Path. Mykol.,' Bd. ii, 1890. 'Monatschrifte für prakt. Dermatol.,' Bd. iii, No. 7. 'Zeitschrift für wissensch. Microscopie,' Bd. i, 1884. 'Centralblatt für Bact. und Parasitenkunde,' Bd. i, p. 574.

4. *Bonome.*—'Virch. Arch.,' Bd. iii, p. 114.

5. *Bordone Uffredumi.*—'Zeitsch. für Hygiene,' Bd. iii, p. 178, 1887.

6. *Cornil and Babes.*—'Les Bacteries.'

7. *Cornil and Suchard.*—'Soc. Méd. des Hôpitaux,' June, 1881.

8. *Damaschino.*—'Arch. de Méd. expérimentale,' March, 1890.

9. *Danielssen and Bock.*—'Traité de la Spedalsked.' (Eng. translation).

10. *Flügge.*—'Micro-organisms,' p. 274, trans. by Watson Cheyne.

11. *Hillis.*—'Leprosy in British Guiana.'

12. *Hutchinson.*—'B. M. J.,' 1890, vol. i, p. 341.

13. *Kaurin.*—'Journal of Leprosy Committee,' vol. ii, 1891.

14. *Kobner.*—'Virch. Archiv,' 1882.

15. *Koch.*—'Berlin. klin. Wochenschrift,' 1882, p. 222. 'Micro-organisms and Disease,' New Sydenham Society.

16. *Leloir.*—'Mém. de la Société de Biologie,' 1885, p. 101. 'Traité théorique et pratique de la lèpre,' 1880.

Digitized by Google

17. *Lustgarten.*—'Jahrbücher der K. K. Gesellsch. der Aerzte,' 1885, p. 6.

18. *Lutz.*—'Dermatolog. Studien,' 1886, Heft 1. 'Monat. für prakt. Dermat.,' 1886.

19. *Neisser.*—'Virch. Archiv,' Bde. lxxxiv, xc, and ciii. 'Verhandlung der Deutsch. Dermatol. Gesellschaft,' Prague, 1889.

20. *Rake* (*Beaven*).—'Reports of Trinidad Leper Asylum.'

21. *Thin.*—'Med.-Chir. Trans.,' vol. lxvi, p. 314, 1883.

22. *Touton.*—'Virch. Archiv,' Bd. civ.

23. *Unna.*—"Leprastudien," 'Monat. für prakt Derm.,' 1884, 1885. 'Dermatolog. Studien,' 1886, Heft 1.

24. *Virchow.*—'Onkologie,' vol. ii.

25. *Voltolini.*—'Breslauer Aerzt. Zeitsch.,' 1885, p. 173.

26. *Webb-Cook.*—'Reports on Leprosy,' Honolulu, 1886, Appendix P.

27. *Wesener.*—'Centralblatt für Bact. u. Parasitenkunde,' Bd. i, p. 450; Bd. ii.

---

10. *A case of melano-mycosis of the skin, with remarks, &c.*

By Sheridan Delépine.

[With Plates IX and X.]

GENERAL SUMMARY.

PAGE

I. Preliminary remarks 424

II. History of the case; nature of lesions; treatment . . 424

III. General description of the *Aspergillus niger* . . . 426

IV. Evidence of the pathogenic action of the *Aspergillus niger*:

1. Facts of the case 427
2. Cases and experiments of other observers . . . 428
3. Inoculation experiments 428
4. Effects of accidental inhalation in man . . . 430
5. Form of parasitism; influence of heat, moisture, and lowered vitality of tissues affected 431

Digitized by Google

V. Development and variability of the *Aspergillus niger*: PAGE
1. Observations 432
2. Typical developmental stages 442
3. Variations:
1st. Influence of pabulum 445
2nd. Influence of temperature . . . 447
3rd. Vital concurrence between the *Penicillium glaucum* and *Aspergillus niger* at various temperatures . 448
4th. Influence of moisture 449
5th. Influence of air 449
VI. Effects of the growth of the *Aspergillus niger* on various nutrient media:
Production of glucose, proteoses, gelatoses, and peptones, oxalic acid, acetic acid, crystalline extractives, gallic acid, sucrose, and invert sugar 451
VII. General considerations on the hydrolytic actions of living protoplasma 453
VIII. Bibliographical appendix 454

I. Preliminary Remarks.

I am indebted to one of my pupils, Mr. Wild, for bringing this case under my notice, and for helping me in getting the following clinical notes. Had he not been struck by the unusual appearance presented by the ulcers, and removed the few shreds of epidermis which he brought to me for examination, this very interesting case would have entirely been lost to me.

II. History of the Case; Nature of the Lesions.

The patient, a man 27 years of age, was admitted on the 11th of May, 1890, into St. George's Hospital, under the care of Mr. Rouse, for fracture of the right femur. He had eight years previously sustained a compound fracture of the right tibia at the junction of the upper and middle thirds of the leg. As a result of that previous accident there was a scar on the inner and anterior aspect of the leg, which was otherwise apparently sound.

The leg was put up in Desault's and three short splints, and strapped with ordinary soap plaster from the ankle to just below the knee. The foot was bandaged as usual with cotton bandage. At the time of "putting up" *there was no wound below*

Digitized by Google

the knee, and with the exception of the scar remaining from the previous fracture the skin was normal.

On June 13th the strapping was removed from the leg, when it was noticed that both strapping and leg were in two situations covered with a black substance closely resembling soot. In these two places there were also two ulcers. These ulcers were evidently superficial. The skin surrounding them was covered with the brown dust, and wherever this substance was present the cutis was moist, and the epidermis peeled off easily. (A small shred of the cuticle covered with the suspicious substance was removed for microscopical examination.) The lower ulcer was quite near the upper margin of the cotton bandage; notwithstanding this the black stuff did not extend at all beneath it; it, on the contrary, was most abundant where the soap plaster came in contact with the skin, and was absent where this was not the case. There was no trace of it on the outer side of the leg.

The upper ulcer corresponded exactly to the region where the skin had been torn by the broken tibia eight years previously.

These ulcers, although they frightened the patient greatly, were not painful, and healed rapidly after thorough washing and boracic acid dressing.

Microscopical examination of the epidermis.—Under the microscope the cuticle was found to be literally covered with small round bodies, resembling closely red blood-corpuscles both in shape and size, but presenting a dark brown colour. Many of these bodies were crenated, and this increased their resemblance to red blood-corpuscles.

These bodies measured from 3·5 to 6 μ, generally speaking about 5 μ; most of them were spherical, but many also were flattened. I naturally suspected them to be the conidia of some pathogenic mould, and I therefore immediately inoculated some nutrient gelatine tubes; and in less than a week, at a temperature of 20 to 23° C., I obtained an abundant growth of mycelium with conidia, entirely similar to the round bodies found in the skin. The mould thus obtained had all the characters of the *Aspergillus niger*.

Digitized by Google

III. Description of the Aspergillus niger.

Flügge says (p. 119), in connection with that fungus,—

"We distinguish (after Siebenmann) the so-called *true* Aspergillus (*Asp. clavatus, flavus, fumigatus, niger*, &c.) and the two *Eurotium forms* proper (*Eurotium aspergillus-glaucus* and *Eurotium repens*)."

Further, he describes the *Aspergillus niger* as follows (p. 121):

"Dark brown masses. The knob of the fruit hypha completely spherical. Sterigmata 20—100 μ in length, branched like a hand. Conidia round; when ripe blackish brown; diameter 3·5—5 μ. Sclerotia brownish red, of the size of a rape seed. Best temperature 34° to 35° C."

It will be seen from the drawings accompanying this paper that the organism which I found in the diseased skin brought to me by Mr. Wild corresponds exactly to the above descriptions.

I may add that all the Aspergilli I have examined are extremely variable in their characters, the conidia being about the only parts the appearance and measurements of which can be considered to have any constant value. And even these have to be considered in the light of surrounding circumstances. Thus I found that those which covered the moistened epidermis around the cutaneous ulcer in this case were, generally speaking, vesicular-looking, spherical, and of the size of a small red blood-corpuscle. The pigment seemed to be mostly near the surface, under a double outlined capsule, and at times it projected beyond the surface, having apparently passed through a small opening in that capsule; this gave to the conidia the crenated appearance already alluded to. When, on the contrary, the conidia were obtained from a rather dry cultivation, and before they had come in contact with any watery fluid, then their size was much smaller, barely measuring 3 μ in most cases. They were also more deeply pigmented; the pigment seemed to be uniformly distributed through their contents, &c. &c.

I have observed similar variations in the spores of all the other Ascomycetes I have had an opportunity to study.

These variations are not only the results of conditions of moisture and dryness, but they depend on numerous factors, and, I have no doubt, correspond to various modes of growth and conditions of activity.

The work of Pasteur and his followers strongly points towards

Digitized by Google

the importance which the study of the variability of properties (quite independently of the mutability of species) must have in connection with the origination and modification of diseases.

It seems, therefore, to me that a careful study of micro-organisms which have very characteristic features and stages of growth may help towards the elucidation of some important ætiological problems. I think also that the most suitable objects for such studies are organisms, such as many of the Aspergilli, which are (1st) *facultative parasites*, and which have (2nd) a pretty definite position in the scale of living beings. The first condition gives us organisms which are, so to speak, in a transitional state (that is, admitting that *saprophytes* are capable of becoming gradually *obligatory parasites*). The second condition allows us to compare the various biological relations which determine virulence, either independently of purely physico-chemical factors, or more probably under the direct or indirect influence of external conditions. It is in the hope of helping a little in the investigation of such questions that I have taken advantage of the opportunities offered to me by several cases of mycosis *observed in man* to make a few experiments, some of which I will briefly relate.

Before doing so I must, however, indicate my reasons for believing in the pathogenic properties of the *Aspergillus niger*.

IV. Evidences of the Pathogenic Properties of the Aspergillus niger.

1. *Facts of the case.*

The fact that in the case here related the fungus was found growing abundantly in the skin surrounding and on the plaster covering the ulcers seems to indicate clearly that there was a connection between the Aspergillus and the ulcer. It would be difficult, however, from this to conclude that the fungus was the cause of the ulceration, since it might be urged with equal probability that the fungus had grown only where the skin had become ulcerated for some reason or other.

The removal of the Aspergillus was, however, followed by rapid cure; and this undoubtedly strengthens the view that it was there as a parasite, and not as a saprophyte. Before coming to this

Digitized by Google

conclusion it is, however, necessary to prove that no other organism than the Aspergillus was present in the wound; and that, by inoculation with pure cultivation of the *Aspergillus niger*, it was possible to induce lesions directly connected with the presence of that fungus.

2. *Cases and experiments of various observers.*

Such experiments have been made by a few observers with several Aspergilli, the *Aspergillus niger* included — Lichtheim, Leber, Schütz, &c.; and it has been proved that severe inflammation may be started by these moulds when there is a sufficiently free access of air. It has, however, also been recognised that the *Aspergillus niger* germinates imperfectly in living tissues. Several observers have brought forward cases in which Aspergilli closely allied with the *Aspergillus niger* have apparently caused serious lesions of the integument lining the EXTERNAL AUDITORY meatus—*Pacini, Meyer, Bezold, Bizzozero, &c.*; the CORNEA—*Leber*; the LUNGS—*Rother, Lichtheim, Schütz, Schubert, &c.* There is, therefore, altogether strong evidence in favour of the view that certain Aspergilli may cause lesions; it is also evident that among these pathogenic fungi the *Aspergillus niger* is probably one of the least virulent.

No case of primary affection of the skin by the Aspergillus niger has, so far as I know, *been recorded yet.* I thought, therefore, that although the evidence of the case itself was strongly in favour of the possibility of such an infection, it would be desirable to obtain a new demonstration of the pathogenic properties of that organism.

3. *Inoculation experiments on rabbits.*

I therefore collected conidia from one of the cultivations I had obtained from the spores found on the skin ulcers, and mixed them with sterilised water. Dr. Woodhead had the great kindness to inject this mixture for me into the peritoneal cavity of one rabbit, and into the anterior chamber of the eye of another rabbit. For this I wish to express my best thanks to him here, as, by the interest he took in the question, he saved me the trouble and delays which, in experiments of this kind, are generally experienced

Digitized by Google

in this country. Thirty-six hours after the injection the inoculated eye was distinctly affected. The conjunctiva was considerably inflamed and swollen; the anterior chamber was partly occupied by a white and opaque material, not looking like pus, and extending from the edge of the cornea towards the centre, leaving the greater part of the space in front of the pupil clear.

There was also distinct photophobia. Forty-eight hours afterwards, the animal having been killed, I found that the whitish matter was almost entirely composed of epithelial-looking cells, among which were a few swollen spores. The greater number of spores had, however, disappeared from the anterior chamber, having probably passed into the lymphatics or been destroyed. Owing to the difficulty of tracing the distribution of brown spores in the midst of the pigmented tissues of the eye, I have so far confined my observations to the rabbit in which the parasite had been injected into the peritoneum.

In this animal there were hardly any evidences of discomfort, except perhaps that thirty-six hours after inoculation it seemed quiet, and kept the abdomen more raised from the ground than is usual in healthy rabbits. Forty-eight hours after inoculation the abdomen was opened immediately after death. There was no evidence of general peritonitis, but at the seat of puncture, and in various other parts, numerous tubercles were found. Their diameter varied from ½ mm. to 3 or 4 mm. Many of them had some blackish material in their centre.

These nodules were most abundant in and about the central tendons of the diaphragm, the suspensory ligament of the liver, the mesentery, and the peritoneal folds about the back and sides of the bladder. There were, however, several small tubercles in the parietal layer of the peritoneum, and on the surface of several viscera, such as the liver and the intestine.

Some of the mesenteric glands were enlarged, congested, and contained numerous spores.

On microscopical section these tubercles were found to contain one or several groups of the brown spores. Even the smallest tubercles, which to the naked eye did not seem to contain any spores, were found under the microscope to follow the general rule.

Around each group of spores there was a zone of small round-cells, more or less altered, but evidently leucocytic in nature. Outside this zone there was in all cases a considerable increase of

Digitized by Google

fixed connective-tissue corpuscles, which formed round each tubercle a distinct layer of embryonic connective tissue.

In the case of the nodule found on the surface of the liver the subjacent tissues were much altered; thus many of the liver-cells had completely degenerated. In presence of such active changes I was surprised to find that there were only slight indications of germination on the part of the spores, especially where they had accumulated in large numbers. In none of the lesions I examined did I find any typical mycelium, such as has been observed in some of the cases of mycosis of internal organs which have been described. There could not be any doubt, however, as to the activity of the spores, and their appearance corresponded exactly to that which I observed in spores embedded for several days in the midst of a nutrient medium without access of air. Such spores germinate very slowly indeed, even at the temperature of the body.

Notwithstanding this, I suspected that perhaps I had introduced some other pathogenic organisms with the spores of the Aspergillus. I therefore stained several sections by the usual methods used for bringing out various forms of bacteria, but I failed to discover any other organism than the *Aspergillus niger* in them.

It seems, therefore, probable that during the early stages of germination some very irritating product must escape from the spores of that fungus, and that the extension of the mycelial filament causes only a small part of the irritation of the tissues, since, before any serious mechanical disturbance has occurred from that cause, lesions of considerable magnitude have already been produced.

4. *Effects of accidental inhalations in man.*

Involuntarily I obtained on two occasions experimental confirmation of that fact. Whilst cultivating the *Aspergillus niger* on a large scale for the purpose of studying its properties I had twice the misfortune to expose myself to breathe air loaded with conidia. In a few hours I became affected with an intense coryza, and redness of the conjunctivæ accompanied with fever and frontal headache. The day after the bronchi were also slightly affected. Each time I was in much discomfort for about three days, and then the symptoms subsided. Each attack reminded me strongly of hay fever, and to a certain extent of influenza. The first time, either owing

Digitized by Google

to the headache or for some other reason, I felt very ill for twenty-four hours; this was noticed not only by myself, but by several other persons. (It is quite possible that the spores of some of these moulds may have more to do with the production of hay fever than is suspected at the present time.)

For all these reasons I feel justified in considering that the *Aspergillus niger* is capable of inducing a considerable amount of irritation of animal tissues; and that although it is not under ordinary circumstances a serious source of disease, it may at times induce lesions, of which I give some instances in this paper.

5. *Form of parasitism; influence of heat, moisture, and lowered vitality of affected tissues.*

This fungus is, however, not a true parasite (obligatory parasite of De Bary), but essentially a saprophyte, becoming parasitic at times (*facultative parasite*—De Bary).

The conditions under which the Aspergillus niger *may become parasitic* are well indicated in this case. They are essentially—

1st. High external temperature.

2nd. Moisture due to retained secretions.

3rd. Inactivity or lowered vitality of the parts affected.

The *high external temperature* is necessary to promote the rapid production of the spores by the Aspergilli growing on their ordinary pabulum, which consists chiefly of decayed animal and vegetable matters, as will be shown hereafter. The present case occurred during the hottest months of the year 1890 (June, July), when I found it easy to grow the fungus on almost any material without the aid of artificial heat.

The *moisture* was the result of the retention of the secretions of the skin, the impermeable soap plaster preventing entirely evaporation. It is to be noticed that where the skin was covered with cotton bandage, and therefore comparatively dry, there was no trace of mould.

How the spores got under the strapping can only be surmised. The strapping itself was not mouldy. No other case of mycosis occurred in the hospital, although other portions of the same material had been used. There was no evidence of affection of the skin at the time the limb was strapped. One is therefore driven

Digitized by Google

to conclude that either the strapping or the skin had, just previously to dressing, been contaminated with spores of the *Aspergillus niger*. At that period of the year it is quite possible that the contamination may have taken place through the air. A single spore, as I have proved by cultivation, is capable of giving rise to several cubic centimetres of spores in the course of a few weeks.

The *effects of lowered vitality* are well shown by the occurrence of ulceration in the cicatrix of an old ulcer which partially seemed to have reopened.

V. Development and Variability of the Aspergillus niger.

1. *Observations.*

The considerations which precede show that the production of parasitic lesions is partly determined by the *respective states of the possible parasite and host;* they therefore invest with interest any study which may help one to grasp the relation between the various stages of the life of any pathogenic organism, or to understand the condition which may influence the greater or less development of any of these stages.

I have summarised the results of some experiments which I have made in this connection. They were carried out by means of ordinary *drop, test-tube, plate* (*capsule*), and *flask cultivations;* in addition I used the *interlamellar method* which I have described elsewhere.[1] Various cultivation media were used. These were either the usual ones—*e. g.* 1, potato; 2, ordinary glycerine nutrient gelatine (Nocard and Roux); 3, agar-agar; 4, glycerine agar-agar; 5, hydrocele fluid,—or simple substances such as—6, distilled water; 7, starch; 8, glucose; 9, cellulose; 10, gum-arabic; 11, egg albumen; 12, peptones; 13, pure gelatine; 14, paraffin,—or, again, various tissues, such as—15, horny epithelium; 16, muscular tissue; 17, adipose tissue. These cultivations were made in sets, and the effects of *temperatures ranging from* 10° *to* 45° *C.* were studied either in parallel specimens or in specimens submitted alternately to high and low temperatures. The effects of *free or limited access of air* were observed in some cases, and the effect of temperature was also noticed with reference to the *vital concurrence*

[1] 'Lancet,' June, 1891.

Digitized by Google

of the *Aspergillus niger* and *Penicillium glaucum.* The action of a few unknown bacilli was also witnessed in some cases quite accidentally. The *importance of moisture* was also ascertained in several cases.

It will be easy to understand the results of these experiments from a study of the following tables.

Digitized by Google

No. of experiment.	Date of inoculation.	Material inoculated.	Mode of cultivation.	Temperature.	Appearance of mycelium.	Appearance of conidia.	Time when was first noticed the appearance of	
							Mycelium.	Conidia.
1	1890 June 13	Glycerine, nutrient gelatine	Tube	20°–25° C.	1890 June 14–15	1890 June 15–16	Hours 36	Hours 48
2	"	Glycerine, agar-agar	"	"	June 16	June 18–19	72	120
3	June 20	Potato	Capsule	"	Rapid	Rapid	—	—
4	"	Water	Drop cultivation	"	Delayed	—	—	—
5	"	Nutrient gelatine	"	"	June 20–21 ?	June 21–22 ?	—	—
6	"	Hard paraffin and distilled water	Inter-lamellar film	"	July	July	—	—
7	July 2, 8 p.m.	Nutrient gelatine	"	"	July 3, 2 p.m.	July 7	Less than 18	—
8	July 2	Agar-agar	"	"	? later than 7th	? later than 7th	—	—
9	Dec. 31	Potato	Capsule	23° C.	1891 Jan. 2	1891 —	48	—
	1891 Jan. 2	—	—	10°–15° C.	—	Jan. 14	—	288
	Feb. 24	—	—	23°–30° C.	—	—	—	—
10	"	Potato	Capsule	23°–25° C.	Feb. 25–26	Before March 7	24 about	—
11	"	Starch	"	"	Feb. 26–28	"	48 about	—
12	"	Pure gelatine	"	"	Feb. 26	"	"	—

Digitized by Google

Some of the chemical products formed in media after growth of fungus.	Remarks.	Mother cultivation.	
		Nutrient material.	Date.
Liquefaction of gelatine, crystallised extractives; oxalate of lime abundant	... ...	Ulcer, skin	1890 May 11–June 10.
Considerable amount of oxalate of lime	... ...	"	"
Fluid products (softening of potato)	... ...	Nutrient gelatine, No. 1	June 13.
?	... ...	Gelatine, No. 1	"
Various crystalline products soluble in water and alcohol; oxalate of lime abundant	... ...	"	"
?	Mycelial filaments penetrating between the layer of paraffin and the cover-glass; the ends of the filaments produce conidia without previous formation of fruit-bearing hyphæ or distinct stigmata	Gelatine, No. 5	June 20.
Various crystallisable products, soluble in water (and alcohol ?); abundant production of oxalate of lime	Formation of spores delayed owing to experimental drying; abundant formation of oxalate of lime when filaments reach surface; gelatine liquefied and ultimately transformed into crystallisable products	Potato, No. 3	"
—	... ...	"	"
—	... ...	Gelatine, No. 1	June 13.
—	Between Jan. 2 and Jan. 14 a green mould [1] has appeared and grows rapidly, whilst the black fungus has grown slowly	"	"
—	The green stops by March 7; the black encroaches upon the green, and ultimately covers the whole surface	"	"
Potato softened and slightly discoloured	March 7: green mould[1] appears at side. March 9: the black mould appears to overtake it, and causes it to remain stationary	Potato, No. 9	Dec. 31.
Glucose	Mycelium very thin, widely spread; conidiophores discrete	"	"
Gelatose or gelatine peptone	March 9: gelatine liquefied, mycelium thin, conidiophores separate; no fairy rings	"	"

[1] *Penicillium glaucum*.

Digitized by Google

No. of experiment.	Date of inoculation.	Material inoculated.	Mode of cultivation.	Temperature.	Appearance of mycelium.	Appearance of conidia.	Time when was first noticed the appearance of	
							Mycelium.	Conidia.
13	1891 Feb. 24	Nutrient gelatine	Capsule	23°–25° C.	1891 Feb. 25–26	1891 Feb. 28–29	Hours 24	Hours —
14	"	Agar-agar (rather dry)	"	"	March 7	0	260	—
15	"	Glycerine, agar-agar	"	"	Feb. 27	March 9	72	—
16	"	Glucose (saturated nearly)	"	"	0	0	∞	—
17	"	Egg albumen (undiluted and possibly too dry)	"	"	0	0	∞	—
	March 9	—	—	39°	—	—	—	—
18	Feb. 24	Potato	Capsule	23° C.	Feb. 26	?	48	—
19	"	Starch (rather dry)	"	"	Feb. 27	Before March 7	72	144
20	"	Glucose (nearly saturated solution)	"	"	0	0	∞	—
	March 9	—	—	39°	—	—	—	—
21	Feb. 15	Peptone, Denaeyer's	Flask	10° C.	0	—	—	—
	March 5	—	—	39° C.	March 7	March 12	48	168
22	March 7	Potato	Capsule	39°–40° C.	March 8	Before March 9	12–24	36
23	"	Potato inoculated with *Asp. niger* on one side and *Penicillium glaucum* on other side	"	39°–40° C.	"	March 8	"	24
	March 12	—	—	35° C.	—	—	—	—

Digitized by Google

Some of the chemical products formed in media after growth of fungus.	Remarks.	Mother cultivation.	
		Nutrient material.	Date.
Liquefied. Oxalate of lime	Spores not very abundant, central tuft; fairy rings produced by intermittent growth of mycelium and spores; growth contaminated with *Penicillium glaucum*	Potato, No. 9	1890 Dec. 31.
—	Growth apparently stops after formation of a little mycelium, possibly the medium too dry; placed in 39° C. incubator; hardly any change	"	"
—	Mycelium very yellow; spores hiding nearly the whole mycelium. March 7: contamination	"	"
—	March 9: temperature raised to 39·5° C. No change after many days	"	"
—	... ...	"	"
—	Temperature raised to 39° C., but after many days no change can be observed	—	—
—	... ...	Agar-agar, No. 2	June 13.
Glucose	Rapid extension of a thin layer of mycelium all over the starch; the conidiophores much separated from each other, quite discrete	"	"
—	... ...	"	"
—	Temperature raised to 39°, but with no effect	—	—
—	... ...	—	—
—	Mycelium very scanty at first and distinctly yellow. Conidia also very few, growth evidently difficult. The fluid became contaminated after first opening, and the Aspergillus soon ceased growing	Gelatine, No. 1	June 13.
—	Excessively rapid growth of mycelium, which becomes heaped up in a hemispherical mass, soon becoming folded. Peripheral extension seems to be limited by the abrupt depression of the parts of the potato over which mycelium has grown. Mycelium very yellow; conidia few	Potato, No. 10	1891 Feb. 24.
—	The *Penicillium glaucum* shows no sign of growth till March 12	"	"
—	The *Penicillium glaucum* does not show any sign of growth. The *Asp. niger* grows quicker than at 39° C., especially the mycelium	—	—

Digitized by Google

No. of experiment.	Date of inoculation.	Material inoculated.	Mode of cultivation.	Temperature.	Appearance of mycelium.	Appearance of conidia.	Time when was first noticed the appearance of	
							Mycelium.	Conidia.
	1891 March 18	—	—	23° C.	1891 —	1891 —	Hours —	Hours —
24	March 13	Human epidermis	Capsule	39° C.	March 14	Before March 16	24–36	48–72
25	"	Subcutaneous fat	"	"	March 15	"	48	"
26	"	Human muscle	"	"	March 14	"	24	"
27	March 16	Coagulated hydrocele fluid	"	39°–40° C.	Before March 18	Mar. 18–19	24–48	48–72
28	"	"	Flask	23° C.	March 19 0	March 19 0	?	?
	March 20	—	—	39°–40° C.	March 21 ?	Before March 23	24	48–72
29	March 18	Swedish filter-paper	Capsule	39° C.	March 19	March 20	24	48
30	"	Pure gum arabic	"	"	"	Before March 23	24	96–120
31	April 30	Potato	"	40°–45° C.	Before May 1	?	12–24	?
32	"	Gelatine	—	"	May 1	?	24	?
	May 3	—	—	—	—	—	—	—
33	April 30	Starch	—	40°–45° C.	—	—	—	—
34	"	Paper	—	"	0	—	—	—
35	"	Egg albumen	—	"	0	—	—	—

Digitized by Google

Some of the chemical products found in media after growth of fungus.	Remarks.	Mother cultivation.	
		Nutrient method.	Date.
			1891
—	After 1 day at 23° C. the mycelium of *Penicillium glaucum* begins to grow. On March 23 green conidia abundant. The *Asp. niger* has grown slowly	—	—
—	In less than 3 days an area measuring 3 inches in diam. is covered with a radiating white mycelium, with a central clump of brown conidia. At the same time a very strong smell of manure is developed, such as is observed in connection with certain animal manure during the hottest days of summer	Nutrient gelatine, No. 13	Feb. 24.
—	Growth of mycelium and conidia very scanty compared with last specimen. Mycelium is denser and whiter. The smell is the same, but after a time a smell of rancid fat is superadded	"	"
—	The growth of the mycelium and spores incredibly rapid; in less than 1 week a surface 2½ inches in diameter is entirely covered with conidia; the mycelium is almost invisible. The conidia are of a more reddish colour than in other cases. Smell as above (24)	Gelatine, No. 13	"
Proteoses, &c.	Growth very rapid though not dense. Conidiophores discrete; tendency to arrangement in rings (like fairy rings). Smell of manure	Human muscle, No. 26	Mar. 13.
—	Same as above. On March 23 the cultivation is left at the ordinary temperature (under 20° C.)	"	"
Id.	Growth arrested at once.		
Glucose	Mycelium distinctly yellow. Conidiophores discrete, as in starch cultivations. Slight tendency to the production of concentric rings (fairy rings)	Hydrocele, No. 27	Mar. 16.
Oxalic acid, acetic acid, glucose (?), &c.	Extraordinary mycelial growth. In 5 days the mucilage has become almost white through it. This mycelium forms a kind of felt, holding in its meshes gigantic crystals of oxalate of lime. Conidia scanty. Smell very sour	"	"
—	Very rapid growth of mycelium; very yellow and heaped up; pleasant and somewhat fruity smell. The temperature hardly reached 45° C., and that for at most 1 hour	"	"
—	Very rapid growth of mycelium	"	"
—	The temperature hardly reached 45° C., and that for at most 1 hour.		
—	The temperature remained at 45° C. for several hours	"	"
—	Ditto	"	"
—	Ditto	"	"

Digitized by Google

No. of experiment.	Date of inoculation.	Material inoculated.	Mode of cultivation.	Temperature.	Appearance of mycelium.	Appearance of conidia.	Time when was first noticed the appearance of	
							Mycelium.	Conidia.
36	1891 May 1, 3–4 p.m.	Nutrient gelatine	Inter-lamellar film, spores 0·1 mm. from surface	40° C.	1891 May 2, 10 a.m.	1891 —	Hours Less than 18	Hours —
37	May 2–3 May 1, 3–4 p.m.	— Nutrient gelatine	— Inter-lamellar film, spores on surface and within 0·8mm.	25° C. 40° C.	— Before May 2, 10–11 a.m.	— Before May 2, 10–11 a.m.	— Less than 12	— Less than 18
38	May 2 May 1	— Nutrient gelatine	— Inter-lamellar film, spores 10 mm. from surface	25° C. 40° C.	— May 2, 10 p.m.	— ∞ ?	— About 30	— —
39	May 2 May 1	— Nutrient gelatine	— Inter-lamellar film, spores 10 mm. from surface	25° C. 40° C.	— ?	— ∞	— —	— —
40	May 2 May 1	— Nutrient gelatine	— Inter-lamellar film spores, 15 mm. from surface	25° C. 40° C.	— ∞	— ∞	— —	— —
41 to 45	—	"	—	—	—	—	—	—
46	April 30, 4 p.m.	Rabbit, black	—	—	May 2, 2 p.m. ?	—	—	—
47	" May 4	Rabbit, grey, peritoneal cavity —	— —	— —	— —	— —	— —	— —
48[1]	Aug. 7	Egg-albumen coagulated	Capsule in air saturated with moisture	38°	Aug. 8	Aug. 9, 1	—	—

[1] This additional observation, made after the reading of the paper, shows that on coagulated, circumstances of moisture and temperature.

Digitized by Google

Some of the chemical products found in media after growth of fungus.	Remarks.	Mother cultivation.	
		Nutrient material.	Date.
—	Growth of mycelium very rapid; mycelial filaments thick, branching, and septate. Spores beyond 2 mm. in depth hardly altered	Starch, No. 19	1891 Feb. 24.
—	... ...	—	—
—	The surface spores have formed, mycelial filaments very abundant, and already, after 24 hours, a dense network is produced. Conidiophores appear before the end of the first day; the spores are not yet coloured, and the fruit-bearers do not differ from other mycelial filaments. Up to a depth of 0·8 mm. spores have germinated	Starch, No. 19	Feb. 24.
—	... ...	—	—
—	Mycelial filaments very few, short, slender, and without septa. Only a small proportion of the spores have germinated, the others are either swollen or unaltered	Starch, No. 19	Feb. 24.
—	... ...	—	—
—	A few spores only swollen, the others unaltered	Starch, No. 19	Feb. 24.
—	... ...	—	—
—	Spores show hardly any change even after a week	Starch, No. 19	Feb. 24.
—	All these cultivations became rapidly contaminated with a bacillus; the spores became very irregular. Their progress was not followed afterwards	Hydrocele, No. 27	Mar. 16.
—	The anterior chamber of the eye has become full of desquamated cells, epithelial-looking. No distinct mycelium discovered. Spores swollen and beginning to germinate?	Potato, No. 3	June 20, 1890.
—	... ...	"	"
—	Numerous tubercles in the central tendon of diaphragm, the pelvic peritoneum, the mesentery; a few small ones in the parietal and visceral layers of peritoneum, over liver and intestine. All tubercles contain swollen spores, some of which are beginning to germinate. No mycelium yet	—	—
—	Growth extremely scanty	Starch, No. 19	Feb. 24.

undiluted egg albumen the *Aspergillus niger* can grow with difficulty under favorable

Digitized by Google

2. *Typical developmental stages.*

The results obtained were on the whole what might have been expected from the work of other observers in allied fields. Owing, however, to the very characteristic features of the *Aspergillus niger*, they were unusually clear.

I will, therefore, try to summarise these results so as to make them more available than by the inspection of the foregoing table, which I have not been able to render descriptive enough.

Development of the Aspergillus niger.—When grown on the surface of potatoes, or glycerine nutrient gelatine, at a temperature ranging between 35° C. and 40° C., typical spores of the *Aspergillus niger* pass through the following stages:

1st. Swelling and accumulation of pigment under the membrane; passage of pigment as through pores into surrounding medium; crenated appearance.	During the first 2 or 3 hours.
2nd. Appearance of one or two bright spots, then of one or two conical projections, which rapidly elongate, become cylindrical, and often have as large a diameter as the spore itself, at some distance from it. Some measure over 0·2 mm. in length. Two or three septa may have appeared in the longest; the segments nearest to the spore have a double outline, their protoplasma is granular, and contains also pretty large bright granules or vacuoles. The terminal segments are finely granular, thick, and appear to have no cell wall. Small bud-like projections appear on the sides of the filaments; these have the same character as the terminal segments.	Within the first 6 to 12 hours.
3rd. The filaments branch rapidly, and form a network, from which straight hyphæ, some like the others, some thicker, rise up into the air and at various heights from the surface. They become club-shaped. A number of small bud-like projections appear on these bladders; they grow radially, so that the sphere is surrounded by radiating filaments, all very nearly of the same thickness; some of these filaments branch, their extremities become constricted, so that a small rounded spore becomes partitioned off; a second spore is formed in the same way between the end of the filament and the first spore, and so on. These acrospores are the conidia, the filaments supporting them the sterigmata, the erect hypha with its bladder-	From the 12th to the 18th hour.

Digitized by Google

FIG. 22.

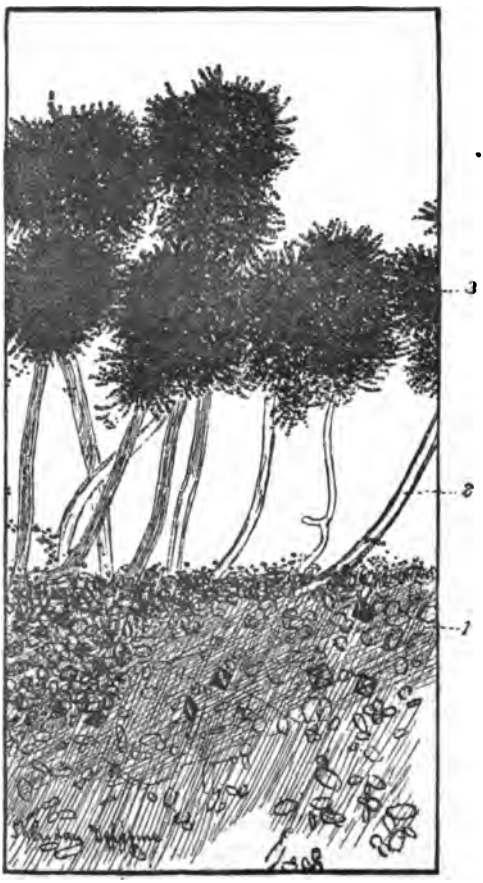

× 150

Side view of a cultivation of *Aspergillus niger* (obtained from the skin surrounding the ulcer of the leg).

1. Nutrient gelatine with mycelium (indistinct) and numerous crystals of oxalate of lime.
2. Conidiophores (fruit-bearing hyphæ).
3. Conidia (colour exactly that of soot).

Digitized by Google

like end is the fruit-bearing hypha of mycologists; it may be also called conidiophore for shortness' sake, but this term has not always the same meaning. As yet there is no evidence of any pigmentation, except a bright lemon-yellow coloration of the young conidiophores and of some of the ordinary mycelial filaments. One or two large oval protoplasmic masses are often seen in the thick fruit-bearing hyphæ. These masses gradually pass towards the club-shaped end; this takes place at the time when the sterigmata appear. Another phenomenon may also be observed at the same or perhaps before this time. Among the vegetative mycelial filaments some come in close contact, and between such filaments a kind of conjugation takes place; buds appear on corresponding points in the two filaments; these buds come in closer contact and become flattened against each other; the intermediate membrane is resorbed, and the contents of one segment of one of the filaments pass into the corresponding segment of the other.

From the 12th to the 18th hour.

It is evident that this conjugation must indicate some essential change in the properties of the hyphæ, for up to that period they have a marked tendency to separate from each other as widely as they can, so that if three spores placed together germinate, the filaments thus produced radiate in three different directions, and even their branches seem at first to avoid each other. This tendency is quite uninfluenced by light, heat, or even access of air. I take this to indicate that in the early stages of their growth the filaments impoverish and contaminate the surrounding medium within a certain radius, and that the growing point of other filaments of the same species grows naturally more luxuriantly on the side not exposed to the poisonous emanations than in the other direction. In favour of this influence of the pabulum I may mention that in large groups of spores only few germinate when there is no free oxygenation and the air is not kept very moist. The few filaments thus produced diverge as usual, but they are much more slender than when only two or three start from the same point.

4th. The mycelial filaments become more and more densely interwoven on the surface of the nutrient material. Many of the older filaments lose their protoplasmic contents, and are represented only by a transparent sheath. Some segments retain their protoplasma longer than others. The most superficial filaments become more and more vacuolated, their diameter increases considerably, especially at places where they become dilated

Within the first week.

Digitized by Google

Digitized by Google

DESCRIPTION OF PLATE IX.

To illustrate Dr. Delépine's paper on Melanomycosis of the Skin. (Page 423.)

From drawings by the author.

A. A fruit-bearing hypha (conidiophore) grown in a very narrow space between two glass plates (interlamellar method). The fructification is flattened, and the arrangement of the sterigmata is very distinct. The arrangement of the conidia is not typical, as they are not arranged in rows; this was apparently due to very rapid growth. × 450.

1. Hypha.
2. Its club-shaped end.
3. Sterigmata, branching very distinctly.
4. Proliferating end of the sterigmata from which the conidia arise; this region was very pigmented in this case.
5. Young conidia, hardly pigmented yet, very unequal in size.

B. Development of conidia and modifications brought about by nature of pabulum, amount of moisture, &c. (interlamellar method of cultivation being used).

1. First appearance of sterigmata on the club-shaped end of a future conidiophore.
2, 3. Constriction of peripheral end of sterigmata showing the mode of production of conidia.
4. Formation of chains of conidia, their gradual pigmentation.
5. A chain of conidia separated from the conidiophore; the conidia as they grow older become more pigmented, slightly warted, and become gradually separated, remaining connected by what seems to be an axial filament.
6. Sterigmata arising from the end of a hypha which has not become bulbous.
7 Conidia arising from an ordinary mycelial filament without the intervention of conidiophore or sterigmata.

Digitized by Google

Digitized by Google

Digitized by Google

and bladder-like; these swellings are sometimes so abundant as to give the filaments a moniliform appearance. When the mycelium has become so altered it seems at places to be replaced by a kind of loose cellular tissue. Meanwhile the conidia are increasing in number, and if the fungus is well protected from any disturbing influence chains of conidia of considerable length are produced. These conidia being all of the same size, or nearly so, the chains thus formed look like giant streptococci; at the same time the spores get more and more deeply pigmented as they get older; the link uniting them becomes more and more thread-like, and the spores somewhat flattened. Ultimately they look like rows of thick discs connected together by a central thread. Under certain circumstances they become regularly crenated, owing to the projection of small pigmented granules all over their surface. The sterigmata become often pigmented as well as the fruit-bearing hyphæ, and some of the most superficial vegetative hyphæ.	Within the first week.

3. *Variations.*

Without going into further details I may now mention briefly the various changes which are brought about by various circumstances.

1st. *Influence of pabulum* (temperature, moisture, &c., being the same or nearly so).

Potato, glycerine nutrient gelatine, muscle, skin, all appear to be excellent nutrient media, and on them both the mycelium and the conidia appear rapidly and abundantly.

On *potato* the mycelium generally assumes a yellow colour before the conidia appear; the growth of the mycelium and conidia is abundant.

On *glycerine nutrient gelatine* the growth is rapid, but both the mycelium and the spores are less abundant than in potato cultivation; the production of spores becomes intermittently arrested whilst the mycelium continues to extend peripherally; this leads to the production of concentric rings of conidia. This process is quite analogous to that observed in meadows, and giving rise to the production of the "*fairy rings,*" about which Dr. Wollaston wrote a paper in 1807 ('Philosophical Transactions,' 1807, p. 133).

Digitized by Google

On *skin* the growth is about as rapid as on nutrient gelatine, but the mycelium tends to grow abundantly in comparison to the conidia.

On *muscle* the growth of the fungus is extremely rapid; the mycelium is entirely hidden by a mass of conidia, which is much in excess of what is found in any other form of cultivation. The conidia have also a tendency to be pale in colour, very large, not well separated from each other, probably owing to very rapid growth.

Adipose tissue was found to be a less suitable medium than either skin or muscle; it favoured the formation of a dense white mycelium.

On *hydrocele fluid* the fungus grew rapidly but not thickly, the mycelium forming a thin stratum, and the conidia seldom forming dense clumps; they showed also a tendency to produce concentric rings (fairy rings).

On *concentrated solution of peptones* the growth was very slow, and spores appeared very late.

On *glycerine agar-agar* the growth was much slower, and the small mycelial masses usually took a deep yellow colour long before the conidia appeared; when this happened the whole mycelium was covered with a dense layer of conidia.

On *pure gelatine* the mycelium formed rapidly a thin layer of radiating filaments, with a clump of conidia in the centre, and discrete conidia bearers all over the surface.

On *ordinary agar-agar* only a very slight mycelial growth was obtained after days, but the material used in my experiments seemed to have got rather dry, and was found to grow badly other organisms also.

On *undiluted coagulated egg albumen* growth could be obtained only with difficulty and in very moist air.

Of the non-nitrogenous substances starch and gum arabic were found to be very good media.

On *starch* the mycelium spread very rapidly, forming a very thin layer, and the conidia-bearing hyphæ sprung at large intervals from each other and remained quite isolated; they sometimes reached a large size. They were very convenient for experimental purposes, since each conidiophore could be easily picked with a needle without any other being touched.

On *cellulose* (best Swedish paper washed with distilled water)

Digitized by Google

Digitized by Google

DESCRIPTION OF PLATE X.

To illustrate Dr. Delépine's paper on Melanomycosis. (Page 423.)

From drawings by the author.

FIG. A.—A small group of seven conidia (spores) of the *Aspergillus niger*.

FIG. A.—The spores had not altered, they had been only a few hours in the gelatine.

FIG. B.—The same group eighteen hours later.

FIG. B.—The spores had swollen and sprouted, some filaments had begun (for about two hours) to protrude beyond the surface. The deposition of oxalate of lime began very soon after this.

FIG. C.—Part of the filaments produced by the same group one month later. × 450. These spores were sown in an enclosed layer of nutrient gelatine (see 'Lancet,' June, 1891), and kept at the temperature of 23° C. in an incubator. The first day they were examined hourly, and after that daily. The dotted line indicates the shortest distance between the spores and the surface of the gelatine (mm. 0.15). The shading indicates the surface of the gelatine.

FIG. C.—The swollen and greatly altered mycelium as it appeared just under the surface of the gelatine one month after. Some filaments have conjugated, the protoplasm is much vacuolated.

Digitized by Google

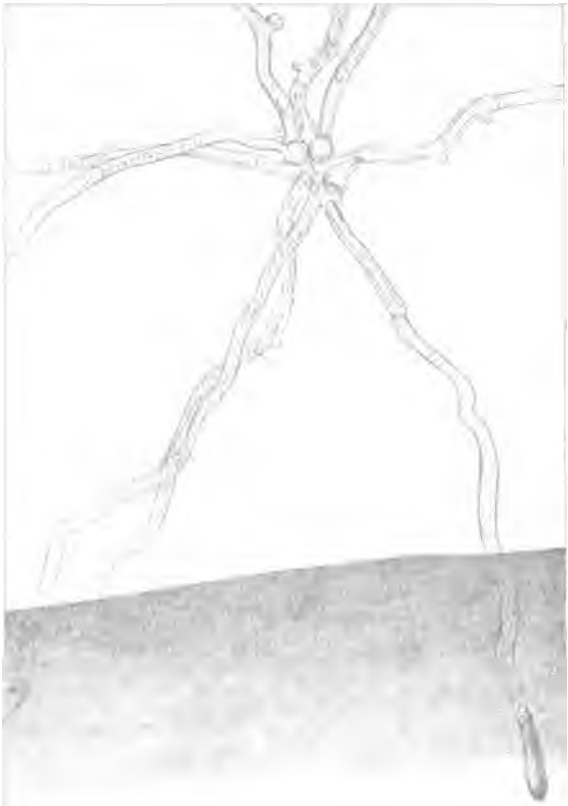

Digitized by Google

Digitized by Google

the *Aspergillus niger* grew well and quickly, though not abundantly. There was a central clump of conidia with discrete conidiophores all round.

In *mucilage* the mycelium grew with great rapidity and so abundantly that the whole mucilage was permeated with a dense network in about two days; this mycelium was composed of extremely large hyphæ, with very thick walls. Conidia appeared very late and scantily.

On *ordinary hard paraffin*, such as is used for cutting sections, the spores, when kept moist, germinated, and after many weeks gave rise to chains of conidia, very pale, *without the intermediation of ordinary conidiophores*. This acrogenous formation of conidia at the end of apparently ordinary mycelium filaments was observed in many other instances.

In *a thick solution of glucose*, of the consistency of honey, no mycelial growth could be obtained at any temperature.

In *distilled water* spores germinated after a long time, but probably by feeding on the other spores which had not germinated.

From these observations, most of which have been repeated several times with similar results, it is evident that, by *modifying its pabulum, it is possible to obtain several varieties of* Aspergillus niger.

(1) One with pretty *equal* production of *vegetative* and *reproductive* elements (potato).

(2) One with an *excess of reproductive* elements over the vegetative (muscle, glycerine agar-agar).

(3) One with a great *excess of vegetative* over the reproductive elements (mucilage).

In addition, the mycelium may be made to develop a *bright yellow pigment* (potato, glycerine agar-agar).

The mycelium may be made to cover rapidly large areas with a *sporadic production of conidiophores.*

Mycelium and conidia may be made to grow intermittently in excess of each other, and so as to produce an appearance similar to that known under the name of "*fairy rings*" (glycerine nutrient gelatine).

These varieties are *particular to the nutrient media*, since conidia, obtained from any of these cultivations, will give rise to new colonies having types corresponding to those described above, when grown on each special medium.

Digitized by Google

2nd. *Influence of temperature.*—The effects of temperature were similar to those observed in other pathogenic micro-organisms. On unfavorable nutrient media a temperature of 10° to 15° C. prevents or arrests the growth of the mycelium or conidia.

On the most favorable media the same temperature causes a very considerable delay in the growth of the mycelium, and still more in the appearance of conidia (thus, in one of the most successful cultivations, conidia appeared only after 288 hours, instead of being evident before the end of the first day, as when the temperature is most favorable). Both mycelium and conidia are extremely spare at this temperature.

At 20° to 25° C. the growth of mycelium and spores is tolerably rapid on the most suitable materials, but very slow on the less suitable media. The mycelium has a tendency to form a thin, evenly distributed layer.

At 35° both mycelium and spores grow with exceedingly great rapidity on most suitable materials, a thick mass of mycelium being formed in a few hours, and before the end of the first day conidia being already abundant.

At 39° and 40° C. the growth is very active, and spores are produced abundantly, even on apparently unsuitable media, such as pure cellulose.

Between 40° and 45° C. the cultivation succeeds only on the best nutrient media. The mycelium is produced so abundantly that it forms thick hemispherical masses which soon become deeply folded. The mycelial filaments form a denser felt than in previous cases. Conidia appear very slowly or not at all, at any rate in their typical form.

3rd. *Vital concurrence between the* Penicillium glaucum *and the* Aspergillus niger *at various temperatures.*—The coloured spores of these two fungi gave the means of obtaining some very clear demonstrations of the influence of temperature in the production of an apparent antagonism.

For the purpose of experiments I used either mixed conidia of the Aspergillus and Penicillium, and inoculated various media; or inoculated slices of potatoes in one place with spores of the one, and in another with spores of the other; then exposed them to various temperatures. The results obtained can be easily tabulated as follows:

Digitized by Google

Temperature.	*Aspergillus niger* growth.	*Penicillium glaucum* growth.	Result.
10° C.	0	Mycelium and spores abundant	Apparently nothing but *Penicillium glaucum.*
15° C.	Very slight of mycelium	Mycelium and spores abundant	Id.
20° to 25° C.	Moderate growth of mycelium and conidia	Moderate growth of mycelium and conidia	The two fungi grow equally side by side.
25° to 30° C.	More rapid growth of mycelium and conidia	Diminished growth of mycelium and conidia	The *Aspergillus niger* is slowly creeping over the *Penicillium glaucum* and hiding it.
35° to 40° C.	Very rapid growth of mycelium and conidia	0	Apparently nothing but *Aspergillus niger.*
40° to 45° C.	Very rapid growth of mycelium, but not of conidia	0	Apparently nothing but a mycelium, with no distinct features.

4th. *Influence of moisture.*—I was able to stunt the growth and cause swelling of the extremities of mycelial filaments by simply diminishing the amount of moisture in the air surrounding the *Aspergillus niger*. If, after stopping and modifying the growth by drying slightly the preparation, the organism is again exposed to the influence of air saturated with moisture, fresh offshoots are obtained from the clubbed ends of the stunted filaments (these clubbed ends are not to be mistaken for those of conidia-bearing hyphæ). In this way the branching of the filaments can be greatly modified. It is evident that under ordinary circumstances parasites and other fungi may be influenced by similar circumstances, and may thus exhibit alternate forms which are evidently connected with different degrees of growth and physico-chemical activity.

5th. *Influence of air.*—I shall have to refer to this again further on. I may, however, mention that if spores be placed at various depths in a suitable nutrient medium, such as glycerine peptonegelatine, only the most superficial ones grow.

Digitized by Google

The fungus is distinctly aerobic, yet within certain limits it can grow in the depth of the nutrient material, and then becomes modified. Spores placed *quite on the surface* grow well and rapidly, yielding within a few hours thick septate filaments, which branch rapidly on the surface of the gelatine, and at 35° C. yield within the first day typical conidiophores. Spores placed at a depth of 0·1 mm. germinate a little more slowly, produce long filaments, which become slightly thicker as they approach the surface, where they become rapidly branched, assuming the same form as in the last case. This is very distinct within twelve hours.

At *a depth of* 0·8 *to* 1 *mm.* they only begin to produce short mycelial filaments at the end of sixteen hours.

At a depth of 1·5 *mm.* the spores are swollen, often crenated, owing to projection of pigment through their wall, and show a bright nucleus-like body (also at the end of sixteen hours).

Beyond 2 *mm.* from the surface the conidia are only a little swollen or not altered at the end of the first day.

Even the spores placed at *a depth of* 10 *mm.* may occasionally germinate after thirty or more hours; but in such cases the filaments produced are extremely slender, and take weeks to reach the surface. If, however, they succeed in doing so, then, as they approach the surface, they get thicker and thicker until they acquire their normal size. Filaments grown under such circumstances may be as slender as the *Bacillus anthracis* in the leptothrix stage, and, as often the protoplasmic contents of some of the segments of the septate filaments disappear, whilst those of other segments remain, an appearance is produced, by which the few segments still containing protoplasma resemble long or short thick bacilli with square ends.

If mycelial filaments can be made to grow in nutrient matter without reaching its surface, or, after projecting beyond the free surface, are made to re-enter the substratum, they can be made to continue growing without producing conidia. This is probably the way in which mycelial filaments may multiply to a considerable extent in fluid media without producing conidia. As they grow they sink into the fluid and remain surrounded by it until a sufficiently thick layer is produced, the surface of which gradually emerges from the fluid medium.

Digitized by Google

VI. Effects of the Growth of the Aspergillus niger on Various Media.

In the course of the investigations just related, I observed a number of changes which were distinctly brought about by the growth of the fungus. Without entering into lengthy details, I may summarise these observations.

Nutrient material.	Products found after cultivation of *Aspergillus niger*.
Pure cellulose	Glucose.
Pure starch	Glucose.
Best gum arabic	Glucose, oxalic acid, acetic acid.
Best gelatine of commerce . . .	Gelatose (gelatine peptones ?).
Solidified hydrocele fluid . . .	Proteoses (peptones ?).
Glycerine, peptone gelatine . .	Oxalic acid, abundant.
" " " . .	Crystalline extractives replacing ultimately nearly the whole gelatine.

It is useless to consider the changes resulting from the growth of the fungus in more complicated food-stuffs, since it would be difficult to understand their meaning so long as the changes observed in simple compounds are not quite clear.

It is evident that most of the products mentioned above are the results of some hydrolytic process.

The *formation of glucose* may be graphically represented as follows:

$$\underset{\substack{\text{Starch, Cellulose,}\\ \text{Arabic acid, or Arabin.}}}{C_6H_{10}O_5} + H_2O = \underset{\text{Glucose.}}{C_6H_{12}O_6}.$$

Oxalic acid can be obtained by oxidation of cellulose, starch, and allied products. In the experiments related above the presence of oxalic acid was rendered evident whenever some salt of calcium was present in the nutrient medium. It is well known that lime and other bases are abundantly present in gum acacia when they are supposed to form salts with arabic acid. Lime is also pretty abundant in the ordinary nutrient jelly, as can be proved by the addition of oxalate of ammonia. Whether the oxalic acid is produced by oxidation of the glycerine or of the nitrogenous

Digitized by Google

compound is difficult to say. I have, however, not been able to make gelatine yield any oxalate of lime under the influence of the Aspergillus; but perhaps there was not enough lime present in the specimen I used.

Gelatoses and gelatine peptones.—The formation of these products was indicated only by their solubility and the biuret test (the quantities experimented upon not allowing the precipitation methods to be used in order to determine further the variety of compound obtained). As *Hofmeister* has shown, these products must be the result of the hydration of gelatine. *Chittenden* and *Solley* have lately supported the same view, although they have not been able to prove it by analysis.

Proteoses or *peptones* were also demonstrated after the growth of the fungus, although the quantities obtained were too small to allow of separation being attempted; these substances must also have been produced by hydrolysis of the albumin and globulins used as cultivation media (hydrocele fluid).

Although these experiments are few, yet they all point so clearly to the same conclusion that, even on their basis, it seems justifiable to assert that whatever the material used (provided it allowed the fungus to grow), the changes brought about were either those associated with digestive processes (glucose, gelatoses, proteoses, peptones) or with regressive metabolism (oxalic acid, &c.).

The production of oxalic acid was, perhaps, the most interesting of these phenomena connected with the growth of the fungus. It was much more abundant in some media than in others; thus the production of oxalate of lime out of gum acacia was extraordinarily abundant.

This production of oxalate of lime was distinctly connected with the exposure of the mycelial filaments to air.

So long as the filaments were embedded in nutrient gelatine, for instance, no crystal of oxalate of lime was observed. No sooner did they project for some distance beyond the surface than crystals began to appear in the superficial layers of the gelatine and in deeper layers along the filaments to which air had access. This last fact is of considerable interest in connection with the probable influence which protoplasmic respiration has on the metabolic products which have just been enumerated.

The production of oxalate of lime takes place by steps, and before typical crystals are formed other crystalline forms are evident,

Digitized by Google

some of which undoubtedly indicate the presence of some other compounds, for they are soluble in water. Crystals of oxalate of lime after a time accumulate to such an extent as to form with the mycelium a kind of white crust, and it is at this stage that the large cellular-looking swellings of the mycelium occur. Conidia are abundantly produced at the same time. The changes observed in nutrient gelatine do not stop at simple peptonisation; further important modifications must occur, for after a week or two a drop of the liquefied gelatine, when allowed to evaporate, yields a large mass of fine, prismatic, lozenge-shaped, acicular crystals, some of which form very elegant dendritic masses. These crystals are entirely soluble in alcohol and water, and, as I have not ascertained their composition, I will call them for the present extractives.

To the facts which I have just enumerated, and which indicate the fermentative action of the *Aspergillus niger*, I should add also that *Th. van Tieghem* had already, in 1868, connected the *gallic fermentation* with the growth of the *Aspergillus niger* in this fermentation. *Tannin* by hydration becomes converted into *gallic* and *acid glucose* (Van Tieghem, 'Ann. de Sc. Nat.,' 5e Série, viii, 1868).

On the other hand, *Fernbach*, working in Pasteur's laboratory, has shown that *saccharose* could be *interverted* by the *Aspergillus niger*, which he considers must contain a diastatic ferment (sucrase) ('Annales de l'Institut Pasteur,' 1889, pp. 473—531, and 1891, p. 1).

VII. General Considerations on the Hydrolytic Action of Living Protoplasm.

Thus through all these observations it seems proved that *hydrolysis* of almost any organic product can be produced by the *growth of the Aspergillus niger*. It would, according to our present notions of enzymes, be capable of producing a *proteolytic ferment* (*a gelatolytic ferment*), *an amylolytic ferment, an inverting ferment, an oxalic acid ferment, an acetic acid ferment, and probably a host of other ferments.*

When we deal with a compound organism like a mammal, it is easy to imagine that the cells of various organs have the power to manufacture special ferments, all specific, and having limited chemical properties. When, however, an organism which, like the

Digitized by Google

Aspergillus niger, is composed of cells which, independently of any marked morphological alterations, are capable to produce in turn all the hydrolytic actions which are attributed to the presence of special ferments, then one is almost driven to the conclusion that the production of so many different ferments by the same cell is problematical. The fact that active bodies can be extracted from the products of the secretions of certain cells, and may be made to bring about definite changes under definite chemical and physical conditions, seems equally unanswerable. There are, however, marked differences of activity between the artificial digestive fluids and the natural processes of digestion. One is almost tempted to believe that the action of these products is more or less related to their *not distant connection* with a living cell, without which their mode of action becomes more and more allied to that of chemical reagents in an *ordinary dynamical state.*

It is perfectly clear that protoplasm can hardly live without hydrolysing its surroundings, and that *hydrolysis seems therefore to be one of the concomitants of life.* This is not given here as a new idea. When an organism has, like the *Aspergillus niger*, the power to adapt itself to a great variety of circumstances, it becomes possible to demonstrate that this hydrolytic action of living protoplasma gives rise to *products which depend less on the cell itself than on its surrounding media. The adaptability of an organism to various circumstances renders it therefore capable to acquire properties which may become extraordinary when the circumstances themselves are not the ordinary ones under which it is generally known to us.* On these grounds there can be no serious theoretical objection to the supposition that a non-pathogenic organism may at times become pathogenic.

VIII. Bibliographical Appendix (Mycoses).

Author.	Reference.	Year.	Nature of contribution.
Bezold	Ueber Otomycosis zur Ætiol. d. Infect. (Munich)	1881	*Aspergillus fumigatus, nigricans,* and *flavescens* found in the external meatus, as well as other organisms, such as the *Trichothecium roseum.* They excite inflammation. Oil favours their development.

Digitized by Google

Author.	Reference.	Year.	Nature of contribution.
Bizzozero and Firket	Manuel de Microscopie Clinique (Bruxelles)	1888	The presence of *Aspergilli* in the external meatus was first observed by *Pacini* and *Meyer*, and is of more importance than was suspected at first. Other fungi are also found in the same situation, *e.g.* *Ascophora elegans*, *Trichothecium*, *Mucor mucedo*, *Peziza*.
Chittenden and Solley	Journal of Physiology, vol. xii, p. 23 (Cambridge)	1891	The primary cleavage products formed in the digestion of gelatine.
De Bary	Morphologie und Physiologie der Pilze, ii, Bd. i (Leipzig)	1866	Morphology and classification. Forms of parasitism.
Fernbach	Annales de l'Institut Pasteur, pp. 473—531	1889	Production of a diastatic ferment (sucrase) by the *Aspergillus niger* (see note at the end of the Appendix).
	Ibid., p. 1	1891	
Flügge	Fermente und Mikroparasiten (English translation by Watson Cheyne, London)	1886 1890	Description of mould fungi. Classification. Pathogenic properties. Reference to various writers, some of which are not mentioned here. Literature.
Fränkel	Deutsche med. Wochensch., No. 31	1885	Cultivation of *Aspergillus fumigatus* at a temperature of 51° C. for half a year prevents formation of spores, but when temperature is brought down to 37° C. conidia are produced again, which are as virulent as if the fungus had been grown in the usual way.
Leber	Grafe's Arch., xxv	—	Growth of *Aspergilli* in the human cornea and in the anterior chamber of the eye of rabbits. Suppurative inflammation.
	Berl. klin. Woch., Nos. 9 and 10	1882	
Lichtheim	Berl. klin. Woch., No. 9	1882	*Aspergillus fumigatus* found in the lungs.
Rother	Charité Annalen, iv Jahrgang, 1877, p. 272 (Berlin)	1879	Woman with extensive bronchitis, and hardly recovered from pneumonia, expectorated *débris* of pulmonary tissue containing mycelium and sterigmata of some *Aspergillus*. The patient recovered.
Schubert[1]	Deutsches Archiv für klin. Med., T. xxxvi	1885	Woman, æt. 75, in a state of marasmus. Naso-pharyngeal cavity covered with mycelium of *Aspergillus fumigatus*. Small ulcerations. Growth arrested by boracic acid after several relapses.

[1] Schubert remarks that the lungs were free, although conidia must have been carried into the air-passages by the air. As he describes the mycelium as greyish white there were either no spores at all, or else he mistook some other fungus for the *Aspergillus fumigatus*.—S. D.

Digitized by Google

Author.	Reference.	Year.	Nature of contribution.
Schütz	Mitth. a. d. Kais. Ges. Amt., Bd. ii	—	*Pneumono-mycosis Aspergillana.* — Severe pneumonic inflammation occurring in pigeons and geese, and generally caused by the *Aspergillus fumigatus*, and more seldom by the *Aspergillus niger*. Mammals may be affected in the same way.
Siebenman	Die Fadenpilze (Wiesbaden)	1883	Description of the characters and growth of the *Aspergilli*. Literature.
Van Tieghem	Annales des Sciences Naturelles, 5e série, viii	1868	Gallic fermentation (of tannin) under the influence of *Aspergillus niger* and *Penicillium glaucum*.
"	Bulletin de la Société Botanique de France	1877	Development of some *Ascomycetes* (*Aspergillus*).
Wollaston	Philosophical Transactions	1807	Production of "*fairy rings*." Mycelium exhausts the ground in the central parts and persists. At the periphery the visible receptacles of the Agarici (then called fungi) grow and then decay, producing a rich manure, which causes the grass to grow luxuriantly. From the spores produced by these receptacles fresh mycelium is produced, which extends further, a wider circle of receptacles is produced, and so on.
Ziegler	A Text-book of Pathological Anatomy, i, p. 316 (Translated by MacAlister, London)	— 1883	Inflammatory and necrotic changes produced by *Aspergillus fumigatus* and *flavescens*. References to other observers.

Fernbach's experiments with the *Aspergillus niger* are extremely interesting, and bear so much on the mode of production of substances, which may give to the so-called toxalbumins or albumoses some of their prophylactic properties, that I need no excuse for alluding to them here.

When the *Aspergillus niger* is grown in *Raulin's fluid* (saccharose 17·6 gr., free tartaric acid 0·72 to 1·8 per 1000) at a temperature of 35° C., this fungus grows rapidly. Whilst it is growing the saccharose is at first rapidly transformed into interverted sugar. When all the sugar has thus been transformed and used up, the plant, instead of increasing in weight, begins to lose weight. During the first day, when the saccharose is being interverted, the acidity of the fluid is rapidly increasing, but after this it dimin-

Digitized by Google

ishes. By careful analyses Fernbach estimated the amount of the ferment (sucrase), to the action of which he attributes the inversion of the sugar. (He estimated this quantity by means of the *sucrase unit*, which is the quantity of it necessary to invert 20 centigrammes of saccharose in one hour at the temperature of 56° C. in presence of $\frac{1}{100}$ of acetic acid.)

The results which he obtained are given in the following table:

Duration in twenty-four hours.	Saccharose remaining in fluid.	Quantity of interverted sugar in fluid.	Saccharose used up.	Acidity.	Sucrase in fluid.	Sucrase in fungus cells.	Weight of fungus.
	Grammes.	Grammes.	Grammes.	Grammes.	Units	Units	Grammes.
0	4·44	—	—	0·170	0	0	A few spores only
1	1·36	2·36	0·92	0·293	2	58	0·65
2	0·22	1·65	2·57	0·368	3	47	1·265
3	0	0·7	3·74	0·267	5	45	1·78
4	0	0	4·44	0·143	10	44	1·65
5	0	0	"	0·135	13	35	1·61

These experiments show well that the agent sucrase, to which the chemical activity (considered here) of the fungus is due, is closely connected with the cells themselves. It is only when their source of activity seems exhausted that any marked fraction of this activity seems to be transferred to the surrounding media. At the same time, however, the total weight of the plant and the total amount of the "ferment" diminish. These facts, considered in the light of the almost universal fermentative activity of the *Aspergillus niger*, which I have tried to make evident, seem to indicate that perhaps *too much has been attributed to the action of enzymes, independently of their connection with living cells.*

Digitized by Google

11. *Charcot's crystals in sputum containing a croupous cast.* (*Card specimen.*)

By Sheridan Delépine, M.B., B.Sc.

[With Plate XI.]

Not having been able to ascertain the nature of the case from which this specimen was obtained, I simply show the preparation for comparison with the others. The sputum had been sent to me for the purpose of finding tubercle bacilli in it, and from that I suppose the case was not typically one of asthma.

Products in which Charcot's crystals have been observed.—Leucæmic spleen (Charcot and Robin), 1853. Leucæmic blood (Charcot and Vulpian). Hepatic blood in a case of anæmia (Wagner). Dried human semen (Boettcher). Bone marrow in leucæmia (Neumann). Expectorations in asthma (Leyden, Ungar, Curschmann). Expectorations of phthisical patients (Ungar, Fraentzel). Expectorations in bronchial catarrh (Bizzozero and Firket). Tumour of optic nerve (Foerster). Sarcoma (Zenker). Carcinoma (Firket). Prostatic fluid (Fuerbinger). Intestinal contents, &c.

January 20th, 1891.

---

12. *Charcot's crystals in an alcoholic extract of a liver in a state of acute atrophy (yellow and red).* (*Card specimen.*)

By Sheridan Delépine, M.B., B.Sc.

[With Plate XI.]

These specimens gradually formed in an alcoholic extract of the liver. The liver had been kept in the spirit for about two years when these crystals were first noticed, and as the vessel was not tightly closed a certain amount of evaporation had taken

Digitized by Google

Digitized by Google

DESCRIPTION OF PLATE XI.

To illustrate Dr. Delépine's specimens of Charcot's Crystals. (Page 458.)

From drawings by the author.

FIG A.—Crystals found in an alcoholic extract of a liver in a state of acute yellow atrophy. The long acicular crystals of tyrosin appeared first after slow evaporation of the alcohol. In the course of the following year the large spindle-shaped and slightly sigmoid crystals appeared amongst the crystals of tyrosin.

FIG. A shows the crystals as they appear when examined in spirit or water.

FIG. B.—Charcot's crystals found in a croupous bronchial cast. Most of these crystals are embedded in the croupous products, a few are free on the surface.

FIG. B shows them as they look after being mounted in Canada balsam.

Digitized by Google

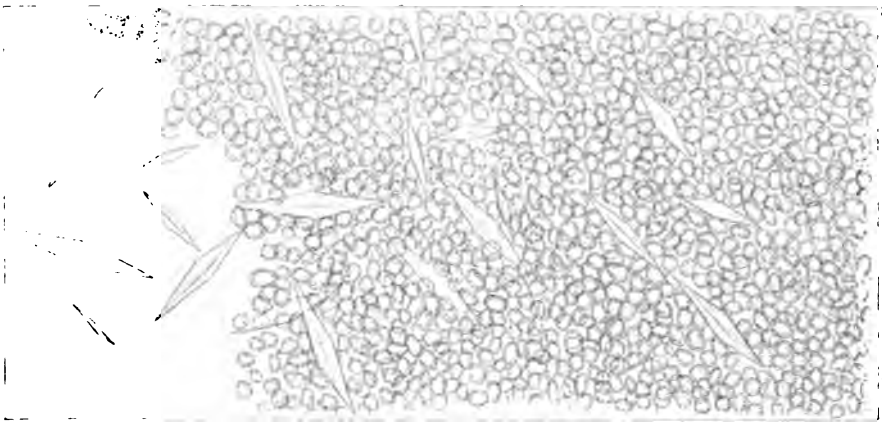

Digitized by Google

Digitized by Google

place. At first the spirit contained a very large amount of leucin and tyrosin, some of which are still present in the specimen exhibited.

The somewhat sigmoid, spindle-shaped crystals which are exhibited have all the characters of Charcot's crystals. They are fragile, soluble in boiling water, practically insoluble in cold water, soluble in most organic and inorganic acids and bases. Insoluble in alcohol, ether, chloroform, and turpentine. They are supposed to be phosphates of a basis discovered by Schreiner and called *spermine*. This spermine is supposed now to be the active principle of Brown-Séquard's fluid (testicular extract).

January 20*th*, 1891.

---

13. *Charcot's crystals in fæces.* (*Card specimen.*)

By Sheridan Delépine, M.B., B.Sc.

This alvine discharge came from a female child, twelve years of age, about whom Dr. Lauder Brunton was consulted during the month of June, 1890. The child had had measles, and soon after convalescence is supposed to have caught cold. She was taken with diarrhœa and much pain in the abdomen. The evacuation soon became dysenteric in character. No physical sign could be detected. I am indebted to Dr. Brunton for two specimens of the fæces obtained on the 20th, and the other on the 27th of June. These two specimens were similar in characters.

Description of the fæces.—Very thin, watery, brownish, greenish yellow, semi-translucent. Sediment composed of an upper layer of greyish, yellowish white opaque matter, and of a thinner lower layer, composed of reddish orange, coarse granules resembling cayenne pepper. The smell of the fluid was peculiarly sour and unpleasant. The filtered fluid was alkaline, gave clearly an albuminous precipitate, but no bile-pigment reaction. The reddish masses at the bottom, when treated with nitric acid, gave the usual play of colours indicating the presence of bile-pigment, and

Digitized by Google

on account of their colour were supposed to be some form of bilirubin usually absent from the intestine.

Microscopical examination.—The following were all found in the two specimens examined:—1. Phosphate (triple and calcic); 2. Tufts of fine curved needles (fatty acids); 3. Small sheaves of prismatic crystals (probably tyrosin); 4. Fatty-looking rounded masses with concentric markings (probably leucin); 5. Bright orange-yellow colloid or resinous-looking masses, giving the reactions of bile-pigment (bilirubin); 6. Pale greenish-yellow masses, giving also the bile-pigment reaction; 7. Small plugs of mucus; 8. Fatty granules; 9. Bacteria of all sorts very abundant; 10. Food *débris* and charcoal particles very abundant; 11. Typical *Charcot's crystals* abundant all through the fluid.

January 20th, 1891.

---

14. *Case of chronic general nodular tuberculosis*, i. e. *multiple tubercular tumours throughout the body, many in brain; no symptoms save indefinite one of tumour of the brain.*

By Samuel West, M.D.

Frederick J—, aged 14, was admitted into the Royal Free Hospital for severe headache, loss of sight, and optic neuritis.

The family history was good; out of nine children three died as infants, but the rest were well, as was the patient until the commencement of his illness a year ago. Then he began to feel weak, and found his work too much for him; and though he has at times been able to do a little light work he has not been in continuous employment since. One month ago he began to suffer from attacks of severe frontal headache, which was at first general over the whole head, and subsequently became most marked over the left eye. He vomited from time to time without cause, and about three weeks ago for the first time noticed that his eyesight was failing, for which he applied for relief to Mr. Mackinlay at the South London Ophthalmic Hospital, and was sent on to me at the Royal Free Hospital.

The patient was a tall, delicate lad, pale and thin. Physical

Digitized by Google

examination revealed nothing abnormal in thorax or abdomen, and the urine was healthy. A few enlarged glands were present under the jaw on each side, in the axilla, and in both groins. There was no paralysis to be discovered, and the reflexes, both superficial and deep, were normal.

The only positive sign of disease was double optic neuritis, the pupils being equal and reacting to light well. The discs were greatly swollen, and the effusion extended for some distance beyond them. There were a few small hæmorrhages and white patches. These changes were more marked in the left eye.

The diagnosis was made of cerebral tumour, but there was not enough in the symptoms to fix its position. As regards the nature of the tumour, the probabilities seemed to be in favour of its being tubercular. Although there was no history of syphilis, it was still thought wise to place the patient on full doses of iodide of potassium with some mercury; but when after some time no change was detected, these drugs were given up and tonics administered.

There is really very little to record in the subsequent history of the case beyond the gradual failure of the patient's strength and nutrition during the five months that he was under treatment.

The optic neuritis, though the amount of effusion seemed to vary from time to time, and some hæmorrhages disappeared and fresh ones took their place, never materially improved, while the sight became steadily worse, until just before death it was completely lost in both eyes. The pains in the head, though never so severe as at first, recurred continually, but lasted only for an hour or two at a time. The vomiting, too, was very irregular but never severe.

The patient had three or four fits at regular intervals, the first occurring a month after admission. They were never severe, and threw no light upon the case. They seemed to begin generally upon the right side, but affected both, even when quite slight. During the last month of life complaint was made of attacks of numbness on the right side, but no defect of sensation could be made out.

During the last month the patient rapidly lost flesh and strength, and for the last few days was troubled with diarrhœa, gradually became dull, drowsy, and finally comatose, and died just five months after admission.

The only additional fact that remains to be mentioned is that during the last five or six weeks a tumour developed on the right

Digitized by Google

wrist, which felt soft and doughy, but was not painful, and was accidentally discovered.

Post-mortem examination.—Body much emaciated. Pleura adherent on both sides in places. A few yellow nodules on both the parietal and visceral layers, some of which only corresponded with the adhesions; the largest the size of a small nut, and attached to the parietal layer, but not connected with the periosteum or ribs. The lungs everywhere crepitant, but studded with small nodules, most grey, but many yellow, and all firm and looking like chronic tuberculosis.

The bronchial glands much enlarged, firm, yellow, and caseous; one or two softening in the centre; the largest gland as big as a small Tangerine orange and very hard.

The peritoneum studded on both parietal and visceral layers with similar nodules of small size, several of which were on the capsule of the liver and spleen, but did not involve their substance.

On the stomach there were also several similar flat nodules, but section showed that they also did not extend beyond the peritoneal coat, nor did they produce any projection in the interior. The mesenteric glands much enlarged and caseous.

Throughout the small intestines were scattered numerous transverse ulcers, having the ordinary appearances of chronic tubercular ulcers, of sizes varying from ⅓ to 1½ inches or more. The only peculiarity they presented was in the absence in most of them of any tubercular nodules on the peritoneal surface corresponding with them; the ulcers began high up in the jejunum, but became more numerous and larger towards the cæcum, and just above the valve coalesced to form one large ulcer of several square inches in extent, as is so common in intestinal tuberculosis. Some of the mesenteric glands immediately beneath the intestine were enlarged, and one as large as a cherry had become adherent to the intestine and burst into it.

The kidneys were enlarged, but the capsule stripped off readily, and, unlike the capsules of the liver and spleen, contained no nodules; but the gland itself was studded throughout with large caseous nodules of all sizes, from that of a barleycorn to that of a small cherry.

The swelling on the left wrist was connected with the sheath of extensor tendons, and was found to be formed of thickened tissue, and to contain much softening caseous matter.

Digitized by Google

On opening the skull the dura mater at the base of the brain was found studded with small masses of growth of a similar character to those met with elsewhere. These masses were most numerous in the left posterior fossa. One or two similar nodules were found over the parietal region, but free from adhesions to the pia mater or brain.

In the brain itself several hard masses were felt, and after hardening tumours were found in the following places:

1. On the under and inner side of the right frontal lobe, beneath the grey matter of the internal orbital convolution.

2. In the white substance corresponding with the left third frontal convolution, a little in front of Broca's convolution.

3. In the upper part of the ascending frontal on the right side, extending 1 inch from the surface, which it just reached. This tumour was the size of a large filbert, the long axis being directed towards the lateral ventricle.

4. In the upper part of the left ascending parietal, one inch from the longitudinal fissure.

5. In the left optic thalamus, which was almost entirely replaced by tubercular growth.

6. In the floor of the left lateral ventricle, just at its bend, involving the junction of the hippocampus major and minor.

7 and 8. In the middle of the white matter of the right occipital lobe.

9 and 10. Behind these, one in front of the other, in a similar position.

11 and 12. Symmetrical with the preceding in the left occipital lobe.

The lateral ventricle was greatly dilated in all its parts.

I have ventured to call this case by the name chronic general nodular tuberculosis, to indicate its peculiar nature, and the strong contrast which it presents to the acute general miliary form.

Its pathological interest lies in the great numbers, large size, and wide distribution of the tumours. Such cases are, I believe, rare; at any rate, no instance of the kind is recorded in the recent volumes of the Society's 'Transactions.' The clinical interest lies in the entire absence of symptoms until one month ago. The only diagnosis possible was that of a tubercular tumour of the brain, but its position was uncertain at the time of death.

Digitized by Google

15. *Tuberculosis of finger (tendon-sheath, &c.).*

By E. C. Stabb.

E. R—, widow, aged 66. Two years ago she ran a fork into the palmar surface of the left middle finger at its base. The fork penetrated deeply, so that it still hung from the hand when the latter was held up, and it had to be pulled out. No bleeding. Finger was stiff and painful for some days, during which poultices were applied.

Two months afterwards she first noticed a small lump at site of puncture, followed shortly by others, which coalesced with the first, forming one swelling; and this gradually increased in size, and rendered her finger stiff and useless. Was treated as an out-patient at St. Thomas's Hospital for seven months before admission. Diagnosis was compound ganglion, which was punctured without any result, but after a small incision a number of semi-gelatinous melon-seed bodies were expressed on two occasions. After the second incision the wound filled up with granulation tissue, and patient was admitted for amputation in February, 1891, and the finger removed at the metacarpo-phalangeal joint. On examination of finger after removal the bones and joints were found to be normal, but all the soft parts replaced by a gelatinous mass, in which the tendons could not be distinguished. There was one small cavity filled with caseous material.

On microscopic examination of the tissue it proved to be tubercular in nature. There is no family history of phthisis. Patient has always been a strong and healthy woman, and there are no signs of disease in her lungs or other organs. No enlarged glands in axilla.

The clear history of a punctured wound followed by swelling, starting from the site of puncture, and the absence of tubercle, as far as can be ascertained, from any other part of the body, would suggest the case as being one of inoculation. *April 7th*, 1891.

Digitized by Google

16. *Symmetrical hemiatrophy of the gastrocnemii muscles.* (*Card specimen.*)

By J. H. Targett.

The specimen exhibited is a portion of a right gastrocnemius muscle, showing fatty metaplasia of its muscular tissue limited entirely to the *inner* belly. The affected part is somewhat broader than the outer belly, and its greatest thickness is an inch and a quarter against three eighths of an inch on the unaffected side. It appears to consist of a mass of fatty tissue which has replaced the muscular substance, but at the same time preserved its original shape. The anterior or deep surface of the muscle presents the usual tendinous expansion, and superficially it is covered with a thin fibrous membrane prolonged from the upper extremity of the muscle, as in the normal condition. A few small bundles of unaltered muscular fibres may be seen in some parts of the fatty mass, giving it a streaky appearance. The transverse section shows the outlines of the original fleshy bundles very clearly.

The opposite (left) gastrocnemius is similarly affected. The *inner* belly of the muscle measures 3¼ inches in breadth, while the outer is only 2 inches across; the former is 1 inch in thickness, the latter is only ⅓ an inch. The upper end of the diseased portion shows a superficial layer of unaltered muscular tissue, but its lower half is entirely converted into fat. Microscopic sections of large branches of the left internal popliteal nerve exhibit changes in many of the bundles. The perineurium is remarkably thickened, and almost tendinous in character; and there are evidences of chronic inflammation in the interior of the nerve-bundles. Owing to the shrinkage of the nerve-fibres within, the thickened perineurium is thrown into folds, closely resembling the elastic lamina of an artery. The medullary sheaths and axis cylinders of the nerve-fibres are much wasted. Sections of the posterior tibial nerve are normal, but the condition of the nerves above the knee-joint is not known.

The preparation was taken from a female dissection subject, aged 81 years, of whom no history could be obtained. There was no deformity of the lower extremities. *May 5th*, 1891.

Digitized by Google

17. *Spina bifida associated with cystic horse-shoe kidney.* (*Card specimen.*)

By Raymond Johnson.

The specimen is from a male child, aged 4 weeks, under the care of Mr. Christopher Heath in University College Hospital. The coverings of the tumour sloughed, and the cause of death was purulent meningitis extending upwards to the foramen magnum.

The spina bifida involved the column below, and including, the last dorsal vertebra, measuring $3\frac{1}{2}$ inches in length and $1\frac{1}{2}$ inches in breadth between the tips of the laminæ at its widest part.

The lumbar spine has a considerable concavity forwards.

The kidney presents the horseshoe-shaped malformation, the two parts being inseparably united in the middle line below.

The right half measures 2 inches in length by $1\frac{1}{4}$ inches in breadth, and $\frac{7}{8}$ inch in thickness. It is distinctly lobulated, and the ureter passes in front of its lower extremity to end normally in the bladder.

The left kidney is converted into a single oval cyst, having an extreme length of $2\frac{1}{4}$ inches. Below the point at which the inner surface of the cyst is connected with the right kidney, it narrows into a tailed lower extremity from which the ureter passes. The latter is small but pervious throughout. The left suprarenal body surmounting the cystic left kidney is normal; the right has been removed. The intestines and other viscera were normal.

The association of the two malformations is of interest. Parts which in the normal process of development should have united *dorsally* have failed to do so, whilst, on the other hand, parts which should have remained distinct have united *ventrally*. Considering the close connection of those parts of the mesoblast from which the vertebræ and the kidneys are respectively developed, it would appear probable that one general disturbance in this neighbourhood has accounted for both malformations.

Our knowledge as to the true nature of congenital cystic degeneration of the kidney is uncertain. The association of it with the

Digitized by Google

other malformation would perhaps rather suggest its origin in some early error or arrest of development, than as the result of pathological changes occurring in the later stages.

May 5th, 1891.

---

18. *Cured spina bifida.* (*Card specimen.*)

By G. H. Makins.

The specimen was removed by excision from the sacral region of a child, aged 17 months, at the Evelina Hospital for Sick Children. At birth the tumour was filled with fluid, but repeated injections with Morton's fluid caused almost complete solidification. On admission the tumour was of the size of a tangerine orange, connected by a pedicle, five inches in circumference, with the back of the sacrum, the first sacral spine being distinctly palpable above it. Only one small spot at its summit was still fluctuating, and this was not rendered appreciably tense on coughing or when the child cried. There were no nervous symptoms.

It was excised by means of two lateral elliptical incisions, a small quantity of cerebro-spinal fluid escaping on division of the pedicle. The skin flaps were then sutured. The wound did not heal by primary union, and unfortunately the child contracted diphtheria of the fauces ten days after the operation and died.

The tumour is covered with skin, which at the circumferential portion bears numerous hairs. At the central portion the skin is thin and cicatricial, and hairs are absent. During life this part was bluish in colour, and did not differ in appearance from ordinary cicatricial skin covering a chronically inflamed area.

On section the whole tumour consists of soft œdematous fibrous tissue, crossed in places by a few bands of denser structure. A small opening exists in the centre posteriorly, which probably communicated with the subarachnoid space. At the most prominent portion a cystic cavity, the size of a small nut, still exists

February 17th, 1891.

Digitized by Google

19. *Webbed fingers and toes.* (*Card specimen.*)

By H. Betham Robinson.

The hand and foot exhibited were taken from a female child who died fourteen days after birth. Both hands and feet showed complete webbing of the digits, which was unattended by any fusion of phalanges. No other malformation was present. The child was the first offspring of a father similarly deformed. The defect did not extend back more than the one generation.

---

20. *Hodgkin's disease, with lardaceous kidneys and an unusually large spleen.* (*Card specimen.*)

By W. Hale White.

Chas. T—, aged 25, first came under observation May, 1890. There was then an enlarged gland above Poupart's ligament on the right side. The spleen was down to the umbilicus, and the liver was one inch below the ribs. The blood showed 80 per cent. red corpuscles, 45 per cent. hæmoglobin, and one white corpuscle to fifty red. He frequently had a high temperature, usually about 101° or 102° in the evening. The urine was normal. He improved and went out in September, 1890.

He was re-admitted March 9th, 1891. The abdomen was full of fluid; six pints of opalescent fluid were withdrawn. The legs were œdematous, especially the left; the right arm is very œdematous. The spleen and liver are about as before. The blood shows hæmoglobin 50 per cent., red corpuscles 75 per cent., one white corpuscle to 150 red. The lymphatic glands in the neck are slightly enlarged. The urine was highly albuminous. He gradually sank and died.

Autopsy.—Lymphatic glands: Retro-peritoneal enormously enlarged. One gland in the pelvis, just above the right Poupart's

Digitized by Google

ligament, was also enlarged, being 2 inches in diameter. It showed in its interior some hæmorrhages which had formed cysts the size of peas. In it, and also in some other lymphatic glands, there were several spots of caseation. The glands in the neck were considerably enlarged on both sides; on the left they pressed on the left subclavian vein, causing thrombosis; the axillary and inguinal glands were slightly enlarged, and the left femoral vein was pressed upon by a gland. The spleen weighed 46 oz. It contained four or five infarcts, the largest about an inch or rather less in length. It and the liver presented the typical appearances of Hodgkin's disease. The kidneys were very pale and contained infarcts. The lungs were studded with minute masses of lymphoid growth, looking like miliary tubercles. The stomach contained several large deep hæmorrhagic ulcers along its upper curvature near the pylorus. The tonsils were normal. The medulla of the bones (femur and tibia) showed several pale whitish-yellow patches, about the size of a threepenny-piece, contrasting strongly with the red colour of the normal marrow. Microscopical sections by Dr. Perry showed typical lardaceous change in the glomeruli of the kidney. There were also in the liver a few hepatic cells, which gave the lardaceous reaction. In all the organs the lymphoid tissue was in places undergoing caseation. *April 7th*, 1891.

Digitized by Google

XII. DISEASES, ETC., OF THE LOWER ANIMALS.

1. *Bony plates in dura mater pressing on the spinal cord, and causing paraplegia in a dog.* (*From the Brown Institution.*) (*Card specimen.*)

By W. G. Spencer.

The specimens were taken from a large St. Bernard bitch, aged 3 years. For two years there had been slight weakness of the hind legs, which had become more marked during the last six months.

At the Institution the animal could progress only by dragging its hind limbs; when the hind quarters were raised to a standing position the hind limbs were just able to support the body, but they could not move.

There were excoriations on the dorsal surfaces of the hind paws from the dragging, but there was no tendency to ulceration on the plantar surfaces.

The patella tendon reflexes were excessive, but there was no clonus or rigidity. Sensation, both superficial and deep, was diminished but not absent. The urine and fæces passed involuntarily. The animal was killed.

Between the layers of the dura mater, covering the lower end of the spinal cord, are to be seen and felt thin, long plates, about 1 to 2 cm. long, 2 to 4 mm. broad, and about 0·5 mm. thick. They are situated especially at the lateral aspects of the cord, and above the point where these plates are to be found there are small nodules in the dura, also at the lateral aspects. At some points the cord has been pressed upon, and where this is the case the pia mater and part of the structure of the spinal cord are seen, in microscopic section, to have been replaced by small round cells and newly-formed fibrous tissue.

Digitized by Google

The bladder is seen to have been inflamed and thickened. The urine was alkaline, and contained blood, pus, and triple phosphate crystals. The kidneys were normal. On the mitral valve of the heart are a few small nodules due to endocarditis.

It is worthy of note that these changes took place in a young adult animal.

A drawing of the spinal cord, twice the natural size, seen in section where pressed upon is added. *December 2nd*, 1890.

---

2. *Filariæ in a dog's heart.* (*Card specimen.*)

By E. C. Perry.

The heart and a portion of the left lung of a dog. The superior and inferior vena cava, the right auricle and ventricle, and the pulmonary artery, with its larger branches, are filled with filariæ. There are none on the left side of the heart. Mr. H. J. Campbell informs me that the parasite is the *Filaria immitis* described by Welch in the 'Monthly Microscopical Journal' of 1873 (p. 157).

The specimen was sent from the Fiji Islands by Mr. C. Daniels. He states that in addition to the situations above mentioned, he has found a filaria in the thoracic duct. "The symptoms are for a long time only a cough, rather like that in aneurysm; but for about a week before death languor, listlessness, and general exhaustion. The dogs never get œdema or any signs of back pressure. Cardiac murmurs only late in the disease; systolic at apex, and diastolic or double at base; no præsystolic." He adds that the disease is common in the tropics, China, and India.[1]

December 3rd, 1890.

[1] A similar specimen is described by Mr. Shattock in the thirty-third volume of the Society's 'Transactions,' p. 434.

Digitized by Google

3. *Lympho-sarcoma surrounding the abdominal aorta, narrowing it near its termination, and completely obstructing the iliacs, in a dog.* (*From the Brown Institution.*) (*Card specimen.*)

By W. G. Spencer.

An Irish retriever dog, aged 2½, was sent to the Brown Institution for examination, but there is no history of the disease. The tumour surrounds the abdominal aorta and extends into the mesentery. The hinder part of the aorta for about 8 cm. is narrowed in passing through the middle of the mass, and the common iliacs are reduced in diameter to that of the finest bristle. At about 1 cm. from their origin the iliacs are obstructed by a thrombus, and they cannot be traced further in the tumour.

Microscopically, the growth is a small round-cell sarcoma, and no doubt began in the lymphatic glands in front of the vertebræ.

January 6th, 1891.

---

4. *Sarcoma surrounding the trachea and the aorta in a dog.* (*From the Brown Institution.*) (*Card specimen.*)

By W. G. Spencer.

A dog, aged 4 years, had been getting thinner for several weeks. The trachea and bronchi are surrounded by a new growth, which includes also the large vessels, the root of the heart, and the lungs. Secondary growths were found in the lungs, liver, kidneys, and lymphatic glands.

The aorta contains a clot, which is partly adherent and pale, elsewhere free and coloured. The clot extends from the left ventricle into the right brachiocephalic artery as far as its bifurcation. The clot has occluded to a large extent the right subclavian, into which it extends as far as the origin of the vertebral. The right carotid

Digitized by Google

is free, as also the left brachiocephalic. The structure of the growth is that of a small, round, and spindle-celled sarcoma, and it probably arose in connection with the bronchial lymphatic glands. *January 6th*, 1891.

---

5. *Rabbit's liver showing hypertrophic cirrhosis.* (*Card specimen.*)

By E. N. Nason, M.B.

The sections show considerable increase of new fibrous tissue, both inter- and intra-lobular. The new fibrous tissue seems to follow the course of the bile-ducts, which are apparently increased in number. The liver-cells themselves are in various stages of atrophy.

The rabbit was a tame one, kept with several others, and fed in the usual way. Deceived, no doubt, by the enlargement of the abdomen, the animal thought herself pregnant, and made a nest for her expected progeny later on; as she appeared to be in pain she was killed. The liver was then found to be much enlarged; the surface was irregular and of an ashy-grey colour. On section it was paler than natural. There was no biliary staining of the internal organs or of the conjunctivæ. No obstruction of the bile-duct was found. The other organs appeared to be healthy.

December 3rd, 1890.

---

6. *Leucocythæmia splenica. Cat.* (*From the Brown Institution.*) (*Card specimen.*)

By W. G. Spencer.

The animal, an adult male, was killed because it had become weak, and had an enlarged abdomen.

On opening the abdomen, the greatly enlarged spleen lay between

Digitized by Google

the abdominal wall and the intestines. There was no increase of peritoneal fluid; the liver was somewhat enlarged, but the lymphatic glands were normal.

The spleen is about 33 cm. in length. It weighed 352 grms., the liver 232 grms., whilst the weight of the whole cat was 3 kilos. 456 grms. The spleen, therefore, weighs more that one tenth of the whole animal. In the case of a normal cat which was weighed the spleen was only $\frac{1}{432}$ of the whole. The increased size of the spleen is partly due to blood.

The liver shows lymphatic cells between the cells of the liver, and in parts replacing them.

The blood shows an increase of white blood-corpuscles.

January 6th, 1891.

---

7. *Pyosalpinx. Distension of both uterine cornua with pus from a dog which had purulent vaginitis.* (*From the Brown Institution.*) (*Card specimen.*)

By W. G. Spencer.

The animal died soon after admission. There was no peritonitis or other disease than that of the uterus and vagina.

Both uterine cornua were distended with pus so as to be about 3 cm. in diameter, and the wall 2 to 3 mm. in thickness. The cornua no longer communicated with the body of the uterus and vagina, for when pressure was made on the distended cornua no pus escaped, either into the uterine cavity or from the fimbriated extremities, which had also become closed by inflammation. The pus had not a foul smell. The vagina contained pus, and its mucous membrane was slightly inflamed. The uterus and cornua with the vagina are exhibited, as well as the normal ovaries, kidneys, and bladder.

A microscopical section of the wall of the distended cornu shows that inflammation and suppuration have affected the mucous and submucous layers. In some parts remains of the follicles lined with epithelium are to be seen; in others these structures have disappeared. There is no evidence of tubercle.

Digitized by Google

The suppuration in the cornua has, doubtless, extended from the vagina, and then the communication with the uterine cavity has been shut off. *December 2nd*, 1890.

---

8. *Hæmatosalpinx and hæmatometra. Distension of the uterus and both cornua with menstrual fluid in an aged dog, due to obstruction by a cervical polypus.* (*From the Brown Institution.*) (*Card specimen.*)

By W. G. Spencer.

The specimen was taken from a large St. Bernard, aged 13 years. It had had three litters of puppies, the last about eight years ago. After ailing for some time it died unexpectedly.

No peritonitis was found, nor other disease than is shown in the specimen.

The uterus and cornua have been distended so as to be from 3 to 4 cm. in diameter. The cornua have also been greatly elongated, measuring 81 cm. from one extremity to the other. The fluid contained measured 12 ozs. Both cornua communicated widely with the body of the uterus, but no fluid escaped by the cervical canal into the vagina when pressure was made on the distended uterus and cornua. The fimbriated extremities have also been closed by inflammation.

The upper part of the cervical canal is seen to have been obstructed by a soft sessile polypus, 5 mm. in diameter, apparently growing from the mucous membrane. The vagina is normal, and the lower half of the canal of the cervix uteri patent. A bristle passed up before the canal was laid open was arrested by the polypus.

A microscopical examination of the wall of the cornua shows that the mucous and submucous layers have been wholly replaced by inflammatory cells; only a few of the follicles remain with their epithelial lining persistent.

The fluid (shown in a bottle) is viscid, about the consistency of

Digitized by Google

treacle, dark red in colour, and had a sickly odour. No putrefaction had taken place, and this has been prevented, since its exposure, by the addition of thymol; under the microscope it is seen to consist of *débris* and fat globules, with only a very few partly broken-down white cells. The cervical canal must have become blocked after the last parturition, and the polypus was most probably caused by inflammation. *December 2nd*, 1890.

---

9. *Eyes of an adult cat, showing the results of purulent keratitis and conjunctivitis.* (*From the Brown Institution.*) (*Card specimen.*

By W. G. Spencer.

During life the eyelids were much swollen, and fungating granulations protruded between their margins, from which pus was being discharged. No other disease beyond that of the eyes was found. The eyes are shown divided by median section after hardening.

Fig. 23.

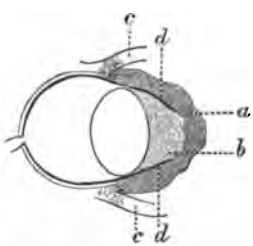

A vertical antero-posterior section of the cat's eye described, showing the results of purulent keratitis and conjunctivitis. *a.* Granulation tissue replacing ocular conjunctiva and cornea. *b.* Pus filling anterior chamber and pushing forwards the iris. *c.* Eyelids thickened. *d.* Iris. (Nat. size.)

The cornea and ocular conjunctiva are seen to have become changed into a layer of soft tissue, 2 to 3 mm. thick antero-posteriorly. The iris is pushed forwards and the anterior chamber

Digitized by Google

distended with pus. The lens and the rest of the eyeball are unaltered. The disease has been symmetrical. Under the microscope the laminæ of the cornea are seen to be separated by small round cells and vessels filled with blood. At some points the epithelium has not been detached by ulceration, but still covers the infiltrated cornea. The presence of epithelium on the free surface shows that there has been infiltration of the cornea, and not a growth of granulations over the surface from the conjunctiva. The changes are the result of purulent keratitis and conjunctivitis, which have extended to the anterior chamber, and would shortly have produced suppuration of the eyeball. The owner supposed that something had been thrown in, and the disease may well have been traumatic in origin, septic material being inoculated at the time or subsequently. But it is more likely that the purulent keratitis and conjunctivitis was a sequela to distemper. *December 2nd*, 1890.

---

10. *Cervical teeth.*

By J. Bland Sutton.

Dr. Evan Jones, of Aberdare, was good enough to send me the remarkable cervical auricle from a sheep, figured below. The natural pinna and external auditory meatus were well formed, but a few millimetres behind the normal meatus there was a persistent second branchial fistula, surmounted by a conspicuous cervical auricle. The posterior surface of this auricle is concave, and beset with numerous long processes resembling the buccal papillæ found on the inner surface of the lips of sheep. Strangest of all, is the presence of an incisor, of bad shape, mounted on a pedicle of bone; its base is surrounded with tissue resembling mucous membrane. When the parts are in position the tooth is hidden by the accessory auricle.

This specimen in itself would be of little value, and would merely excite curiosity; but it is not an isolated specimen. A few months before his death, Principal Robertson gave me a tooth which he removed from a cyst in the neck of a horse immediately below the auricle, the situation corresponding to that

Digitized by Google

FIG. 24.

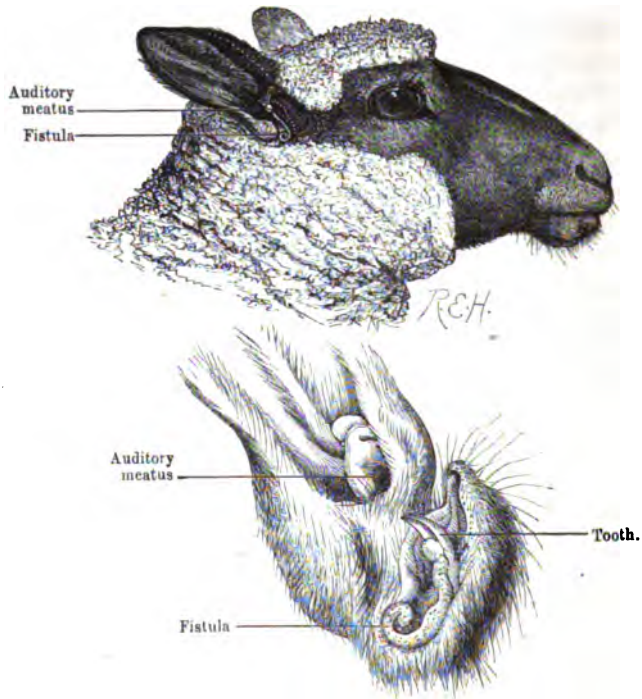

The head of a sheep with cervical auricle, and tooth surmounting a persistent branchial cleft. The lower figure represents the parts sketched separately.

FIG. 25.

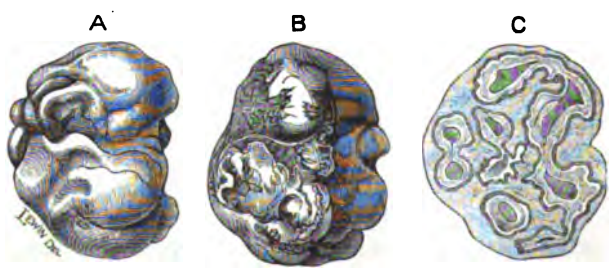

A tooth removed from the petrosal of a horse. A. Its crown. B. Its base. C. The tooth in section.

Digitized by Google

occupied by the tooth in the sheep's neck. The horse had a troublesome sinus communicating with a cyst, and on exploring the sinus the tooth shown in fig. 25 was removed.

This tooth at once recalled to my mind some specimens of teeth connected with the petrosal bone of oxen preserved in the museum of the Veterinary College, Alfort.[1]

There is, we may feel sure, some explanation for these strange appearances, but it will be hazardous to make a guess until more examples have been examined and described; but it may be here mentioned that similar teeth have been seen in man. A wax cast in the museum of the Odontological Society of Great Britain shows a tooth projecting from the skin of the neck, near the angle of the mandible.

The tooth was removed and the opening in the skin closed. This specimen has been described as a lower wisdom tooth, which has made its way to the surface and pierced the skin; but the evidence on which this opinion is based is not forthcoming.

It is much more reasonable to believe that it belongs to the same category as the incisor-shaped tooth in the sheep's neck, and that from the horse. It certainly agrees with them in this important particular, that the tooth is in the immediate neighbourhood of the external orifice of the second branchial cleft.

P.S.—Since this case was exhibited to the Society, Kostanecki has described a specimen identical with that in the sheep. See 'Virchow's Arch.,' Bd. cxxiii, S. 401. Gurlt figures a similar specimen in his 'Thierische Missgeburten,' Taf. xv, 1877.

February 17*th*, 1891.

---

11. *A harlequin calf.*

By J. Bland Sutton.

The skin of this calf has been preserved as a stuffed specimen in the museum of the Royal Veterinary College, London, since 1865. It was obtained by Mr. John Wallin (at that date a student of the College) from a heifer, a year and a half old, at Aldermaston,

[1] These are figured in Magitot's 'Anomalies Dentaire.'

Digitized by Google

Berks. The calf was alive when born, but died a few minutes afterwards.

The calf was described in the 'Veterinarian,' 1865, by Varnell as an example of elephantiasis. In his account of the calf, Varnell was unaware of any similar specimen having been recorded in this country, but he had been informed that Continental veterinary schools possessed one or two specimens. The first impression one gets on looking at this calf is that it is almost destitute of hair, except at the distal ends of the limbs. The greater part of the skin

FIG. 26.



A harlequin calf (Museum Royal Veterinary College, London).

of the head, trunk, and trunk-ends of the limbs is marked by deep furrows running mainly at right angles to the axis of the trunk; these are intersected irregularly by numerous shorter furrows, which help to produce a resemblance to a badly built brick wall. The ridges and furrows are fairly symmetrical on the two sides. In the furrows red hair exists; this seems to be absent in the thickened portion of the hide; but on microscopical examination these parts are found to contain hairs embedded in the hard tissue of which it is composed.

Although the skin of this calf has been preserved as a dried specimen for twenty-five years, I was able to obtain sections of the skin for microscopical purposes, which showed that the changes in

Digitized by Google

the skin are identical with those in harlequin fœtuses. These appearances suggest that the skin and hair were normally developed, and the hairs subsequently became matted together, and embedded in some soft material which was exuded in great abundance, and then, becoming hardened, subsequently cracked in different directions as the skin yielded to the force exerted upon it by the growing tissues beneath it.

In a short paper contributed in 1886 to the Medico-Chirurgical Society, and published in vol. lxix, 291, of the 'Transactions' of that Society, I attempted to identify this morbid material as the *Vernix caseosa.*

December 16th, 1890.

Digitized by Google

Digitized by Google

INDEX.

PAGE

ABRAHAM (P. S.), on a supposed case of indigenous leprosy (really carcinoma) 309
„ and E. CROOKSHANK, note on tubercular animals under treatment with tuberculin 343
ACROMEGALY (H. D. Rolleston for A. A. Kanthack) . . . 251
ADDISON'S DISEASE, pigmented small intestines, adrenals, and semilunar ganglia, from a case of (Card specimen). (Dr. Allchin) . . 302
ALLCHIN (Dr.), pigmented small intestines, adrenals, and semilunar ganglia, from a case of Addison's disease (Card specimen) . . . 302
ANÆMIA, blood-cast of the uterus in a case of (Card specimen). (Sheridan Delépine) 222
ANDERSON (WILLIAM), a case of fæcal fistula at the umbilicus with non-development of sigmoid flexure and rectum . . . 128
ANEURYSM of heart (J. A. Ormerod) 60
„ aortic, communicating with superior vena cava (W. M. Ord) . 71
„ — in a woman; rupture into left bronchus (Card specimen). (H. D. Rolleston) 76
„ — (abdominal) compressing common bile-duct and rupturing into duodenum (Card specimen). (W. Lee Dickinson) . . 77
„ of superior mesenteric artery; extravasation into mesentery; hæmorrhage into peritoneal cavity (Card specimen). (James Galloway) . 78
„ — (descending) rupturing into left bronchus (Card specimen). (W. Lee Dickinson) 77
ANEURYSMAL DILATATION of wall of left ventricle (Card specimen). (G. Gulliver) 60
ANEURYSMS above (and involving) the sinuses of Valsalva; death from rupture of one into the pericardium (Card specimen). (F. H. Hawkins) 74
ANKYLO-STOMIASIS, intestine and liver from a case of (Card specimen). (Beaven Rake) 135
ANTHRAX ŒDEMA of stomach (Card specimen) (G. Newton Pitt) . 108
AORTA, rupture of the heart and of the arch of (H. D. Rolleston) . 57
AORTIC ANEURYSM communicating with superior vena cava (William Miller Ord) 71
ARTERY, partial rupture of the right subclavian, with extensive separation of the internal and middle coats (A. A. Bowlby) . . . 79

Digitized by Google

PAGE

ASCITES, chylous (Sidney Martin) 93
„ — (Fred. J. Smith) 100
ATROPHY of heart (G. Gulliver) 58
„ of cerebral convolutions (J. A. Ormerod) . . . 13

BALLANCE (C. A.), osteoma of temporal bone . . . 296
„ and SAMUEL G. SHATTOCK, inoculation experiments with psorospermia 377
BARKER (ARTHUR E.), malignant polyp of the nose . . . 293
BATTLE (WILLIAM HENRY), epiphysitis (so-called) in infants . . 258
„ central sarcoma of femur (Card specimen) . . . 264
BEEVOR (HUGH R.) (communicated by Professor CROOKSHANK), note on media for the cultivation of the bacillus of tubercle . . 344
BERRY (JAMES), carcinoma following lupus of face (Card specimen) . 308
„ fifty loose bodies removed from a knee-joint . . . 275
„ femora three years after osteotomy 234
BIDWELL (LEONARD A.), fibroid polypus of the trachea . . 40
BILE-DUCT, duodenal pouching at the opening of the (H. D. Rolleston) . 183
„ gall-stone in ductus communis choledochus (Card specimen). (W. Joseph Tyson) 182
BILHARZIA HÆMATOBIA, bladder affected with (Card specimen). (Samuel G. Shattock) 196
„ with the urinary organs and lung containing ova (Anthony A. Bowlby) 194
BLADDER, case of tubercular ulceration of, treated by tuberculin (E. Hurry Fenwick) 189
„ affected with Bilharzia hæmatobia (Card specimen). (Samuel G. Shattock) 196
„ secondary melanotic sarcoma of (J. H. Targett) . . . 214
„ large hydatid cyst in the pelvis pressing upon the (E. Hurry Fenwick) 201
„ vesical calculi (Card specimen). (Raymond Johnson) . . 217
„ the soft parts and pelvis of a male adult who had extroversion of the (Edgar Willett) 215
„ myxo-sarcoma of prostate and (Card specimen). (W. D. Spanton) . 218
BLOOD-CAST of the uterus in a case of anæmia (Card specimen). (Sheridan Delépine) 222
BONE, calvaria showing irregular absorption of, from a case of congenital syphilis (J. F. Payne) 252
„ caries of the scapula (Card specimen). (L. A. Dunn) . . 257
„ central sarcoma of femur (Card specimen). (W. H. Battle) . 264
„ Charcot's disease of both knee-joints (Card specimen). (J. H. Targett) 269
„ columnar carcinomä of humerus secondary to tumour of upper part of rectum (Bernard Pitts) 267
„ glandular carcinoma of upper jaw (H. Betham Robinson) . . 265
„ osteitis deformans (Joseph Griffiths) 249
„ ossifying epulis of lower jaw (Card specimen). (L. A. Dunn) . 263
„ osteoma of temporal (C. A. Ballance) 296
„ osteitis deformans in a single (H. H. Clutton) . . . 246
„ patella with (dislocated internal semilunar ?) cartilage fixed to it (H. D. Rolleston) 271
„ symmetrical periostitis of femur, with an unusual formation of new (Anthony A. Bowlby) 243
BONY PLATES in dura mater, pressing on the spinal cord and causing paraplegia in a dog (Card specimen). (W. G. Spencer) . . 470

Digitized by Google

PAGE

BOWLBY (ANTHONY A.), partial rupture of the right subclavian artery, with extensive separation of the internal and middle coats . . 79
„ papillomatous growth, containing the ova of the *Bilharzia hæmatobia*, removed from the rectum 136
„ specimens of the *Distoma hæmatobium* (*Bilharzia hæmatobia*), with the urinary organs and lung containing ova . . . 194
„ symmetrical periostitis of femur, with an unusual formation of new bone 243
BRAIN, local atrophy of cerebral convolutions (J. A. Ormerod) . . 13
„ indefinite tumour of (Samuel West) 460
„ extensive chronic gummatous pachymeningitis of five years' duration (G. Newton Pitt for R. Cuff) 4
„ thrombosis of cerebral veins (William Collier) . . . 12
BREAST, cystic disease of, in young women (H. Betham Robinson) . 226
BRONCHIECTASIS, gangrene of lung secondary to (G. Newton Pitt) . 46
BRONCHITIS, case of plastic (Samuel West) . . . 43
BRONCHUS, rupture of right (Card specimen). (H. D. Rolleston) . 42
BURD (E. LYCETT), (1) primary carcinoma of lung; (2) mediastinal glands from same case 55

CAHILL (JOHN), a tumour involving trachea and œsophagus in the neck . 91
CALCULI, vesical (Card specimen). (Raymond Johnson) . . 217
„ numerous prostatic (Card specimen). (Sheridan Delépine) . . 219
CALCULUS, nasal (Card specimen). (Raymond Johnson) . . 296
CALVARIA in infants, two specimens of extreme thickening of (Samuel G. Shattock 235
„ showing irregular absorption of bone from a case of congenital syphilis (J. F. Payne) 252
CALF, a harlequin (J. Bland Sutton) 479
CAMPBELL (C. M.) and TURNER (WILLIAM ALDREN), heterotopia of the grey matter of the spinal cord 20
CANCER, on the non-contagiousness of (Walter K. Sibley) . . 381
CARCINOMA, columnar-celled, involving the lower jaw (H. Betham Robinson) 317
„ columnar, of humerus secondary to tumour of upper part of rectum (Bernard Pitts) 267
„ "On a supposed case of indigenous leprosy," really (P. S. Abraham) . 309
„ intra-cystic, of pectoral region (Card specimen). (Edgar Willett) . 319
„ following lupus of face (Card specimen). (James Berry) . . 308
„ mediastinal, secondary to scirrhus of the pancreas (Card specimen). (H. D. Rolleston) 320
„ primary, of lung, (2) Mediastinal glands from same case (E. Lycett Burd) 55
„ of scalp (S. Paget) 306
„ simulating scirrhus (H. Betham Robinson) . . . 229
CARIES of the scapula (Card specimen). (L. A. Dunn) . . 257
CASEOUS GLAND opening into the œsophagus (A. F. Voelcker) . 87
CERVICAL TEETH (J. Bland Sutton) 477
CHARCOT'S CRYSTALS in fæces (Card specimen). (Sheridan Delépine) . 459

Digitized by Google

CHARCOT'S CRYSTALS (*continued*)— PAGE
„ — in sputum containing a croupous cast (Card specimen). (Sheridan Delépine) 458
„ — in an alcoholic extract of a liver in a state of acute atrophy (yellow and red (Card specimen). (Sheridan Delépine) . . . 458
„ disease of both knee-joints (Card specimen). (J. H. Targett) . 269
CHAVASSE (THOMAS F.), on a case of pressure diverticulum of the œsophagus 82
CIRRHOSIS of pancreas in diabetes (Card specimen). (W. B. Hadden) . 184
„ rabbit's liver showing hypertrophic (Card specimen). (E. N. Nason) . 473
CLARKE (W. BRUCE), a piece of the patella cartilage knocked off and forming a loose body in the knee-joint 273
CLUTTON (H. H.), osteitis deformans in a single bone . . . 246
„ rodent ulcer of scalp (Card specimen) 304
COLITIS, ulcerative (Seymour J. Sharkey) 109
„ ulcerative (Card specimen). (H. Betham Robinson) . . 115
COLLIER (WILLIAM), thrombosis of cerebral veins . . . 12
COLON, new growth in liver secondary to carcinoma of descending (Norman Moore) 172
„ pigmented black throughout with lead (G. Newton Pitt) . . 109
CONJUNCTIVITIS, eyes of an adult cat showing the results of purulent keratitis and (Card specimen). (W. G. Spencer) . . 476
CONTRACTION of the stomach from chronic inflammation (Card specimen). (Lauriston Shaw) 104
COPEMAN (S. MONCKTON), hæmatoporphyrin in the urine . . 364
CROOKSHANK (EDGAR M.), on the morphology, cultivation, and toxic products of the tubercle bacillus 330
„ and ABRAHAM (P. S.), note on tubercular animals under treatment with tuberculin 343
CROUPOUS CAST, Charcot's crystals in sputum, containing a (Card specimen) 458
CUFF (R.), extensive chronic gummatous pachymeningitis of five years' duration 4
CYSTIC CHONDRO-ADENOMA of testis (Card specimen). (H. Betham Robinson) 220
„ dilatation of the vasa differentia (Card specimen). (J. H. Targett) . 221
„ disease of breast in young women (H. Betham Robinson) . . 226
„ intra-carcinoma of pectoral region (Card specimen). (Edgar Willett) 319
CYST of finger, two cases of dermal (E. C. Stabb) . . . 314
„ hydatid, in the pelvis pressing upon the bladder and causing obstructive suppression of urine (E. Hurry Fenwick) . . . 201
DELÉPINE (SHERIDAN), blood-cast of the uterus in a case of anæmia (Card specimen) 222
„ Charcot's crystals in fæces (Card specimen) . . . 459
„ — — in sputum containing a croupous cast (Card specimen) . 458
„ — — in an alcoholic extract of a liver in a state of acute atrophy (yellow and red) (Card specimen) 458
„ cultivation of psorospermia (a preliminary communication) . . 371
„ ileo-cæcal intussusception with involvement of the duodenum; passage of the cæcum and vermiform appendix from the right into the left iliac region (Card specimen) 124
„ melano-mycosis of the skin 423

Digitized by Google

DELEPINE (SHERIDAN) (*continued*)— PAGE
„ necrosed pulmonary tissue and exudation becoming tubercular (Card specimen) 50
„ a case of primary melanotic sarcoma of the liver . . . 161
„ prostatitis and peripprostatic abscess; cystic dilatation of prostatic glands; numerous prostatic calculi (Card specimen) . . 219
„ and SISLEY (RICHARD), extensive gummatous lesions of the liver, diaphragm, lung, and spleen 141

DERMAL CYST of finger (E. C. Stabb) 314

DEWSNAP (Dr.), extensive necrosis of the vertex (with drawing of the skull) (Card specimen) 234

DIABETES, cirrhosis of pancreas in (Card specimen). (W. B. Hadden) . 184

DICKINSON (W. LEE), saccular aneurysm of descending aorta rupturing into left bronchus (Card specimen) 77
„ aneurysm of abdominal aorta compressing common bile-duct and rupturing into duodenum (Card specimen) 77

DIPHTHERIA, micro-organism of (Albert Wilson) . . . 346
„ *résumé* of objections to Klein's Bacillus Diphtheriæ . . 348

DISEASES, &c., of the lower animals . . . 470—481
„ — of the organs of circulation . . . . 57—81
„ — of the genito-urinary organs . . . 185—231
„ — of the ductless glands . . . . 298—303
„ — of the organs of digestion . . . . 82—184
„ — of the nervous system . . . . 1—34
„ — of the organs of respiration . . . 35—56
„ — of the organs of special sense . . . 293—297
„ — of the skin . . . . . 304—313
„ — of the organs of motion . . . . 232—292

DISTOMA HÆMATOBIUM (*Bilharzia hæmatobia*) with the urinary organs and lung containing ova (Anthony A. Bowlby) . . . 194

DIVERTICULUM of the œsophagus (Thomas F. Chavasse) . . 82

DORAN (ALBAN), hydronephrosis of right kidney, removed by nephrectomy; aberrant renal artery (Card specimen) 185

DUNN (L. A.), caries of the scapula (Card specimen) . . . 257
„ ossifying epulis of the lower jaw (Card specimen) . . . 263

DUODENAL POUCH (Card specimen). (H. D. Rolleston) . . 131
„ pouching at the opening of the bile-duct, due to ulceration (Card specimen). (H. D. Rolleston) 183

DUODENUM, perinephritic abscess opening into the duodenum (Card specimen). (H. D. Rolleston) 186

DURA MATER, bony plates in (Card specimen). (W. G. Spencer) . 470

EPIPHYSITIS (so-called) in infants (William Henry Battle) . . 258

EPITHELIOMATOUS TUMOUR occluding the œsophagus (Lauriston Shaw) 89

EXOPHTHALMIC GOITRE in a girl, causing death by asphyxia (W. G. Spencer) 299

EYES of an adult cat, showing the results of purulent keratitis and conjunctivitis (Card specimen). (W. G. Spencer) . . . 476

Digitized by Google

PAGE

FACE, sebaceous carcinoma of (H. Betham Robinson) . . . 315

FÆCES, Charcot's crystals in (Card specimen). Sheridan Delépine) . 459

FALLOPIAN TUBE, primary carcinoma of the right (Card specimen). (W. Essex Wynter) 222

FEMORA three years after osteotomy (James Berry) . . . 234

FEMUR, central sarcoma of (Card specimen). (W. H. Battle) . . 264

FENWICK (E. HURRY), a case of tubercular ulceration of the bladder, which was treated by means of a weak solution of tuberculin . 189

„ large hydatid cyst in the pelvis, pressing upon the bladder and causing obstructive suppression of urine 201

FIBROID POLYPUS of the trachea (Leonard A. Bidwell) . . 40

FILARIÆ in a dog's heart (Card specimen). (E. C. Perry) . . 471

FINGER, tuberculosis of (tendon-sheath, &c.) (E. C. Stabb) . . 464

„ two cases of dermal cyst of (E. C. Stabb) . . . 314

FINGERS AND TOES, webbed (Card specimen). (H. Betham Robinson) . 468

FISTULA, case of fæcal, at the umbilicus with non-development of sigmoid flexure and rectum (William Anderson) . . . 128

FORAMEN OVALE in an adult—Patent (W. B. Hadden) . . 65

FRACTURE of both first ribs (Card specimen) (H. D. Rolleston) . 232

„ of first rib (Card specimen). (H. D. Rolleston) . . . 232

FRACTURES of the first rib (Card specimen). (H. D. Rolleston) . 233

GALL-BLADDER, distension and commencing suppuration of (Card specimen). (W. Hale White) 181

„ ulceration of (Sydney Jones) 179

„ with internal ulceration (Norman Moore) . . . 178

GALLAWAY (JAMES), aneurysm of superior mesenteric artery; extravasation into mesentery; hæmorrhage into peritoneal cavity (Card specimen) 78

„ a case of syringomyelus 26

GALL-STONE in ductus communis choledochus (Card specimen). (W. J. Tyson) 182

GANGRENE of lung secondary to bronchiectasis (G. Newton Pitt) . 46

GASTROCNEMII MUSCLES, symmetrical hemiatrophy of (Card specimen). (J. H. Targett) 465

GENU RECURVATUM in a fœtus at term (Card specimen). (Samuel G. Shattock) 280

GLANDULAR CARCINOMA of upper jaw (H. Betham Robinson) . 265

GOITRE, exophthalmic, in a girl, causing death by asphyxia (W. G. Spencer) 299

„ substernal, arising in an accessory thyroid (Bernard Pitts) . . 301

GOLDING-BIRD (C. H.) and PITT (G. NEWTON), extreme cicatrisation and contraction of the stomach, due to a corrosive poison taken three months previously 105

GRIFFITHS (JOSEPH), osteitis deformans 249

GULLIVER (G.), aneurysmal dilatation of wall of left ventricle (Card specimen) 60

„ simple atrophy of heart 58

GUMMA of lung (H. D. Rolleston) 50

Digitized by Google

PAGE

GUMMATOUS disease of occipital lobe due to inherited syphilis; perforation of skull (J. Hutchinson, jun.) 254
„ infiltration of the muscular wall of the heart, leading to aneurysmal pouching and rupture (G. Newton Pitt) . . . 61
„ lesions of the liver, diaphragm, lung, and spleen (Sheridan Delépine and Richard Sisley) 141

HADDEN (W. B.), patent foramen ovale in an adult . . . 65
„ cirrhosis of pancreas in diabetes (Card specimen) . . . 184
„ malignant disease of the œsophagus communicating with trachea and aorta (Card specimen) 88
„ a case of extreme contraction of the stomach . . . 107
HÆMATOPORPHYRIN in the urine (S. Monckton Copeman) . . 364
HÆMATOSALPINX AND HÆMATOMETRA, distension of the uterus and both cornua with menstrual fluid in an aged dog, due to obstruction by a cervical polypus (Card specimen). (W. G. Spencer) . . 475
HARLEQUIN CALF (J. Bland Sutton) 479
HAWKINS (FRANCIS H.), aneurysms above and involving the sinuses of Valsalva; death from rupture of one into the pericardium (Card specimen) 74
„ obstruction at the ileo-cæcal valve caused by a carcinomatous tumour growing from the ileo-cæcal valve (Card specimen) . . 132
HEART, aneurysm of (J. A. Ormerod) 60
„ aneurysmal dilatation of wall of left ventricle (Card Specimen). (G. Gulliver) 60
„ aneurysms above and involving the sinuses of Valsalva (Card specimen). (F. H. Hawkins) 74
„ atrophy of (G. Gulliver) 58
„ congenital, communicating between the ventricles of (Card specimen). (H. D. Rolleston) 65
„ gummatous infiltration of the muscular wall of (G. Newton Pitt) . 61
„ with bifid apex (Card specimen). (Samuel G. Shattock) . . 67
„ myocarditis limited to the right side of (H. D. Rolleston) . . 63
„ rupture of, and of the arch of the aorta (H. D. Rolleston) . . 57
„ tricuspid stenosis (Sheridan Delépine) 59
HETEROTOPIA of the grey matter of the spinal cord (C. M. Campbell and W. A. Turner) 20
„ — of the grey matter of the spinal cord (Howard H. Tooth) . 14
HODGKIN'S DISEASE, with lardaceous kidneys and an unusually large spleen (Card specimen). (W. Hale White) . . . 468
HUMERUS, columnar carcinoma of, secondary to tumour of upper part of rectum (Bernard Pitts) 267
HUTCHINSON (J., jun.), gummatous disease of occipital lobe due to inherited syphilis; perforation of skull 254
HYDATID CYST between bladder and rectum; retention of urine; surgical kidneys; death (John R. Lunn) 198
„ in the pelvis (E. Hurry Fenwick) 201
HYDATIDS, liver containing two (Samuel West) . . . 175
HYDROCEPHALUS, external (S. W. Wheaton) . . . 1
HYDRONEPHROSIS of right kidney, removed by nephrectomy; aberrant renal artery (Card specimen). (Alban Doran) . . . 185
HYDROTHORAX, chylous (Sidney Martin) 93

Digitized by Google

PAGE

ILEO-CÆCAL INTUSSUSCEPTION with involvement of the duodenum; passage of the cæcum and vermiform appendix from the right into the left iliac region (Card specimen). (Sheridan Delépine) . . 124
„ valve, obstruction at (Francis H. Hawkins) . . . 132

INTESTINAL OBSTRUCTION, chronic, from stricture of the ileum, secondary to ulceration produced by strangulation of the bowel in a femoral hernia; death from perforation (G. Newton Pitt) . . 119

INTESTINE, perforation of small (Bernard Pitts) . . . 125
„ and liver from a case of ankylo-stomiasis (Card specimen). (Beaven Rake) 135

INTRA-CYSTIC CARCINOMA of pectoral region (Card specimen). (Edgar Willett) 319

INTUSSUSCEPTION, ileo-cæcal (Card specimen). (Sheridan Delépine) . 124

INOCULATION EXPERIMENTS with psorospermia (Samuel G. Shattock and Charles A. Ballance) 377

JAW, columnar-celled carcinoma involving the lower (H. Betham Robinson) 317
„ glandular carcinoma of upper (H. Betham Robinson) . . 265
„ ossifying epulis of lower (Card specimen). (L. A. Dunn) . . 268
JEJUNUM, stricture of (Card specimen). (H. D. Rolleston) . . 122
JOHNSON (RAYMOND), nasal calculus (Card specimen) . . . 296
„ spina bifida associated with cystic horse-shoe kidney (Card specimen) . 466
„ vesical calculi (Card specimen) 217
JONES (Sydney), ulceration of gall-bladder 179

KANTHACK (A. A.), acromegaly 251
KERATITIS, eyes of an adult cat, showing the results of purulent (Card specimen). (W. G. Spencer) 476
KIDNEY, hydronephrosis of right (Alban Doran) . . . 185
„ perinephritic abscess opening into the duodenum (Card specimen). (H. D. Rolleston) 186
„ spina bifida associated with cystic horse-shoe (Card specimen). (Raymond Johnson) 466
„ tumour of right, weighing 4½ lbs.; hæmaturia; death. (John R. Lunn) 186
KIDNEYS, Hodgkin's disease with lardaceous (W. Hale White) . 468
„ surgical (John R. Lunn) 198
KLEIN'S BACILLUS DIPHTHERIÆ, *resumé* of, objections to . . 348
KNEE. Genu recurvatum in a fœtus at term (Card specimen). (Samuel G. Shattock) 280
KNEE-JOINT, a piece of the patella cartilage knocked off and forming a loose body in the (W. Bruce Clarke) 273
„ loose bodies from a tubercular (Howard Marsh) . . . 276
„ two loose bodies removed from a (Edgar Willett) . . . 274
„ fifty loose bodies removed from a (James Berry) . . . 275
KNEE-JOINTS, Charcot's disease of both (Card specimen). (J. H. Targett) 269

LARYNX, leprosy of (Beaven Rake) 37
„ tumour of (Felix Semon and Samuel G. Shattock) . . 37

Digitized by Google

PAGE

LEPROSY of larynx necessitating tracheotomy (Beaven Rake) . . 37
„ on a supposed case of indigenous (really carcinoma) (P. S. Abraham) . 309

LEUCOCYTHÆMIA SPLENICA. Cat (Card specimen). (W. G. Spencer) 473

LIPOMA of liver (? appendix epiploica) (H. D. Rolleston) . . 160
„ of spermatic cord with hernial sac (E. W. Roughton) . . 130

LIVER, lipoma of (? appendix epiploica) (H. D. Rolleston) . . 160
„ new growth in (Norman Moore) 172
„ pigmented growth of (apparently primary sarcoma) (Card specimen) (F. G. Penrose) 172
„ case of primary melanotic sarcoma of (Sheridan Delépine) . . 161
„ Charcot's crystals in an alcoholic extract of a, in a state of acute atrophy (yellow and red) (Card specimen). (Sheridan Delépine). . 458
„ containing two hydatids, the sacs communicating, but not the cysts; paracentesis three times, 90 oz.; free incision; death from exhaustion (Samuel West) 175
„ rupture of, partial repair (Card specimen). (H. D. Rolleston) . 138

LOOSE BODIES (50) removed from a knee-joint (James Berry) . . 275
„ from a tubercular knee-joint (Howard Marsh) 276

LOOSE BODY in peritoneal cavity (Card specimen). (H. D. Rolleston) . 103

LUNG, gangrene of (G. Newton Pitt) 46
„ gumma of (H. D. Rolleston) 50

LUNN (JOHN R.), hydatid cyst between bladder and rectum; retention of urine; surgical kidneys; death 198
„ tumour of right kidney, weighing 4½ lbs.; hæmaturia; death . 186

LUNG, myxo-sarcoma of (H. D. Rolleston) 54
„ primary carcinoma of. (2) Mediastinal glands from same case (E. Lycett Burd) 55
„ tuberculosis of (A. F. Voelcker) 46

LUNGS, diffuse syphilitic fibrosis of (E. C. Perry) . . . 53

LUPUS of face, carcinoma following (Card specimen). (James Berry) . 308

LYMPHO-SARCOMA surrounding the abdominal aorta, narrowing it near its termination, and completely obstructing the iliacs in a dog (Card specimen). (W. G. Spencer) 472

MACKENZIE (JOHN CUMMING) (communicated by G. SIMS WOODHEAD), melanotic sarcoma very widely disseminated 321

MAKINS (G. H.), cured spina bifida (Card specimen) 467

MALIGNANT DISEASE of the œsophagus communicating with trachea and aorta (Card specimen). (W. B. Hadden) 88
„ polyp of the nose (Arthur E. Barker) 293

MARSH (HOWARD), loose bodies from a tubercular knee-joint . . 276

MARTIN (SIDNEY), a case of chylous ascites and chylous hydrothorax, due to thrombosis and contraction of veins at the root of the neck on the left side 93

MEDIASTINAL CARCINOMA secondary to scirrhus of the pancreas (Card specimen). (H. D. Rolleston) 320

MELANO-MYCOSIS of the skin (Sheridan Delépine) 423

MELANOTIC SARCOMA, secondary, of the bladder (J. H. Targett) . 214
„ very widely disseminated (John Cumming Mackenzie, communicated by G. Sims Woodhead) 321

Digitized by Google

PAGE

MICRO-ORGANISM of diphtheria, with experimental results in animals (Albert Wilson) 346
MISCELLANEOUS COMMUNICATIONS . . . 330—469
MOORE (NORMAN), gall-bladder with internal ulceration . . 178
„ new growth in liver secondary to carcinoma of descending colon . 172
MORBID GROWTHS . . . . . 314—329
MORPHOLOGY, cultivation and toxic products of the tubercle bacillus (Edgar M. Crookshank) 330
MURRAY (H. MONTAGUE), ulceration just below right vocal cord, followed by subcutaneous emphysema 35
MYOCARDITIS limited to the right side of the heart (H. D. Rolleston) . 63
MYXO-SARCOMA of lung (H. D. Rolleston) . . . 54
„ of prostate and bladder (Card specimen). (W. D. Spanton) . . 218

NASAL CALCULUS (Card specimen). (Raymond Johnson) . . 296
NASON (E. N.), rabbit's liver showing hypertrophic cirrhosis (Card specimen) 473
NIPPLE, supernumerary median nipple and areola in a male (W. Roger Williams) 224
NOSE, malignant polyp of (Arthur E. Barker) . . . 293

OBSTRUCTION at the ileo-cæcal valve, caused by a carcinomatous tumour growing from the ileo-cæcal valve (Card specimen). (F. H. Hawkins) 132
ŒSOPHAGUS, a case of pressure diverticulum (Thomas F. Chavasse) . 82
„ caseous gland opening into the (A. F. Voelcker) . . . 87
„ epitheliomatous tumour occluding the (Lauriston Shaw) . . 89
„ in the neck (John Cahill) 91
„ malignant disease of (Card specimen). (W. B. Hadden) . . 88
„ sarcoma of (Lauriston Shaw) 90
ORD (WILLIAM MILLER), aortic aneurysm communicating with superior vena cava 71
ORMEROD (J. A.), aneurysm of heart 60
OSSIFYING EPULIS of lower jaw (Card specimen). (L. A. Dunn) . 263
OSTEITIS DEFORMANS in a single bone (H. H. Clutton) . . 246
„ (Joseph Griffiths) 249
OSTEOMA of temporal bone (C. A. Ballance) . . . 296

PAGET (STEPHEN), carcinoma of scalp 306
„ three cases of imperforate rectum 136
PANCREAS, cirrhosis of, in diabetes (Card specimen). (W. B. Hadden) . 184
„ mediastinal carcinoma secondary to scirrhus of the (Card specimen). (H. D. Rolleston) 320
PAPILLOMATOUS GROWTH, containing the ova of the *Bilharzia hæmatobia*, removed from the rectum (Anthony A. Bowlby) . . 136
PATELLA with. (dislocated internal semilunar?) cartilage fixed to it (H. D. Rolleston) 271
„ cartilage, piece of the, knocked off and forming a loose body in the knee-joint (W. Bruce Clarke) 273

Digitized by Google

PAGE

PATENT FORAMEN OVALE in an adult (W. B. Hadden) . . 65

PAYNE (J. F.), calvaria showing irregular absorption of bone from a case of congenital syphilis 252

PENROSE (F. G.), pigmented growth of liver (apparently primary sarcoma) (Card specimen) 172

PERFORATION of small intestine, caused by a collection of orange pips incarcerated in an inguinal hernia (Bernard Pitts) . . 125

PERINEPHRITIC ABSCESS opening into the duodenum (Card specimen). (H. D. Rolleston) 186

PERIOSTITIS of femur, symmetrical (Anthony A. Bowlby) . . 243

PERITYPHLITIS, pylephlebitis suppurativa consequent on (Samuel West) 138

PERRY (E. C.), diffuse syphilitic fibrosis of the lungs . . . 53
„ filariæ in a dog's heart (Card specimen) 471
„ tuberculosis of the pleura 55
„ — of the thyroid gland (Card specimen) . . . 298

PIGMENTED GROWTH of liver (apparently primary sarcoma) (Card specimen). (F. G. Penrose) 172
„ small intestines, adrenals, and semilunar ganglia, from a case of Addison's disease (Card specimen). (Dr. Allchin) . . 302

PITT (G. NEWTON), anthrax œdema of stomach (Card specimen) . 108
„ chronic intestinal obstruction from stricture of the ileum, secondary to ulceration produced by strangulation of the bowel in a femoral hernia; death from perforation 119
„ colon pigmented black throughout with lead . . . 109
„ gangrene of lung secondary to bronchiectasis . . . 46
„ gummatous infiltration of the muscular wall of the heart, leading to aneurysmal pouching and rupture 61
„ volvulus in a new-born infant; laparotomy . . . 123
„ and GOLDING-BIRD (C. H.), extreme cicatrisation and contraction of the stomach, due to a corrosive poison taken three months previously 105

PITTS (BERNARD), columnar carcinoma of humerus secondary to tumour of upper part of rectum 267
„ perforation of small intestine caused by a collection of orange pips incarcerated in an inguinal hernia 125
„ substernal goitre arising in an accessory thyroid . . . 301

PLASTIC BRONCHITIS, (Samuel West) 43

PLEURA, tuberculosis of (E. C. Perry) 55

POISON, cicatrisation and contraction of the stomach due to a corrosive (C. H. Golding-Bird and G. Newton Pitt) . . . 105

POLYPUS, obstruction by a cervical (Card specimen). (W. G. Spencer) . 475
„ of the trachea (Leonard A. Bidwell) 40

PORTAL FISSURE, tumour in (Samuel West) 155

PRIMARY CARCINOMA of the right Fallopian tube with large cyst in connection with the new growth (Card specimen). (W. Essex Wynter) 222

PROSTATE, myxo-sarcoma of (W. D. Spanton). (Card specimen) . 218

PROSTATITIS and periprostatic abscess; cystic dilatation of prostatic glands; nnmerous prostatic calculi (Card specimen). (Sheridan Delépine) 219

PSILOSIS or sprue (Frank J. Wethered) 116

Digitized by Google

PAGE

PSOROSPERMIA, cultivation of (a preliminary communication) (Sheridan Delépine) 371
„ inoculation experiments with (Samuel G. Shattock and Charles A. Ballance) 377
PULMONARY (necrosed) tissue and exudation becoming tubercular Card specimen). (Sheridan Delépine) 50
PYLEPHLEBITIS, suppurative, consequent on perityphlitis (Samuel West) 138
PYOSALPINX, distension of both uterine cornua with pus from a dog which had purulent vaginitis (Card specimen). (W. G. Spencer) . 474

RABBIT'S LIVER showing hypertrophic cirrhosis (Card specimen). (E. N. Nason) 473
RAKE (BEAVEN), extreme leprosy of larynx necessitating tracheotomy . 37
„ intestine and liver from a case of ankylo-stomiasis (Card specimen) . 135
RECTUM, papillomatous growth, removed from (Anthony A. Bowlby) . 136
„ three cases of imperforate (Stephen Paget) . . . 136
RESUMÉ of objections to Klein's bacillus diphtheriæ . . . 348
RIB, fracture of first (Card specimen). (H. D. Rolleston) . . 232
„ fractures of the first (Card specimen). (H. D. Rolleston) . . 233
RIBS, fracture of both first (Card specimen). (H. D. Rolleston) . 232
ROBINSON (H. BETHAM), columnar-celled carcinoma involving the lower jaw 317
„ cystic chondro-adenoma of testis (Card specimen) . . . 220
„ cystic disease of breast in young women 226
„ duct carcinoma simulating scirrhus 229
„ glandular carcinoma of the upper jaw 265
„ sebaceous carcinoma of face 315
„ ulcerative colitis (Card specimen) 115
„ webbed fingers and toes (Card specimen) . . . 468
RODENT ULCER of scalp (Card specimen). (H. H. Clutton) . . 304
ROLLESTON (H. D.), communication between the ventricles of the heart, congenital (Card specimen) 65
„ complete rupture of right bronchus (Card specimen) . . . 42
„ duodenal pouch (Card specimen) 131
„ — pouching at the opening of the bile-duct due to ulceration (Card specimen) 183
„ for Dr. DEWSNAP, extensive necrosis of the vertex (with drawing of the skull) (Card specimen) 234
„ fracture of both first ribs (Card specimen) . . . 232
„ — of first rib (Card specimen) 232
„ fractures of the first rib (Card specimen) . . . 233
„ gumma of lung 50
„ lipoma of liver (? appendix epiploica) 160
„ loose body in peritoneal cavity (Card specimen) . . . 103
„ mediastinal carcinoma secondary to scirrhus of the pancreas (Card specimen) 320
„ myocarditis limited to the right side of the heart . . . 63
„ myxo-sarcoma of lung 54
„ patella with (dislocated internal semilunar ?) cartilage fixed to it . 271
„ perinephritic abscess opening into the duodenum (Card specimen) . 186
„ rupture of liver; partial repair (Card specimen) . . . 138
„ — heart and of the arch of the aorta 57

Digitized by Google

ROLLESTON (H. D.) (*continued*)— PAGE
„ saccular aneurysm of aorta in a woman; rupture into left bronchus (Card specimen) 76
„ stricture of jejunum (Card specimen) 122
„ for KANTHACK (A. A.), acromegaly 251
ROUGHTON (E. W.), lipoma of spermatic cord with hernial sac . . 130
RUPTURE of liver; partial repair (Card specimen). (H. D. Rolleston) . 138
„ of right bronchus (H. D. Rolleston). (Card specimen) . . 42
„ of spleen (Edgar Willett) 183
„ of vermiform appendix (Arthur Voelcker) . . . 127

SACCULAR ANEURYSM of aorta in a woman; rupture into left bronchus (Card specimen). (H. D. Rolleston) 76
„ of descending aorta, rupturing into left bronchus (Card specimen). (W. Lee Dickinson) 77
SARCOMA, melanotic, very widely disseminated (J. C. Mackenzie, communicated by G. Sims Woodhead) 321
„ of lung, myxo- (H. D. Rolleston) 54
„ of the œsophagus perforating the trachea (Lauriston Shaw) . . 90
„ of femur (Card specimen). (W. H. Battle) . . . 264
„ secondary melanotic, of the bladder (J. H. Targett) . . 214
„ surrounding the trachea and the aorta in a dog (Card specimen). (W. G. Spencer) 472
„ primary melanotic, of liver (Sheridan Delépine) . . . 161
SCALP, carcinoma of (S. Paget) 306
„ rodent ulcer of (Card specimen). (H. H. Clutton) . . 304
SCAPULA, caries of the (Card specimen). (L. A. Dunn) . . 257
SCIRRHUS of the pancreas, mediastinal carcinoma secondary to (Card (specimen). (H. D. Rolleston) 320
„ duct carcinoma simulating (H. Betham Robinson) . . . 229
SEBACEOUS CARCINOMA of face (H. Betham Robinson) . . 315
SEMON (FELIX) and SHATTOCK (SAMUEL G.), anomalous tumour of the larynx 37
SHARKEY (SEYMOUR J.), ulcerative colitis 109
SHATTOCK (SAMUEL G.), a heart with bifid apex (Card specimen) . 67
„ and BALLANCE (CHARLES A.), inoculation experiments with psorospermia 377
„ and SEMON (FELIX), anomalous tumour of the larynx . . 37
„ bladder affected with *Bilharzia hæmatobia* (Card specimen) . . 196
„ genu recurvatum in a fœtus at term (Card specimen) . . 280
„ two specimens of extreme thickening of the calvaria in infants . 235
SHAW (LAURISTON), contraction of the stomach from chronic inflammation (Card specimen) 104
„ epitheliomatous tumour occluding the œsophagus . . . 89
„ sarcoma of the œsophagus perforating the trachea . . . 90
SIBLEY (WALTER K.), on the non-contagiousness of cancer . . 381
SISLEY (RICHARD), *see* DELÉPINE.
SKIN. Carcinoma following lupus of face (Card specimen). (James Berry) 308
„ carcinoma of scalp (S. Paget) 306
„ melano-mycosis of (Sheridan Delépine) 423
„ "On a supposed case of indigenous leprosy" (really carcinoma) (P. S. Abraham) 309
„ rodent ulcer of scalp (Card specimen) 304

Digitized by Google

PAGE

SKULL, perforation of (J. Hutchinson, jun.) 254

Smith (Fred. J.), a case of chylous ascites 100

Spanton (W. D., per J. H. Targett), myxo-sarcoma of prostate and bladder (Card specimen) 218

Spencer (W. G.), bony plates in dura mater, pressing on the spinal cord and causing paraplegia, in a dog (Card specimen) 470
„ exophthalmic goitre in a girl, causing death by asphyxia . . 299
„ eyes of an adult cat, showing the results of purulent keratitis and conjunctivitis (Card specimen) 476
„ hæmatosalpinx and hæmatometra; distension of the uterus and both cornea with menstrual fluid in an aged dog, due to obstruction by a cervical polypus (Card specimen) 475
„ leucocythæmia splenica; cat (Card specimen) 473
„ lympho-sarcoma surrounding the abdominal aorta, narrowing it near its termination, and completely obstructing the iliacs, in a dog (Card specimen) 472
„ pyosalpinx; distension of both uterine cornua with pus, from a dog which had purulent vaginitis (Card specimen). (W. G. Spencer) . 474
„ sarcoma surrounding the trachea and the aorta in a dog (Card specimen) 472

SPINA BIFIDA associated with cystic horseshoe kidney (Card specimen). (Raymond Johnson) 466
„ cured (Card specimen). (G. H. Makins). 467

SPINAL CORD, bony plates in dura mater pressing on the (Card specimen). (W. G. Spencer) 470
„ heterotopia of the grey matter of (C. M. Campbell and W. A. Turner) . 20
„ — (Howard H. Tooth) 14

SPLEEN, Hodgkins' disease, with lardaceous kidneys and an unusually large spleen (Card specimen). (W. Hale White) 468
— rupture of (Edgar Willett) 183

SPLENICA, leucocythæmia. Cat (Card specimen). (W. G. Spencer) . 473

SPRUE or psilosis (Frank J. Wethered) 116

SPUTUM, Charcot's crystals in (Card specimen). (Sheridan Delépine) . 458

Stabb (E. C.), tuberculosis of finger (tendon-sheath, &c.) . . 464
„ two cases of dermal cyst of finger 314

STENOSIS, tricuspid (Sheridan Délepine) 59

STOMACH, anthrax œdema of (Card specimen). (G. Newton Pitt) . 108
„ cicatrisation and contraction of (C. H. Golding-Bird and G. Newton Pitt) 105
„ contraction of, from chronic inflammation (Card specimen). (Lauriston Shaw) 104
„ extreme contraction of (W. B. Hadden) 107

STRICTURE of jejunum (Card specimen). (H. D. Rolleston) . . 122

SUBSTERNAL GOITRE arising in an accessory thyroid (Bernard Pitts) . 301

SUPERNUMERARY median nipple and areola in a male (W. Roger Williams) 224

Sutton (J. Bland), a harlequin calf 479
„ cervical teeth 477

SYMMETRICAL HEMIATROPHY of the gastrocnemii muscles (Card specimen). (J. H. Targett) 465
„ periostitis of femur, with an unusual formation of new bone (Anthony A. Bowlby) 243

Digitized by Google

PAGE

SYPHILITIC FIBROSIS of the lungs (E. C. Perry) . . . 53

SYRINGOMYELUS, case of (James Galloway) . . . 26

TARGETT (J. H.), Charcot's disease of both knee-joints (Card specimen) . 269
„ cystic dilatation of the vasa deferentia (Card specimen) . . 221
„ secondary melanotic sarcoma of the bladder . . . 214
„ symmetrical hemiatrophy of the gastrocnemii muscles (Card specimen) 465

TEETH, cervical (J. Bland Sutton) 477

TESTIS, cystic chondro-adenoma of (Card specimen). (H. Betham Robinson) 220

THYROID GLAND, tuberculosis of (E. C. Perry) . . . 298
„ — tuberculosis of the (Card specimen). (A. Voelcker) . . 298
„ substernal goitre arising in an accessory (Bernard Pitts) . . 301

TOES, webbed fingers and (Card specimen). (H. Betham Robinson) . 468

TOOTH (Howard H.), heterotopia of the grey matter of the spinal cord . 14

TRACHEA AND ŒSOPHAGUS in the neck involved by tumour (John Cahill) 91
„ fibroid polypus of (Leonard A. Bidwell) 40

TRICUSPID STENOSIS. partial obstruction of right auriculo-ventricular opening by partly calcified and organised fibrinous vegetations (Sheridan Délepine) 59

TUBERCLE, note on media for the cultivation of the bacillus of (H. R. Beevor, communicated by Professor Crookshank) . . . 344

TUBERCLE BACILLUS, the morphology, cultivation, and toxic products of the (Edgar M. Crookshank) 330

TUBERCULAR animals under treatment with tuberculin (P. S. Abraham and E. Crookshank) 343
„ necrosed pulmonary tissue and exudation (Card specimen). (Sheridan Délepine) 50
„ ulceration of the bladder (E. Hurry Fenwick) . . . 189

TUBERCULIN, note on tubercular animals under treatment with tuberculin (P. S. Abraham and E. Crookshank) 343
„ tubercular ulceration of the bladder treated by (E. Hurry Fenwick) . 189

TUBERCULOSIS, case of chronic general nodular, *i.e.* multiple tubercular tumours throughout the body, many in brain; no symptoms save indefinite one of tumour of the brain (Samuel West) . . 460
„ of finger (tendon-sheath, &c.). (E. C. Stabb) . . . 464
„ of the lung arising from tuberculosis of the bronchial glands (A. F. Voelcker) 46
„ of the pleura (E. C. Perry) 55
„ of the thyroid gland (Card specimen). (A. Voelcker) . . 298
„ of the thyroid gland (Card specimen). (E. C. Perry) . . 298

TUMOUR in the portal fissure and liver leading to complete occlusion of the vena cava from the kidneys to the heart, with a similar tumour in the heart (Samuel West) 155
„ of right kidney, weighing 4½ lbs.; hæmaturia; death (John R. Lunn) 186

TURNER (WILLIAM ALDREN) and CAMPBELL (C. M.), hererotopia of the grey matter of the spinal cord. 20

Digitized by Google

PAGE

TYPHOID FEVER, distension of, and commencing suppuration of the gall-bladder in association with typhoid fever (Card specimen). (W. Hale White) 181

TYSON (W. JOSEPH), large gall-stone in ductus communis choledochus (Card specimen) 182

ULCERATION of gall bladder (Sydney Jones) . . . 179

ULCERATIVE COLITIS (Card specimen). (H. Betham Robinson) . 115

„ — (Seymour J. Sharkey) 109

URINE, hæmatoporphyrin in the urine (S. Monckton Copeman) . . 364

UTERUS, blood-cast of the, in a case of anæmia (Card specimen). (Sheridan Delépine) 222

VASA DEFERENTIA, cystic dilatation of the (Card specimen). (J. H. Targett) 221

VEINS, case of chylous ascites and chylous hydrothorax, due to thrombosis and contraction of (Sidney Martin) 93

VERMIFORM APPENDIX in a case of general acute peritonitis (A. Voelcker) 128

„ — rupture of (Arthur Voelcker) . . . 127

VESICAL CALCULI (Card specimen). (Raymond Johnson) . . 217

VOCAL CORD, ulceration just below right (H. Montague Murray) . 35

VOELCKER (ARTHUR FRANCIS), caseous gland opening into the œsophagus 87

„ rupture of vermiform appendix 127

„ tuberculosis of the lung arising from tuberculosis of the bronchial glands 46

„ tuberculosis of the thyroid gland (Card specimen) . . . 298

„ vermiform appendix in a case of general acute peritonitis . . 128

VOLVULUS in a new-born infant; laparotomy (G. Newton Pitt) . 123

WEST (SAMUEL), case of chronic general nodular tuberculosis, *i. e.* multiple tubercular tumours throughout the body, many in brain; no symptoms save indefinite one of tumour of the brain 460

„ case of plastic bronchitis 43

„ liver containing two hydatids, the sacs communicating but not the cysts; paracentesis three times, 90 oz.; free incision; death from exhaustion 175

„ pylephlebitis suppurativa consequent on perityphlitis; no symptoms pointing to the liver; parotid swelling a fortnight before death subsiding without suppuration 138

„ tumour in the portal fissure and liver leading to complete occlusion of the vena cava from the kidneys to the heart, with a similar tumour in the heart 155

WETHERED (FRANK J.), psilosis or sprue 116

WHEATON (S. W.), external hydrocephalus 1

WHITE (W. HALE), distension and commencing suppuration of the gall-bladder in association with typhoid fever (Card specimen) . . 181

„ Hodgkin's disease, with lardaceous kidneys and an unusually large spleen (Card specimen) 468

WILLETT (EDGAR), intra-cystic carcinoma of pectoral region (Card specimen) 319

Digitized by Google

WILLETT (EDGAR) (*continued*)— PAGE
„ rupture of spleen 183
„ the soft parts and pelvis of a male adult who had extroversion of the bladder 215
„ two loose bodies removed from a knee-joint separately with an interval of four weeks 274
WILLIAMS (W. ROGER), case of supernumerary median nipple and areola in a male 224
WILSON (ALBERT), micro-organism of diphtheria with experimental results in animals 346
WYNTER (W. ESSEX), primary carcinoma of the right Fallopian tube with large cyst in connection with the new growth (Card specimen) . 222

PRINTED BY ADLARD AND SON, BARTHOLOMEW CLOSE.

Digitized by Google

Digitized by Google